

# The Results of Photodynamic Therapy in the Treatment of Central Serous Chorioretinopathy

## Kronik Santral Seröz Korioretinopati Tedavisinde Fotodinamik Tedavi Sonuçları

Zeynep ALKIN<sup>1</sup>, Ziya KAPRAN<sup>2</sup>, Tuğrul ALTAN<sup>1</sup>, Ece UZUN<sup>3</sup>, Nur ACAR<sup>1</sup>, Yaprak Banu ÜNVER<sup>1</sup>

Original Article

Klinik Çalışma

### ABSTRACT

**Purpose:** To evaluate the efficacy and results of photodynamic therapy (PDT) in the treatment of chronic central serous chorioretinopathy (CSC) which persists longer than six months.

**Material and Methods:** Fifteen eyes of 14 patients with subfoveal fluid which persisted longer than 6 months were included in the study. Visual acuities and contrast sensitivities of the patients were measured before and after the treatment. Infrared fundus photographs, fundus fluorescein and indocyanine green angiographies were performed. Central macular thickness and macular volume values were obtained with optical coherence tomography.

**Results:** The mean age of the patients was  $49 \pm 6.3$  years. Mean follow-up period was  $15.3 \pm 13.6$  months. Visual acuity (VA) increased more than 2 lines in 12 (80%) eyes after PDT. Visual acuity decreased 1 line in 1 (6.6%) eye; remained unchanged in 1 (6.6%) eye and increased 1 line in 1 (6.6%) eye. The mean contrast sensitivity did not change significantly after PDT. A statistically significant decrease in the mean central macular thickness and total macular volume was observed after the treatment compared to pretreatment ( $p=0.001$ ). Eleven (73.3%) eyes had complete resolution and 4 (26.7%) eyes had partial resolution of subretinal fluid in OCT. No complication was observed due to PDT.

**Conclusion:** Photodynamic therapy reduced subretinal fluid and improved visual acuity in patients with chronic CSC of longer than six months duration. Photodynamic therapy was considered as a safe and effective method in the treatment of chronic CSC.

**Key Words:** Central serous chorioretinopathy, photodynamic therapy, visual acuity.

### ÖZ

**Amaç:** Altı aydan uzun süren kronik santral seröz korioretinopatinin (SSKR) tedavisinde fotodinamik tedavinin (FDT) etkinliği ve sonuçlarını değerlendirmek.

**Gereç ve Yöntem:** Çalışmaya 6 aydan uzun süredir subfoveal sıvısı bulunan 14 olgunun 15 gözü dahil edildi. Tedavi öncesi ve sonrasında olguların görme keskinliği ve kontrast duyarlılık değerleri ölçüldü. İnfrared fundus fotoğrafisi, fundus florescein ve indosyanin yeşili anjiyografileri yapıldı. Optik koherens tomografi (OKT) ile santral makula kalınlığı ve makula hacmi elde edildi.

**Bulgular:** Olguların ortalama yaşı  $49 \pm 6.3$  idi. Ortalama takip süresi  $15.3 \pm 13.6$  aydı. Fotodinamik tedavi sonrası 12 (%80) olgunun görme keskinliğinde 2 sıra ve üzerinde artış görüldü. Bir (%6.6) olguda görme keskinliği değişmezken, 1 (%6.6) olguda 1 sıra azaldı. Ortalama kontrast duyarlılıkta FDT sonrasında anlamlı bir değişiklik olmadı. Ortalama santral makula kalınlığı ve total makula hacminde FDT öncesi ve sonrası değerler karşılaştırıldığında istatistiksel olarak anlamlı bir azalma gözlemlendi ( $p=0.001$ ). Optik koherens tomografide subretinal sıvının 11 (%73.3) gözde tam, 4 (%26.7) gözde kısmen gerilediği görüldü. Hiç bir gözde FDT'ye bağlı bir komplikasyon gelişmedi.

**Sonuç:** Fotodinamik tedavi 6 aydan uzun süren kronik SSKR'li olgularda subretinal sıvının gerilemesi ve görme keskinliğinin artırılmasında güvenli ve etkili bir yöntem olarak değerlendirilmiştir.

**Anahtar Kelimeler:** Santral seröz korioretinopati, fotodinamik tedavi, görme keskinliği.

Ret-Vit 2010;18:23-28

Geliş Tarihi : 23/12/2009

Kabul Tarihi : 08/03/2010

Received : December 23, 2009

Accepted : March 08, 2010

- 1- Beyoğlu Göz Eğitim ve Araştırma Hastanesi, İstanbul, Uzm. Dr.
- 2- Beyoğlu Göz Eğitim ve Araştırma Hastanesi, İstanbul, Doç. Dr.
- 3- Beyoğlu Göz Eğitim ve Araştırma Hastanesi, İstanbul, Asist. Dr.

- 1- M.D., Beyoğlu Eye Research and Education Hospital Kuledibi İstanbul/TURKEY  
ALKIN Z., zalkin@tmail.com  
ALTAN T., tugrulaltan@gmail.com  
ACAR N., nuracar@yahoo.com  
ÜNVER Y.B., yaprakbanu@yahoo.com
  - 2- M.D. Associate Professor, Beyoğlu Eye Research and Education Hospital Kuledibi İstanbul/TURKEY  
KAPRAN Z., zkaprana@gmail.com
  - 3- M.D. Asistant, Beyoğlu Eye Research and Education Hospital Kuledibi İstanbul/TURKEY  
UZUN E., eceuzun@hotmail.com
- Correspondence:** M.D., Zeynep ALKIN  
İbrahimçavuş Mahallesi Yayla Caddesi No:46 D.3 34104 Çapa İstanbul/TURKEY

## INTRODUCTION

Central serous chorioretinopathy (CSC) is characterized by the development of serous neurosensory retinal detachment at the posterior pole. The more common type, typical or classic CSC, presents with an acute localized detachment of the retina with mild to moderate loss of visual acuity. Fluorescein angiography shows one or a few focal leaks. The second presentation of CSC occurs with widespread alteration of the retina pigment epithelium (RPE) and chronic presence of subretinal fluid. This variant has been termed diffuse retinal pigment epitheliopathy, decompensated RPE, or chronic CSC.<sup>1</sup> Generally CSC is self-limited and resolves spontaneously in 4 to 6 months.<sup>2,3</sup> The condition is bilateral in up to 30% of cases, and recurrence occurs in about one third to one half of all patients.<sup>4</sup> A chronic variant of this condition may be associated with persistent subretinal exudation, extensive RPE atrophy, cystoid macular degeneration, choroidal neovascularization, and consequent severe visual loss.<sup>5-8</sup> Indocyanine green (ICG) angiography demonstrates primary choroidal involvement in CSC, including dilated and congested choriocapillaris, choroidal hyperpermeability and extravascular leakage.<sup>9,10</sup> Medical treatments have no proven influence on the course of chronic CSC. Laser photocoagulation therapy is performed on the site of RPE leakage which remains recommended only in selected cases with focal fluorescein dye leakage located 500  $\mu\text{m}$  away from the central fovea.<sup>11-15</sup> In chronic CSC affected areas are often diffuse; therefore, other treatment modalities are desired.

Yannuzzi et al first reported photodynamic therapy (PDT) as a new method of treatment for patients with chronic CSC.<sup>16</sup> PDT has been proven to be beneficial for predominantly classic subfoveal choroidal neovascular membrane (CNV) and completely occult CNV secondary to age related macular degeneration.<sup>17,18</sup> A series of histopathologic studies demonstrated closure of vascular channels in the choriocapillaris by the changes of endothelium.<sup>19</sup> Photodynamic therapy in CSC may lead to reduction of subretinal fluid by decreasing choroidal congestion.

The purpose of this study was to report the efficacy of PDT in chronic CSC.

## MATERIALS AND METHODS

In this study, we retrospectively analysed 15 eyes of 14 consecutive patients with chronic CSC treated with PDT in our clinic. Before the treatment all patients received detailed information about the procedure and all provided a written informed consent.

Inclusion criteria included presence of subretinal fluid and/or serous pigment epithelial detachment involving the fovea on optical coherence tomography (OCT) and fundus examination; angiographic leakage in fluo-

rescein angiography (FA) for at least 6 months or multifocal recurrent detachments with diffuse decompensation of the RPE. Patients who received previous PDT or thermal laser photocoagulation for the treatment of CSC or that had evidence of CNV, pathologic myopia, angioid streaks or other maculopathies were excluded. No systemic disease was observed except one patient with diabetes mellitus.

All patients received comprehensive ocular examination including best corrected visual acuity (BCVA), contrast sensitivity, dilated fundus examinations with a contact lens or a +90 diopter lens. This was followed by infrared fundus photography, FA-ICG angiography and OCT. Best corrected visual acuity was measured using ETDRS chart and converted to logarithmic minimum angle of resolution (log MAR) scale for statistical analysis; contrast sensitivity was measured with Pelli-Robson chart. Fluorescein and ICG angiography images were obtained using the Heidelberg retinal angiograph (Heidelberg Engineering GmbH, Heidelberg, Germany). Macular volume (MV) and central macular thickness (CMT) measurements were obtained using Stratus 3 OCT (Carl Zeiss Meditec Inc. Dublin, CA) in macular thickness map mode. The area of RPE changes was measured manually using a caliper on infrared photographs before and at least 3 months after the treatment.

Photodynamic therapy with verteporfin (Visudyne; Novartis Ophthalmic AG, Hettlinger, Switzerland) was performed according to the TAP (Treatment of Age Related Macular Degeneration with Photodynamic Therapy study). All patients received 6 mg/m<sup>2</sup> infusion of verteporfin over 10 minutes followed by delivery of diode laser at 689 nm (Zeiss, USA) 15 minutes after the initiation of infusion. A total light energy of 50 J/cm<sup>2</sup> and light dose rate of 600 mW/cm<sup>2</sup> was applied for 83 seconds. Protective glasses were given after the treatment, and patients were instructed to avoid direct sunlight or strong light for 3 days. Lesion size was measured as the area of choroidal hyperfluorescence on ICG angiograms. Laser spot diameter was equal to the lesion size.

Patients were scheduled to have follow-up visits on the first week, first month and every 3 months. BCVA, contrast sensitivity, fundus examination were performed in the same fashion as the baseline examination. Fundus photography, and FA-ICG angiography were applied only when judged to be of clinical value by the authors to evaluate the course of therapy. The main outcome measure was the rate of eyes that improved 2 or more lines at the final visit compared to baseline examination. Other outcomes included change in mean contrast sensitivity value, MV, CMT and RPE alteration area. Data were analyzed using SPSS software package version 14.11 (SPSS, Inc., Chicago, IL) and a P value of <0.05 was considered statistically significant. Paired sample t-test was used for continuous variables.

**Table 1:** Patients clinical characteristics.

Patient	Eye	Age	Sex	Baseline BCVA	Angiographic staining pattern	RPE alteration in fovea	PED	Posttreatment BCVA
1	Right	51	M	20/50	Multifocal Juxtafoveal	+	-	20/50
2	Right	57	F	20/63	Diffuse	+	-	20/32
3	Left	43	M	20/100	Diffuse	+	-	20/50
4	Right	48	F	20/50	Focal Juxtafoveal	+	-	20/33
5	Left	55	F	20/66	Diffuse	+	+	20/40
6	Left	61	M	20/32	Multifocal Juxtafoveal	-	-	20/20
7	Left	51	M	20/250	Diffuse	+	-	20/125
8	Right	47	M	20/32	Multifocal Juxtafoveal	+	-	20/20
9	Right	48	F	20/40	Diffuse	+	-	20/32
10	Left	47	M	20/63	Multifocal Extrafoveal	-	-	20/32
11	Right	42	M	20/50	Diffuse	-	-	20/25
12	Left	61	M	20/100	Diffuse	+	-	20/63
13	Right	47	M	20/250	Diffuse	+	-	20/320
14	Left	43	M	20/40	Focal Subfoveal	+	-	20/20
	Right	43		20/125	Focal Subfoveal	+	+	20/32

**Table 2:** Baseline and posttreatment findings comparison.

	Baseline	Posttreatment	p
BCVA(Log MAR)	0.54±0.28	0.31±0.32	0.001
CS(log unit)	23.8±5.05	24.5±4.90	0.54
MV(mm <sup>3</sup> )	7.84±1.37	6.57±0.57	0.001
CMT(μm)	309.67±108.8	151.8±302.4	0.001
PAA(mm <sup>2</sup> )	3.14±2.25	3.58±1.82	0.37

BCVA: Best Corrected Visual Acuity, CS: Contrast Sensitivity, MV: Macular Volume, CMT: Central Macular Thickness, PAA: Pigment Alteration Area.

## RESULTS

The mean age of the patients was 49.6±6.3 years (range, 42-61 years). Ten (71.4%) patients were male and 4 (28.6%) were female. Treatment was applied to 8 (53.3%) right eyes and 7 (46.7%) left eyes. The mean follow-up was 15.3±13.6 months (range, 3-42 months). Table 1 summarizes the clinical characteristics of the patients.

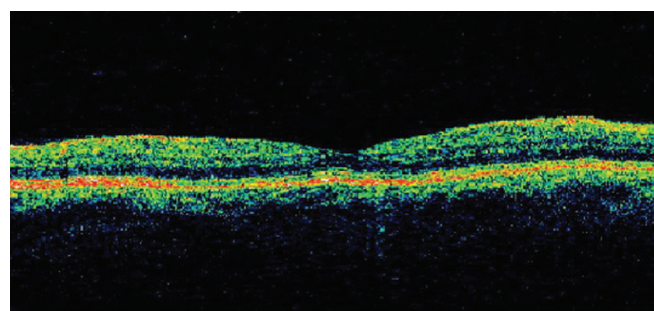
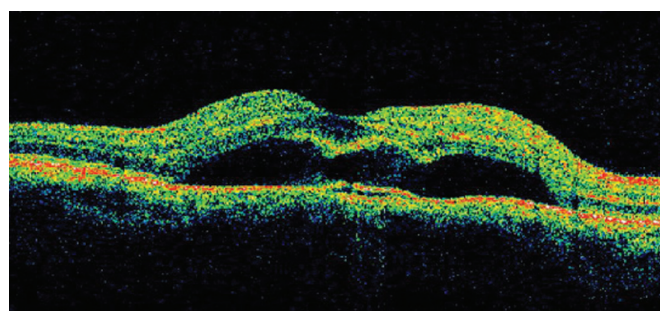
The mean LogMAR BCVA before PDT was 0.52 log unit. The BCVA ranged from 20/250 to 20/32 with a mean of 20/66. The visual acuity improved two or more lines in 12 (80%) eyes while one (6.6%) eye lost 1 line, one (6.6%) eye gained 1 line and another one eye had unchanged visual acuity, at the final visit. The median

Log MAR BCVA improved 0.3 log unit. The improvement compared to baseline was statistically significant ( $p=0.001$ ). At the final visit, the mean BCVA was 20/40, ranging from 20/320 to 20/20 (Graphic).

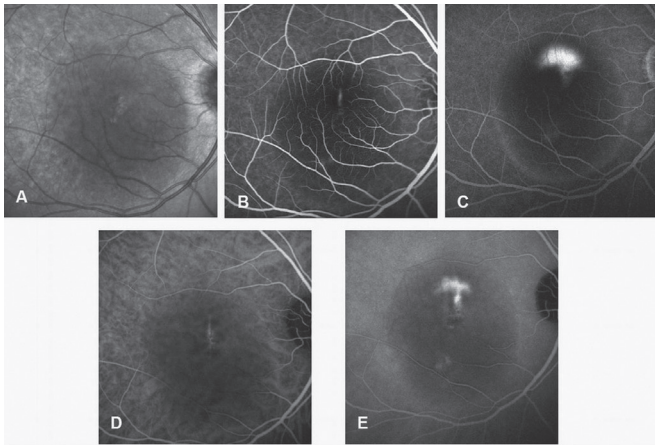
All cases had complete resolution of the ICG hyperpermeability at the site of the treatment after one session of PDT. The mean CMT at baseline was 309.6±108.8 μm (range, 137-533 μm). There was a significant reduction in macular thickness at third month with a mean CMT of 151±30.2 μm (range, 112-199 μm), ( $p=0.001$ ). While 11 (73.3%) eyes had a complete resolution of subretinal fluid, in 4 (26.7%) eyes an incomplete resolution was observed. The two eyes with PED demonstrated a complete resolution at 2 and 14 months after the therapy. Case 14 with a focal leakage that lasted for more than 6 months has been selected for case illustration (Figure 1-3).

Enlargement of the area of RPE alteration following treatment was observed, but the difference was not statistically significant ( $p=0.37$ ), (Table 2).

Retreatment with PDT was not considered in this study. No recurrence of the RPE leakage at the treated site was observed. Nor FA neither ICG angiography demonstrated choroidal hypofluorescence corresponding to the laser spot at first month after the treatment. None of the patients had any complication following the treatment.



**Figure 1:** A 43-year old man (case 14) who had reduced visual acuity due to CSC for the last 8 months with baseline visual acuity of 20/125 in his right eye. **A:** Baseline OCT showed the presence of subretinal fluid and pigment epithelial detachment in the same eye. **B:** OCT at one month after PDT showed complete resolution of the subretinal fluid and recovered pigment epithelial detachment.



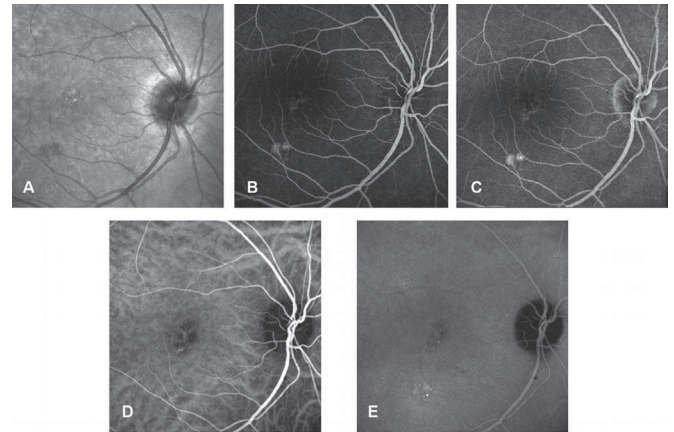
**Figure 2:** **A:** Infrared fundus photograph shows mottled pigmentation in the foveal region in the same patient before treatment. **B-C:** Fluorescein angiograms show focal leakage (1 minute) and increased focal leakage (14 minutes). **D-E:** Indocyanine green angiographies (4-24 minutes).

## DISCUSSION

In CSC, faster resorption of persistent subretinal fluid can be obtained by focal or grid laser photocoagulation applied to the focally or diffusely leaking area.<sup>15,20</sup> However, laser photocoagulation doesn't prevent recurrences and may cause scotomas.<sup>13,14,21,22</sup> In addition, development of choroidal neovascular membranes secondary to laser photocoagulation to treat CSC were reported.<sup>23,24</sup>

Although the physiopathology of CSC is not fully understood, it is believed that the pathology in the choroidal circulation is the cause of the clinical picture. It is alleged that the high perfusion pressure in choroidea causes serous RPE detachments and this results in RPE tears, leakage and RPE atrophy.<sup>10,25,26</sup> Visual prognosis is especially poor if the duration of the disease is longer than 6 months, and if it is accompanied by widespread RPE changes and RPE detachments.<sup>16</sup> In our study the eyes were not good candidates for laser photocoagulation because the leakage areas were focal subfoveal/juxtafoveal or diffuse.

There are several studies that reported successful results with PDT in chronic CSC.<sup>16,27-29</sup> Yannuzzi et al first reported ICG guided PDT in 20 eyes with chronic CSC. It was reported that complete resorption occurred in 60% of cases and partial resolution occurred in 40% of cases who were followed for 6 months.<sup>16</sup> Piccolino et al reported complete resolution of macular detachment following PDT in 75% of 16 eyes with chronic CSC in one month. More than one line of visual acuity gain was obtained in 69% of the eyes in 3 months.<sup>27</sup> Taban et al demonstrated improvement in visual acuity and a fast decrease in macular detachment following PDT in 4 eyes with chronic CSC.<sup>28</sup> In our study, visual acuity improved two or more lines in 12 (80%) eyes. In the study by Batıoğlu et al PDT resulted in complete resolution of serous macular



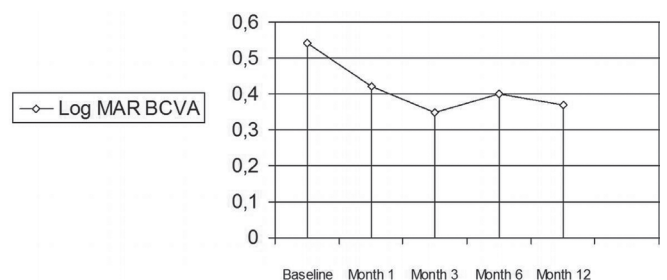
**Figure 3:** **A:** Infrared fundus photograph shows persistent retina pigment epithelial alterations 12 months after photodynamic therapy. **B-C:** Early phases of fluorescein (30 seconds) and indocyanine angiography (24 seconds) show no leakage in the treated area. **D-E:** Late phases of fluorescein (10 minutes) and indocyanine angiography (10 minutes) show hyperfluorescence inferior to fovea out of the previously treated area. The vision of the patient was 20/32 and further treatment was not applied.

detachment at 1 month after treatment in all eyes. In that series involving 6 eyes, 4 eyes had visual improvement by 2 or more lines and 2 eyes remained stable.<sup>29</sup>

The duration of the disease before treatment might have affected the duration of recovery period and final visual outcome due to longstanding and irreversible changes in photoreceptors and RPE.<sup>16</sup> In our study, the symptoms of the patient with decreased visual acuity were present for 8 years. There was a large area of RPE changes in the patient's eye. Based on these assumptions earlier treatment may be more appropriate for CSC.

Recurrences were not observed in any eye with chronic CSC during 10 months follow-up in a study conducted by Taban et al.<sup>28</sup> Yannuzzi et al reported recurrence of subretinal fluid in 2 eyes (10%) 4 months after PDT but additional therapy was not undertaken.<sup>16</sup> We did not observe any recurrent leakage in the area of treatment during 15 months follow-up.

Photodynamic therapy affects by complex cellular and vascular mechanisms. The primary effect of PDT seems to be the damage to the endothelium which is induced by direct interaction of singlet oxygen with the lipids



**Graphic:** Serial changes in mean LogMAR visual acuity of 15 eyes which had photodynamic therapy for chronic central serous chorioretinopathy.

of cytoplasmic membranes. Besides, verteporfin rapidly accumulates in the RPE cells that are similar to the endothelial cells for their high expression of LDL receptors.<sup>30</sup> Some authors reported various degrees of RPE damage after PDT. This may be secondary to choriocapillaris occlusion and/or accumulation of verteporfin in the RPE.<sup>31</sup>

Lai et al studied the change in retinal function after standard PDT with multifocal ERG. They observed transient impairments in retinal function after PDT such as reduction in response amplitudes and delayed peak latencies until first month.<sup>32</sup> Histopathological studies showed that recovery of the RPE took 3 to 4 weeks after the treatment.<sup>33</sup> For this reason many researchers advocated reducing the dose of verteporfin to avoid the undesired effects of PDT. These studies have shown complete resolution of serous retinal detachment in 83% to 85% of the eyes using half-dose verteporfin which is called safety enhanced PDT.<sup>34,35</sup> Lai et al.<sup>35</sup> reported no significant reduction in multifocal ERG response amplitudes with reduced dose of verteporfin in chronic CSC. A complete resolution rate was between 67% and 100% in studies using full dose verteporfin.<sup>27-29</sup> In a safety enhanced study a significant reduction in CMT occurred only in eyes without PED in chronic CSC. Moreover, a reduction in the central response amplitudes in eyes with PED was more than in eyes without PED after treatment. Therefore, PDT should be used more cautiously in eyes with pigment epithelial detachment.<sup>35</sup> In our study, there were only two eyes with PED and the number was considered insufficient to make an assessment.

In a series by Piccolino et al, 31% of the eyes developed secondary RPE changes at the site of PDT which were thought to be due to hypoxic damage caused by choriocapillaris occlusion.<sup>27</sup> Some authors reported that significant clinical or functional alteration in the RPE and neurosensory retina did not occur. Furthermore recanalization of the choriocapillaris begins as early as 2 or 3 weeks after treatment.<sup>16</sup> We did not observe choriocapillaris hypoperfusion in first month with ICG angiography. The area with RPE changes measured on infrared photographs did not enlarge significantly during follow-up as compared to pretreatment. Some authors explained that choroidal vascular structures were partially protected from the toxic effects of PDT by subretinal fluid or presence of CNVM.<sup>31</sup> In our study, visual acuity improvement was observed in 13 of 15 eyes (86.6%) with chronic CSC after PDT in a mean follow-up period of 15 months. We observed a complete resorption of subretinal fluid in 11 eyes (73.3%) and a partial resorption in 4 eyes (26.7%). No eyes were found to have recurrent subfoveal fluid accumulation. We did not observe any ocular and systemic complications.

The main limitations of our study were the short duration of follow-up and absence of a control group for comparison. However, the results of the early visual and angiographic outcomes are encouraging. Randomized controlled studies are essential to demonstrate the safety and efficacy of PDT in CSC in the long term.

## KAYNAKLAR/REFERENCES

1. Klais CM, Ober MD, Ciardella AP, et al.: Central serous chorioretinopathy. In Ryan SJ: Retina The CV Mosby Co. St. Louis. 2006;2:1135-1161.
2. Gass JDM.: Stereoscopic atlas of macular diseases: diagnosis and treatment. St. Louis: Mosby. 1997:52-70.
3. Hussain D, Gass JD.: Idiopathic central serous chorioretinopathy. Indian J Ophthalmol. 1998;46:131-137.
4. Gilbert CM, Owens SL, Smith PD, et al.: Long-term follow-up of central serous chorioretinopathy. Br J Ophthalmol. 1984; 68:815-820.
5. Yannuzzi LA, Shakin JL, Fisher YL, et al.: Peripheral detachments and retinal pigment epithelial atrophic tracts secondary to central serous pigment epitheliopathy. Ophthalmology. 1984;91:1554-1572.
6. Jalkh AE, Jabbour N, Avila MP, et al.: Retinal pigment epithelium decompensation. I. Clinical features and natural course. Ophthalmology. 1984;91:1544-1548.
7. Levine R, Brucker A, Robinson F.: Long-term follow-up of idiopathic central serous chorioretinopathy by fluorescein angiography. Ophthalmology. 1989;96:854-859.
8. Loo RH, Scott IU, Flynn HW Jr, et al.: Factors associated with reduced visual acuity during long-term follow-up patients with idiopathic central serous chorioretinopathy. Retina. 2002;22:19-24.
9. Piccolino FC, Borgia L, Zinicola E, et al.: Indocyanine green angiographic findings in central serous chorioretinopathy. Eye. 1995; 9:324-332.
10. Prunte C, Flammer J.: Choroidal capillary and venous congestion in central serous chorioretinopathy. Am J Ophthalmol. 1996; 121:26-34.
11. Pikkil J, Beiran I, Ophir A, et al.: Acetazolamide for central serous retinopathy. Ophthalmology. 2002;109:1723-1725.
12. Browning DJ.: Nadolol in the treatment of central serous retinopathy. Am J Ophthalmol. 1993;116:770-771.
13. Khosla PK, Rana SS, Tewari HK, et al.: Evaluation of visual function following argon laser photocoagulation in central serous retinopathy. Ophthalmic Surg Lasers. 1997;28:693-697.
14. Burumcek E, Mudun A, Karacorlu S, et al.: Laser photocoagulation for persistent central serous retinopathy: results of long-term follow-up. Ophthalmology. 1997;104:616-622.
15. Yannuzzi LA, Slakter JS, Kaufman SR, et al.: Laser treatment of diffuse retinal pigment epitheliopathy. Eur J Ophthalmol. 1992;2:103-114.
16. Yannuzzi LA, Slakter JS, Gross NE, et al.: Indocyanine green angiography-guided photodynamic therapy for treatment of chronic central serous chorioretinopathy. A pilot Study. Retina. 2003;23:288-298.
17. Treatment of Age-Related Macular Degeneration With Photodynamic Therapy (TAP) Study Group: Photodynamic therapy of subfoveal choroidal neovascularization in age related macular degeneration with verteporfin: One year results of 2 randomized clinical trials-TAP report 1. Arch Ophthalmol. 1999;117:1329-1345.
18. Verteporfin in Photodynamic Therapy Study Group: Photodynamic therapy of subfoveal choroidal neovascularization in age-related macular degeneration: two-year results of a randomized clinical trial including lesions with occult with no classic choroidal neovascularization-verteporfin in photodynamic therapy report 2. Am J Ophthalmol. 2001;131:541-560.
19. Moshfeghi DM, Kaiser PK, Grossniklaus HE, et al.: Clinicopathologic study after submacular removal of choroidal neovascular membranes treated with verteporfin ocular photodynamic therapy. Am J Ophthalmol. 2003;135:343-350.
20. Yannuzzi LA.: Central serous chorioretinopathy. In: Yannuzzi LA, ed. Laser photocoagulation of the macula. Philadelphia: Lippincott. 1989:1-12.
21. Ficker L, Vafidis G, While A, et al.: Long-term follow-up of a prospective trial of argon laser photocoagulation in the treatment of central serous retinopathy. Br J Ophthalmol. 1988;72:829-834.
22. Parodi MB, Pozzo SDA, Ravalico G.: Photodynamic therapy in chronic central serous chorioretinopathy. Retina. 2003;23:235-237.

23. Simon P, Glacet-Bernard A, Binaghi M, et al.: Choroidal neovascularization as a complication following laser treatment of central serous chorioretinopathy. *J Fr Ophthalmol.* 2001;24:64-68.
24. Ha TW, Ham DI, Kang SW.: Management of choroidal neovascularization following laser photocoagulation for central serous chorioretinopathy. *Korean J Ophthalmol.* 2002;16:88-92.
25. Giovannini A, Scassellati-Sforzolini B, D'Altobrando E, et al.: Choroidal findings in the course of idiopathic serous pigment epithelial detachment detected by indocyanine green videoangiography. *Retina.* 1997;17:286-293.
26. Spaide RF, Hall L, Haas A, et al.: Indocyanine green videoangiography of older patients with central serous chorioretinopathy. *Retina.* 1996;16:203-213.
27. Piccolino FC, Eandi CM, Ventre L, et al.: Photodynamic therapy for chronic central serous chorioretinopathy. *Retina.* 2003;23:752-763.
28. Taban M, Boyer DS, Thomas EL, et al.: Chronic central serous chorioretinopathy: Photodynamic Therapy. *Am J Ophthalmol.* 2004;137:1073-1080.
29. Batioğlu F, Özmert E, Demirel S, et al.: Kronik Santral Seröz Korioretinopatide Fotodinamik Tedavi Sonrası OCT ve Fundus Otofloresans Bulguları. *Ret-Vit.* 2007;15:99-102.
30. Schmidt-Erfurth U, Hasan T.: Mechanism of action of photodynamic therapy with verteporfin for the treatment of age-related macular degeneration. *Surv Ophthalmol.* 2000;45:195-214.
31. Tzekov R, Lin T, Zhang KM, et al.: Ocular changes after photodynamic therapy. *Invest Ophthalmol Vis Sci.* 2006;47:377-385.
32. Lai TYY, Chan WM, Lam DSC.: Transient reduction in retinal function revealed by multifocal electroretinogram after photodynamic therapy. *Am J Ophthalmol.* 2004;137:826-833.
33. Husain D, Kramer M, Kenny AG, et al.: Effects of photodynamic therapy using verteporfin on experimental choroidal neovascularization and normal retina and choroid up to 7 weeks after treatment. *Invest Ophthalmol Vis Sci.* 1999;40:2322-2331.
34. Chan WM, Lai TYY, Lai RYK, et al.: Safety enhanced photodynamic therapy for chronic central serous chorioretinopathy. *Retina.* 2008;28:85-93.
35. Lai TYY, Chan WM, Li H.: Safety enhanced photodynamic therapy with half dose verteporfin for chronic central serous chorioretinopathy: a short term pilot study. *Br J Ophthalmol.* 2006;90:869-874.