

# Comparison of Efficacy of Tamponade Agents in Decreasing of Postoperative Complications in Vitrectomy Performed for Isolated Vitreous Hemorrhage in Patients with Diabetic Retinopathy

Selma URFALIOGLU<sup>1</sup>, Mete GULER<sup>2</sup>, Elif DAMAR GUNGOR<sup>3</sup>, Betül DAGHAN<sup>4</sup>

## ABSTRACT

**Purpose:** To compare the efficacy of tamponade agents in decreasing postoperative complications in vitrectomy performed for isolated vitreous hemorrhage in patients with diabetic retinopathy.

**Materials and Methods:** We retrospectively reviewed files of patients who underwent pars plana vitrectomy for isolated vitreous hemorrhage. Only patients without tractional detachment who had non-clearing vitreous hemorrhage were included in the study. All patients underwent standard 3-port 23 gauge pars plana vitrectomy. The patients who underwent pars plana vitrectomy were divided into 4 groups according to the intraocular tamponade used: fluid (group 1), air (group 2), perfluoropropane gas (group 3) and silicone oil (group 4). We recorded complications (such as re-hemorrhage, fibrovascular proliferation, neovascular glaucoma, retinal detachment) observed with intraocular tamponade in place and within the first 1 month after tamponade effectiveness disappeared.

**Results:** There were 17 patients in group 1, 13 in group 2, 14 in group 3, and 13 in group 4. The age ( $p = 0.251$ ), gender ( $p = 0.262$ ) and diabetes duration ( $p = 0.112$ ) of the patients were similar in all groups. The number of patients experienced complications was 3 in group 1 (17.6%), 3 in group 2 (23.1%), 3 in group 3 (21.4%) and 2 in group 4 (15.4%). Complication rates were comparable in all groups ( $p = 0.957$ ).

**Conclusion:** No tamponade is required to reduce postoperative complications when no tear is detected with successful hemostasis during the surgery in vitrectomy performed for isolated vitreous hemorrhage in patients with diabetic retinopathy.

**Key words:** Air, diabetic retinopathy, pars plana vitrectomy, perfluoropropane, silicone oil.

## INTRODUCTION

Diabetic retinopathy (DR) is a leading cause of vision loss worldwide. Proliferative diabetic retinopathy is characterized by neovascularization in retina and optic disc due to hypoxia, micro-angiopathy and capillary occlusion. Vitreous hemorrhage, a delayed complication of proliferative DR, can result in loss of depth vision due to tractional retinal detachment and serious fibrovascular proliferation.<sup>1</sup>

In the treatment of non-proliferative DR, panretinal photocoagulation and anti-vascular endothelial growth factor (anti-VEGF) agents are being used successfully.

However, vitreous surgery may be needed for treatment of PDR complications such as non-clearing vitreous hemorrhage or tractional retinal detachment.<sup>2</sup> Several intraocular tamponade agents have been used to improve long-term success and to achieve retinal stabilization in vitrectomy surgeries employed for treatment of PDR complications, including intraocular air, sulfur hexafluoride (SF<sub>6</sub>), perfluoropropane (C<sub>3</sub>F<sub>8</sub>) and silicone oil.<sup>3</sup> Although the tamponade agents are widely used, there is limited number of studies comparing their efficacy in vitrectomy performed for PDR.<sup>3,4</sup> In this study, it was aimed to compare efficacy of various tamponade agents in decreasing postoperative complications in vitrectomy in PDR patients with isolated vitreous hemorrhage.

1- MD, Asistant Prof., Sutcu Imam University Faculty of Medicine, Department of Ophthalmology, Kahramanmaras, Turkey

2- MD, Associate Prof., Sutcu Imam University Faculty of Medicine, Department of Ophthalmology, Kahramanmaras, Turkey

3- Kahramanmaras Necip Fazil City Hospital, Department of Ophthalmology, Kahramanmaras, Turkey

4- Asistant Dr., Faculty of Medicine, Department of Ophthalmology, Kahramanmaras, Turkey

Received: 14.03.2019

Accepted: 20.06.2020

*Ret-Vit* 2020; 29: 297-300

DOI: 10.37845/ret.vit.2020.29.54

**Correspondence Address:**

Mete GULER

Sutcu Imam University Faculty of Medicine, Department of Ophthalmology,

Kahramanmaras, Turkey

**Phone:** +90 533 771 4080

**E-mail:** meteglr@yahoo.com

## MATERIAL AND METHOD

The study was approved by Ethics Committee on Clinical Research (Approval#2020/4/6). The study was conducted in accordance to tenets of Helsinki Declaration. We retrospectively reviewed files of patients who underwent pars plana vitrectomy (PPV) for complications of diabetic retinopathy between September, 2017 and January, 2020. Only patients without tractional detachment who had non-clearing vitreous hemorrhage were included in the study. The non-clearing hemorrhage was defined as hemorrhage which lasted more than one month and hampered daily activities of an individual (Picture 1). In all patients, standard intravitreal anti-VGEF agent was given 3-7 days before surgery. In all patients, surgery was performed by a single surgeon (M.G). All patients underwent standard 3-port 23 gauge pars plana vitrectomy. Missing laser therapy was completed as panretinal photocoagulation during surgery. In patients given tamponade, whole intraocular space was filled with tamponade agent. In patients with sclerotomy leakage, sclerotomy was closed using 8.0 Vicryl sutures to avoid postoperative hypotonia.

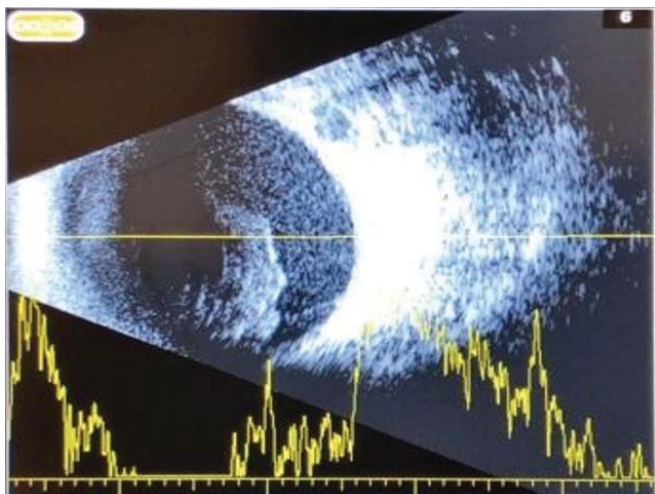
The patients underwent PPV were divided into 4 groups according to tamponade agent:

Group 1: Patients given no tamponade agent, managed with fluid alone,

Group 2: Patients given air as tamponade agent after surgery,

Group 3: Patients given perfluoropropane gas at non-expanding concentration (14%) as tamponade agent after surgery,

Group 4: Patients given silicone oil (1000 centistokes) as tamponade agent after surgery,



**Picture 1:** Sonography image of patients with non-clearing vitreous hemorrhage.

In all patients, age, gender, diabetes duration, and visual acuity before and in final control visit after surgery were recorded. In addition, we recorded and compared complications (such as re-hemorrhage, fibrovascular proliferation, neovascular glaucoma, retinal detachment) observed with intraocular tamponade in place and within the first 1 month after tamponade.<sup>5</sup> The abolishment of tamponade agent activity was defined as complete absorption for gas tamponades and removal from eye for silicone oil.

All statistical analyses were performed using Statistics Program for Social Sciences (SPSS) version 20.0. Numerical values were compared using Kruskal-Wallis variance analysis while categorical variables were compared using Chi-square test among groups.

## FINDINGS

Overall, 57 patients underwent surgery for non-clearing vitreous hemorrhage due to diabetic retinopathy during study period. Table 1 presents demographic and clinical characteristics of patients. There were 17 patients in group 1, 13 in group 2, 14 in group 3, and 13 in group 4. The age ( $p = 0.251$ ), gender ( $p = 0.262$ ) and diabetes duration ( $p = 0.112$ ) of the patients were similar in all groups. The number of patients experienced complications was 3 in group 1 (17.6%), 3 in group 2 (23.1%), 3 in group 3 (21.4%) and 2 in group 4 (15.4%). Complication rates were comparable in all groups ( $p = 0.957$ ). Of the patients with complication, recurrent hemorrhage was observed in 6 patients including one patient in fluid group, 2 patients in air tamponade group and 3 patients in perfluoropropane gas tamponade group. Significant improvement in visual acuity was achieved in all groups after surgery (Wilcoxon test;  $p=0.001$  for group 1,  $p=0.001$  for group 2,  $p=0.034$  for group 3 and  $p=0.007$  for group 4). Mean postoperative HbA1c was  $9.54 \pm 2.08\%$  (6.0-13.0%).

## DISCUSSION

Today, there is a rapid increase in the number of diabetic individuals and it is estimated that there will be a half billion individual with diabetes mellitus in 2030.<sup>6</sup> Thus, vision loss due to diabetic retinopathy will remain to be an important health issue. The number of vitrectomy surgeries for complications of diabetic retinopathy is increasing due to advances in vitreoretinal surgery equipments and increasing number of surgeons capable to perform vitrectomy.<sup>7</sup> Several complications including cataract (39-57%), recurrent vitreous hemorrhage (11-20%), neovascular glaucoma (3.2-7.1%), retinal tear and detachment (4.3-27.7%) can be seen following successful vitrectomy.<sup>8</sup> Clinicians can use various tamponade agents either during or after surgery in order to avoid these

**Table 1.** Demographic and clinical data according to patient groups.

	GROUP 1 (FLUID)	GROUP 2 (AIR)	GROUP 3 (PERFLUOROPROPAN)	GROUP 4 (SILICONE)	P value
AGE (Year)	59±7 (49-75)	60±11 (42-75)	59±9 (48-72)	53±8 (35-66)	0.251
GENDER	5 E/12 K	7 E/6 K	5 E/ 9 K	8 E/ 5 K	0.262
DIABETES DURATION (Year)	17±7 (2-26)	11±5 (1-22)	10±5 (1-21)	11±4 (6-20)	0.121
PREOPERATIVE VISUAL ACUITY (LogMAR)	1.85±0.6 (2.20-0.30)	1.78±0.41 (2.20-1.00)	1.65±0.60 (2.20-0.5)	1.71±0.48 (2.20-1.0)	0.575
POSTOPERATIVE VISUAL ACUITY (LogMAR)	0.76±0.75 (2.20-0.10)	0.65±0.40 (1.30-0.10)	1.11±0.73 (2.20-0.1)	1.04±0.60 (2.20-0.15)	0.128
Complication	Recurrent Hemorrhage (n=1) Neovascular glaucoma (n=2)	Recurrent Hemorrhage (n=2) Retinal detachment (n=1)	Recurrent Hemorrhage (n=3)	Neovascular glaucoma (n=1) Retina detachment (n=1)	0.975

troublesome complications for clinician and patient. The most commonly used tamponade agents are air, sulfur hexafluoride, perfluoropropane and silicone oil. Yang et al. reported that 10% C3F8 use is beneficial to prevent early postoperative vitreous hemorrhage in vitrectomy.<sup>5</sup> In their series, Kayik et al. reported that C3F8 was inadequate to prevent vitreous hemorrhage after vitrectomy.<sup>9</sup> In a prospective, randomized study, Koutsandrea et al. investigated hemostatic effect of SF6 in preventing postoperative vitreous hemorrhage in vitrectomy surgeries for diabetic retinopathy. Authors found no significant difference in prevention of vitreous hemorrhage between sulfur hexafluoride gas and balanced salt solution (BSS). In addition, they emphasized that SF6 gas is not an appropriate tamponade agent as it may trigger cataract in phakic eyes.<sup>10</sup> There are many studies using silicone oil as intraocular tamponade after vitrectomy surgery in patients with diabetic retinopathy. However, silicone oil was used in advanced PDR patients in these studies. Ramezani et al. reported that silicone oil use as tamponade agent following vitrectomy was associated with successful anatomic outcomes but functional outcomes were not satisfactory in patients with advanced diabetic retinopathy.<sup>11</sup> Authors also found that outcomes of heavy silicone oil were worse in patients with macular detachment at baseline and intraoperative iatrogenic tear. Shen et al. reported efficacy of long-term use of silicone oil tamponade following vitrectomy for treatment of complex retinal detachment in PDR.<sup>12</sup> Authors proposed that long-term silicone oil tamponade will achieve anatomic and functional stability. The complications reported were peri-silicone perforation, neovascular glaucoma, elevated intraocular pressure due to

pupillary blockade and silicone oil translocation to anterior chamber.

There is a few number of studies comparing efficacy of different tamponade agents in decreasing postoperative complications after vitrectomy for PDR. Flaxel et al. reported that there was no significant difference between perfluoropropane gas and silicone oil regarding postoperative retinal detachment in vitrectomy surgeries performed in DR patients.<sup>13</sup> Ando et al compared outcomes of vitrectomy surgeries for DR in patient groups given SF6, silicone oil as tamponade or no tamponade agent. Authors reported improved visual acuity in majority of patients received SF6 or no tamponade but limited visual acuity gain in patients received silicone oil, attributing these results to fact that silicone oil was used in eyes with more severe involvement. As similar to our study, Balakrishnan et al. compared eyes given no tamponade or air, gas and silicone oil as tamponade agent in vitrectomy performed for PDR and vitreous hemorrhage regarding postoperative complications. In 6-months follow-up after surgery, authors reported that tamponade use showed no superiority to eyes with no tamponade use regarding prevention of recurrent vitreous hemorrhage.<sup>3</sup> We also found that tamponade use had no effect on prevention of postoperative complications in cases with isolated vitreous hemorrhage in PDR. Balakrishnan et al. reported rate of recurrent vitreous hemorrhage as 11.1% in tamponade-free, 11.1% in air, 6.7% in gas and 9.5% in silicone oil groups.<sup>3</sup> In our study, postoperative complication rate was higher in fluid (17.6%), air (23.1%), gas (21.4%) and silicone oil (15.4%) groups when compared to those

reported by Balakrishnan et al. This may be due to poorer postoperative glucose regulation in our patients [Mean postoperative HbA1c was  $9.54 \pm 2.08\%$  (6.0-13.0%)].

Our study has several limitations. The number of patients in study groups was relatively smaller. This is due to inclusion of patients with vitreous hemorrhage alone and exclusion of patients requiring intervention for proliferative membranes. Thus, our results could not be true for patients with advanced DM. We included patients with 6-months follow-up; thus, our results could not be generalized for longer follow-up. However, we believe that our study will contribute to literature in this field in which there is limited number of studies in the literature. There is a need for multicenter studies to elucidate effectiveness of tamponade agents in preventing postoperative complications in vitrectomy surgeries performed for PDR complications.

## CONCLUSION

In conclusion, tamponade agent use is unnecessary to decrease postoperative complications in vitrectomy surgeries performed for isolated vitreous hemorrhage in DR patients when no tear is detected with successful hemostasis during the surgery.

## REFERENCES

1. Larrañaga-Fragoso P, Laviers H, et al. Surgical outcomes of vitrectomy surgery for proliferative diabetic retinopathy in patients with abnormal renal function. *Graefes Arch Clin Exp Ophthalmol* 2020;258:63-70.
2. Yau GL, Silva PS, Arrigg PG, et al. Postoperative complications of pars plana vitrectomy for diabetic retinal disease. *Semin Ophthalmol* 2018;33:126-33.
3. Balakrishnan D, Jain B, Nayaka A, et al. Role of tamponade in vitrectomy for proliferative diabetic retinopathy with vitreous hemorrhage. *Semin Ophthalmol* 2017;32:488-91.
4. Ando F, Nagasaka T, Sasano K, et al. Factors influencing surgical results in proliferative diabetic retinopathy. *Ger J Ophthalmol* 1993;2:155-60.
5. Yang CM, Yeh PT, Yang CH. Intravitreal long-acting gas in the prevention of early postoperative vitreous hemorrhage in diabetic vitrectomy. *Ophthalmology* 2007;11:710-5.
6. Wild S, Roglic G, Green A, et al. Global prevalence of diabetes: estimates for the year 2000 and projections for 2030. *Diabetes Care* 2004;27:1047-53.
7. Kim JY, Rim TH, Kim SS. Trends of pars plana vitrectomy rates in south korea: a nationwide cohort study. *Korean J Ophthalmol* 2017;31:446-51.
8. Yau GL, Silva PS, Arrigg PG, et al. Postoperative complications of pars plana vitrectomy for diabetic retinal disease. *Semin Ophthalmol* 2018;33:126-33.
9. Kayık T, Uçgun Nİ, Önen M, et al. Review of our pars plana vitrectomy results for proliferative diabetic retinopathy. *Journal of Retina-Vitreous* 2009;17:9-13.
10. Koutsandrea CN, Apostolopoulos MN, Chatzoulis DZ, et al. Hemostatic effects of SF6 after diabetic vitrectomy for vitreous hemorrhage. *Acta Ophthalmol Scand* 2001;79:34-8.
11. Ramezani A, Ahmadi H, Rozegar A, et al. Predictors and outcomes of vitrectomy and silicone oil injection in advanced diabetic retinopathy. *Korean J Ophthalmol* 2017;31:217-29.
12. Shen YD, Yang CM. YD. Extended silicone oil tamponade in primary vitrectomy for complex retinal detachment in proliferative diabetic retinopathy: a long-term follow-up study. *Eur J Ophthalmol* 2007;17:954-60.
13. Flaxel CJ, Dustin L, Kim J, et al. Outcome of diabetic vitrectomy in Latino population. *Retina* 2007;27(9):1274-1278.
14. McCuen BW 2nd, Azen SP, Stern W, et al. Vitrectomy with silicone oil or perfluoropropane gas in eyes with severe proliferative vitreoretinopathy. *Silicone Study Report 3. Retina* 1993;13:279-84.
15. Adelman RA, Parnes AJ, Sipperley JO, et al; European Vitreo-Retinal Society (EVRS) Retinal Detachment Study Group. Strategy for the management of complex retinal detachments: the European vitreo-retinal society retinal detachment study report 2. *Ophthalmology* 2013;120:1809-13.