

# Tuberculosis Anterior Uveitis and Choroidal Tuberculosis Granuloma

Suzan DOGRUYA<sup>1</sup>, Ozcan Rasim KAYIKCIOGLU<sup>2</sup>

## ABSTRACT

In this study, we present a patient with pulmonary tuberculosis, who was diagnosed with uveitis and choroidal granuloma occurring as a new attack in the other eye. Visual acuity of a 26 year-old woman complaining about visual loss in the left eye and fuzziness in both eyes was 0.05 in the right eye and 0.5 in the left eye. Anterior segment examination was normal in the right eye and anterior chamber had 2+cells in the left eye. In the fundus examination of the right eye, diffuse chorioretinal atrophy and atrophy in macula were observed. In the examination of the left eye, macular nasal elevation and retinal pigment irregularity was detected. OCT showed atrophy of the fovea and subretinal fibrosis in the right eye, foveal nasal elevation and fibrosis in the left eye. In FFA, scar areas were observed in the right eye retina and there was, an active focus the granuloma and three scar areas in upper temporal of the left eye. The patient was followed-up under anti-Tbc treatment with the advice of pneumotologist and also topical cyclopegia and steroid treatment. The patient's visual acuity peaked in the left eye after a 12-month treatment. In the follow-ups, foci were observed in the posterior areas of the left eye. During the follow-up period, fresh foci were seen in adjacent areas of the posterior in the left eye in the second year. The patient is still under follow-up with anti-TBc treatment. Tuberculosis uveitis and choroidal granulomas are serious diseases which require long and careful follow-up.

**Keywords:** Tuberculosis uveitisi, Choroidal granuloma, Long-term follow-up.

## INTRODUCTION

Tuberculosis is an infection caused by acid resistant bacilli, *Mycobacterium tuberculosis*, which primarily involves lung tissue. The bacteria can spread to extra-pulmonary tissues such as eyes, gastrointestinal system, genitourinary system, cardiovascular system, central nervous system and skin via lymphatic and hematogenous route.<sup>1</sup> Pulmonary and extra-pulmonary infections with eye involvement comprise 10% of all cases.<sup>2-4</sup> The choroidal granuloma caused by tuberculosis occurs via hematogenous spread. However, choroiditis is presumably due to hyper-sensitivity reaction against bacterial proteins.<sup>2</sup> The true incidence of tuberculosis-related uveitis varies from 1-4% to 10-26% across world.<sup>5-7</sup>

Clinically, intraocular tuberculosis is seen as anterior uveitis, intermediate uveitis, posterior uveitis, choroidal tuberculoma, retinitis, retinal vasculitis, neuroretinitis, optic neuropathy, endophthalmitis and panophthalmitis.

Ocular tuberculosis is generally unilateral and asymmetrical. Tuberculosis can spread from ocular surface to central nervous system via optic nerve, resulting in a wide spectrum of ocular findings.<sup>8</sup> Here, we present a young patient who previously experienced loss of vision in one eye and had impaired vision in the other eye due to tuberculosis uveitis.

## CASE REPORT

A 26-years old woman with diagnosis of pulmonary tuberculosis diagnosis presented to our clinic with blurred vision and loss of vision in left eye. In ophthalmological examination, visual acuity was 0.05 in right eye and 0.5 in left eye. In biomicroscopy, anterior segment was normal in right eye while +2 cell was observed in left eye. In fundus examination, there was diffuse chorioretinal atrophy and macular atrophy in the right eye and elevation in nasal segment of macula, tuberculosis granuloma and irregularity in retinal pigment epithelium in left eye

1- MD, Ophthalmology Department of Uşak Training and Research Hospital, Uşak, Turkey

2- Prof. Dr., Ophthalmology Department of Celal Bayar University, Medicine School, Manisa, Turkey

**Received:** 06.09.2019

**Accepted:** 18.10.2019

*Ret-Vit* 2021; 30: 81-85

DOI:10.37845/ret.vit.2021.30.14

**Correspondence Address:**

Suzan DOGRUYA

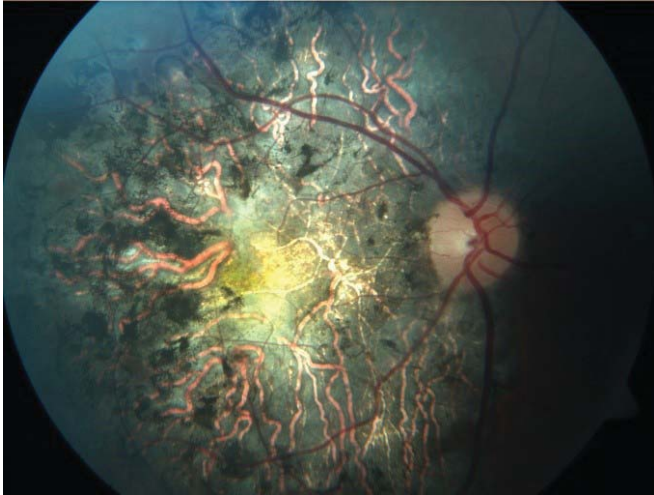
Ophthalmology Department of Uşak Training and Research Hospital, Uşak, Turkey

**Phone:** +90 276 224 0000

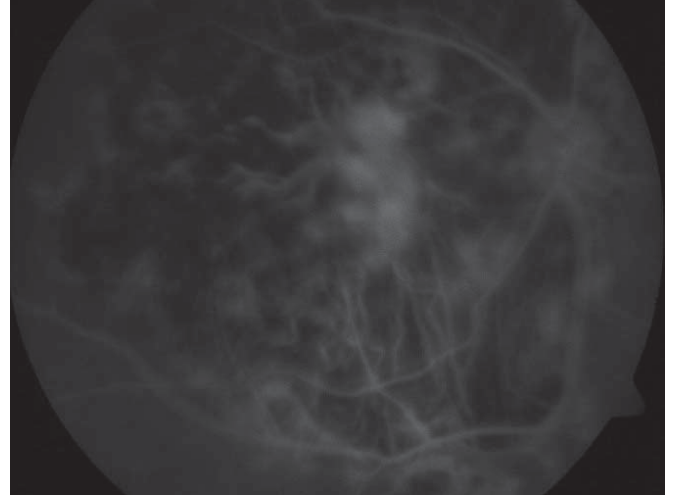
**E-mail:** sdogruya@hotmail.com

(Figure 1, 2). On optical coherence tomography (OCT), there was marked foveal atrophy, subretinal fibrosis in left eye and elevation with marked contours in the nasal fovea and fibrosis. Scarring areas in retina in right eye and active

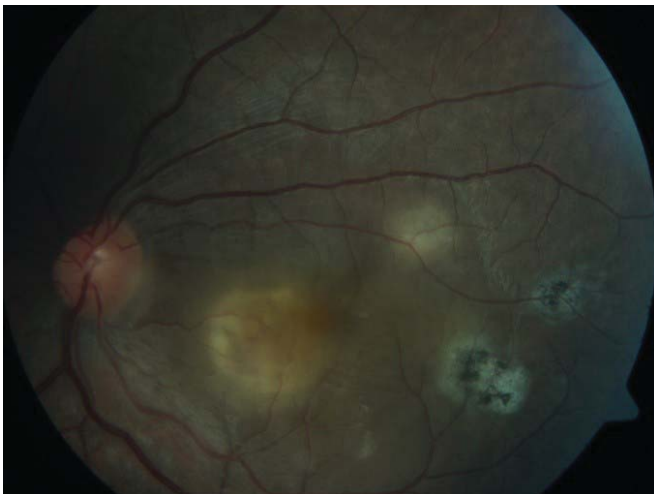foci of tuberculosis granuloma and 3 areas of scarring in the left eye were observed on FFA (Figure 3, 4, 5 and 6). After consultation by thoracic diseases department, systemic anti-tuberculosis therapy (isoniazid, rifampicin,



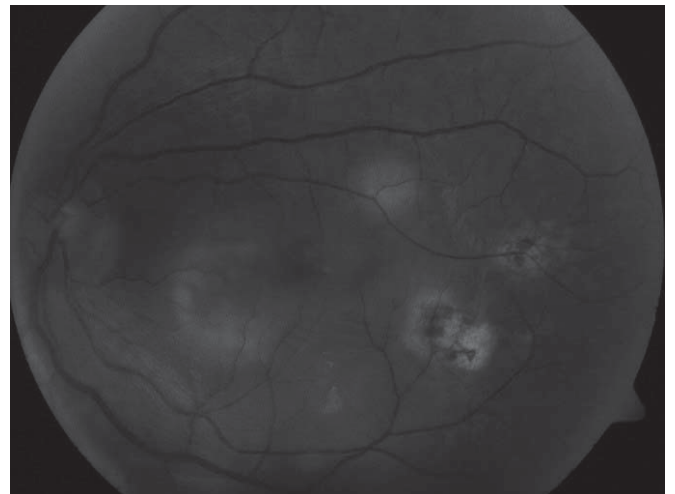
**Figure 1:** Diffuse chorioretinal atrophy and macular scar are seen in fundus image of right eye.



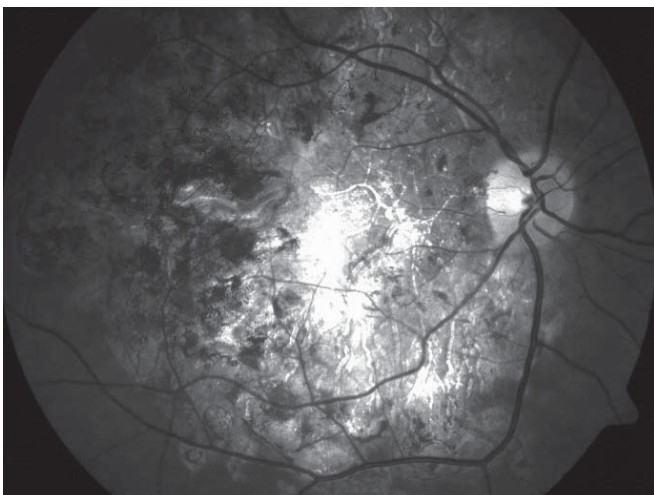
**Figure 4:** Scarring areas are seen in FFA of right eye.



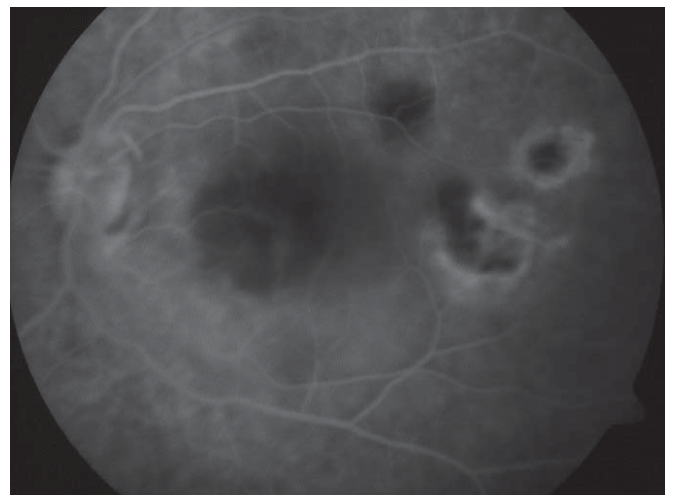
**Figure 2:** Elevation in nasal macula and RPE irregularity are seen in fundus image of left eye.



**Figure 5:** Active foci tuberculosis granuloma is seen in upper temporal region of retina in FFA of left eye.



**Figure 3:** Scarring areas are seen in FFA of right eye.



**Figure 6:** Active foci tuberculosis granuloma is seen in upper temporal region of retina in FFA of left eye.

ethambutol and pyrazinamide over 2 months; followed by isoniazid) was prescribed. Topical steroid and cycloplegic therapy was given for anterior uveitis. After 12-months of systemic anti-tuberculosis therapy, the visual acuity was improved to full vision in the left eye; there was no finding of uveitis on biomicroscopy and multiple macular scars were observed in the left eye on fundus examination. On OCT, subretinal fibrosis was observed in left macula (Figure 7). During 2-years follow-up, no attack was experienced. At the end of 2 years, the patient presented again with impaired vision in the left eye. In the second presentation visual acuity was 0.05 in right eye and 0.05 in the left eye. In the biomicroscopic examination, both right

and left eyes were normal with no findings of uveitis. On fundus examination, there was macular scar in the right eye and macular hyper-pigmented and hypo-pigmented areas compatible with active foci in the left eye (Figure 8, 9 and 10). The patient was re-consulted with thoracic diseases department and anti-tuberculosis therapy was re-initiated. In final control visit, visual acuity was 0.05 in the right eye and 0.4 in the left eye. In biomicroscopy, anterior segment was normal while macular hyper-pigmented lesion was observed in macula with uneventful vitreous. On OCT, subretinal fibrosis was observed in left macula (Figure 11). The patient is being followed with anti-tuberculosis therapy.

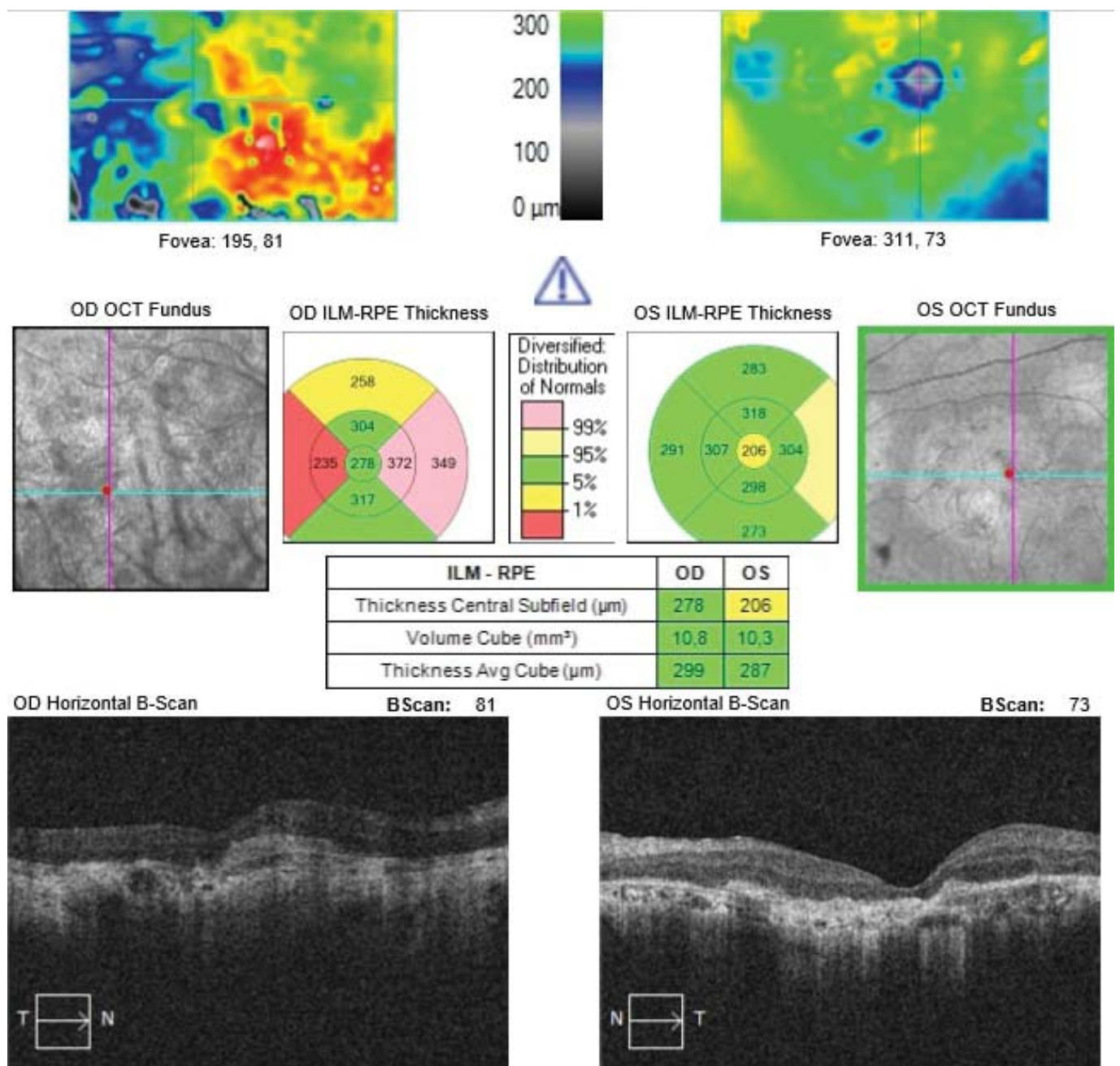
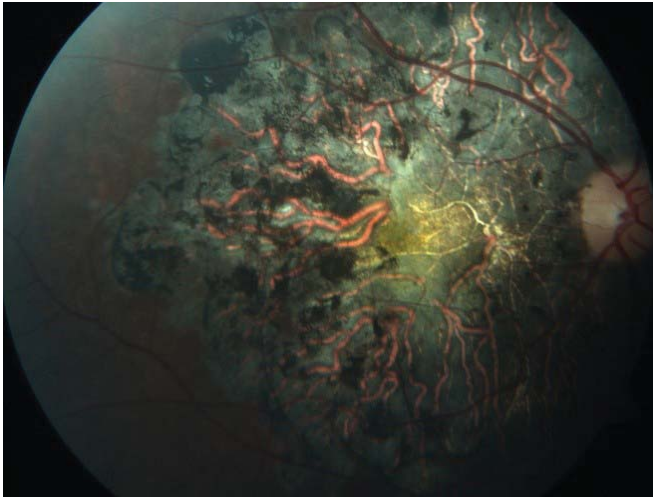
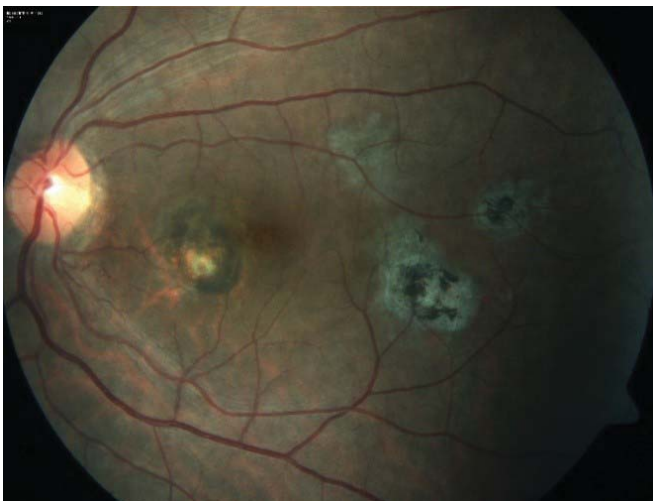


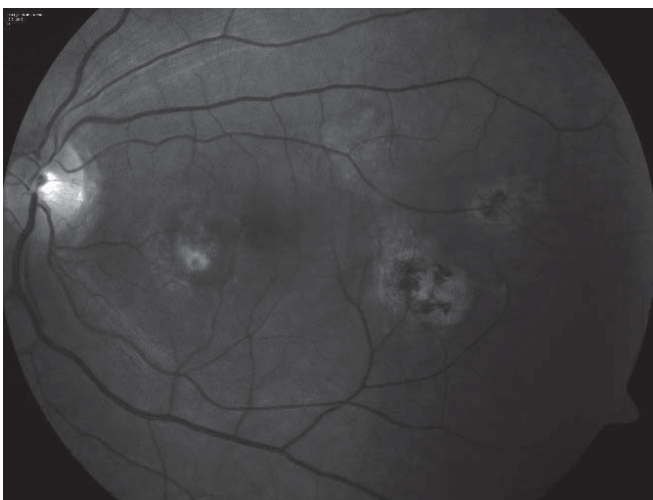
Figure 7: Bilateral subretinal fibrosis in macular on OCT.



**Figure 8:** Scarring is observed in right macula in late follow up fundus pictures



**Figure 9:** Hyper-pigmented and hypo-pigmented lesions are seen in left macula in late follow up fundus pictures



**Figure 10:** Red-free fundus image of left eye.

## DISCUSSION

In developing countries, tuberculosis is a common, opportunistic infection due to poor hygiene, insufficient healthcare services, poverty, drug resistance and HIV infection.<sup>2</sup> Based on epidemiological studies, etiology is tuberculosis in 0.3% of patients with uveitis.<sup>9</sup>

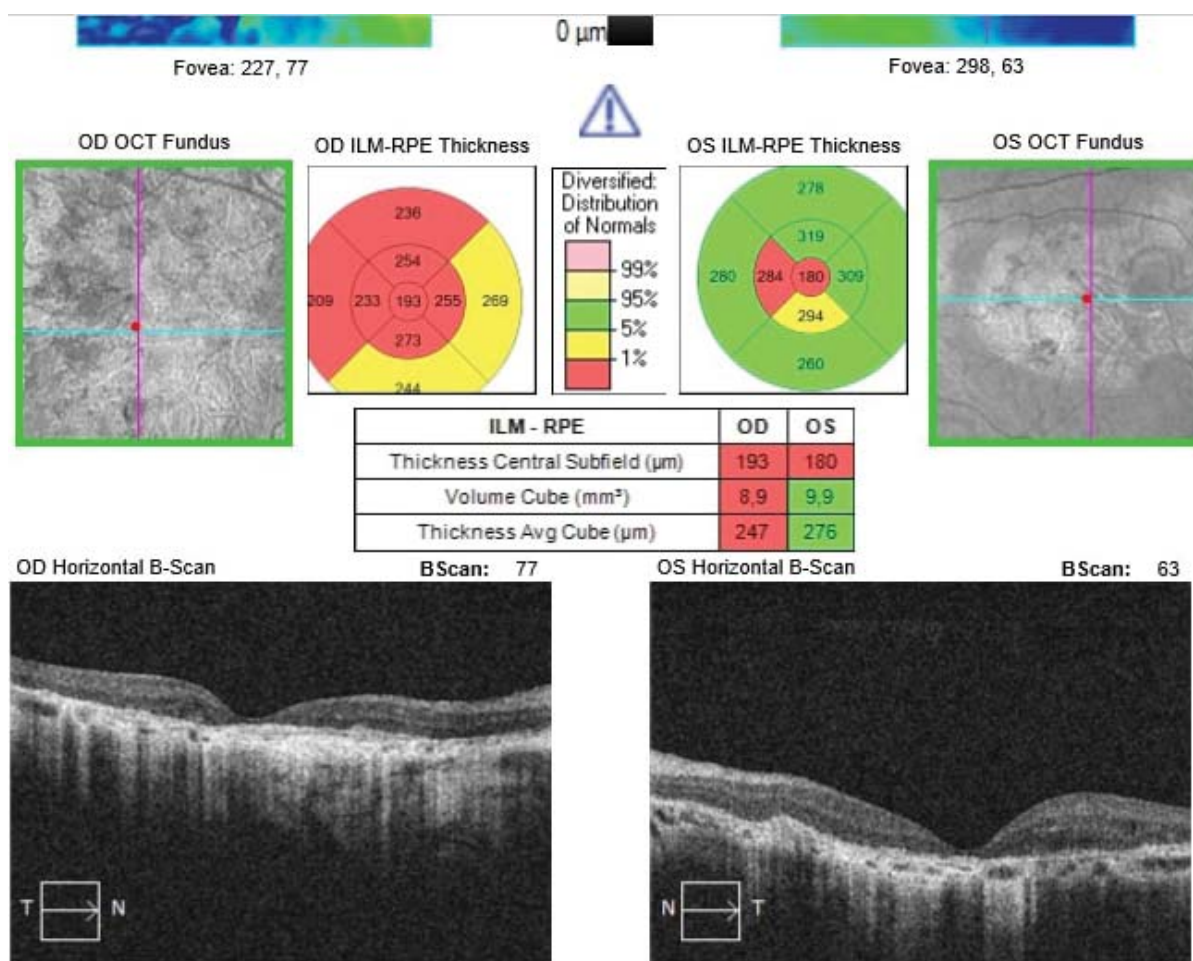
The diagnosis and treatment of ocular tuberculosis is important in order to prevent blindness.<sup>10</sup> The diagnostic criteria for ocular tuberculosis include clinical findings, ancillary tuberculin skin test, imaging studies (chest radiography, CT, FFA and ICG), and isolation of bacteria or its DNA from ocular tissue or fluids.<sup>11</sup>

Kauba et al. retrospectively reviewed 14 patients with ocular tuberculosis who had clinical data and positive tuberculin test between 2006 and 2015. The most common clinical presentation was uveitis (11 patients, 16 eyes) and there was extra-ocular involvement in 3 patients. It was associated with corticosteroid therapy in 11 patients.<sup>12</sup>

In a study, Gupta et al. compared clinical findings between patients with tuberculosis uveitis and non-tuberculosis uveitis. Posterior synechia, retinal vasculitis, iris nodules, serpiginous -like choroiditis and posterior uveitis were significantly more common in patients with tuberculosis uveitis.<sup>13</sup>

Tomkins et al. investigated clinical characteristics of uveitis patients linked to latent tuberculosis and efficacy of anti-tuberculosis treatment regarding outcome of uveitis. Authors found that there was no significant in patients received anti-tuberculosis therapy and those not. Recurrent uveitis was detected in 34.9% of patients. Recurrent uveitis was less common in eyes received anti-tuberculosis therapy (29.5%) compared to those not received (48.2%).<sup>14</sup> In the pathogenesis of tuberculosis uveitis, in addition to infection with bacilli, delayed type hypersensitivity against components of mycobacterial cell wall is also involved. Anterior uveitis related to tuberculosis generally has granulomatous features.<sup>14</sup> In the literature, non-granulomatous anterior uveitis and macular edema were also reported.<sup>15</sup>

The patient diagnosed as uveitis and tuberculosis granuloma in our clinic received anti-tuberculosis therapy for 12 months and no finding of ocular tuberculosis was detected during 2-years follow-up. At the end of year 2, visual complaints were recurred in the patient and tuberculosis granuloma was detected in the patient. In patients with tuberculosis uveitis, it should be aimed to eradicate tuberculosis by multidisciplinary approach using long-term systemic therapy. The patient should be informed about recurrent attacks despite treatment and therapy required should be started promptly.



**Figure 11:** Bilateral subretinal fibrosis in macular on OCT.

## REFERENCES

1. Başarrı B, Karaküçük Y, Altan Ç, et al. A case of presumed tuberculosis uveitis with occlusive vasculitis from an endemic region. Turkish journal of ophthalmology 2017; 47: 169.
2. Gupta V, Gupta A, Rao NA. Intraocular tuberculosis--an update. Survey of ophthalmology 2007; 52: 561-87.
3. Gupta V, Shoughy SS, Mahajan S, et al. Clinics of ocular tuberculosis. Ocular immunology and inflammation 2015; 23: 14-24.
4. Gupta A, Sharma A, Bansal R, et al. Classification of intraocular tuberculosis. Ocular immunology and inflammation 2015; 23: 7-13.
5. Rathinam SR, Cunningham ET, Jr. Infectious causes of uveitis in the developing world. International ophthalmology clinics 2000; 40: 137-52.
6. Abu El-Asrar AM, Abouammoh M, Al-Mezaine HS. Tuberculous uveitis. International ophthalmology clinics 2010; 50: 19-39.
7. Chen EJ, Bin Ismail MA, Mi H, et al. Ocular Autoimmune Systemic Inflammatory Infectious Study (OASIS) - Report 1: Epidemiology and Classification. Ocular immunology and inflammation 2018; 26: 732-46.
8. Önal S, Tuğal-Tutkun İ. Ocular tuberculosis I: epidemiology, pathogenesis and clinical features. 2011; 41: 171-81.
9. Kazokoglu H, Onal S, Tugal-Tutkun I, et al. Demographic and clinical features of uveitis in tertiary centers in Turkey. Ophthalmic epidemiology 2008; 15: 285-93.
10. Thompson MJ, Albert DM. Ocular tuberculosis. Archives of ophthalmology (Chicago, Ill : 1960) 2005; 123: 844-9.
11. Bodaghi B, LeHoang P. Ocular tuberculosis. Current opinion in ophthalmology 2000; 11: 443-8.
12. Koubaa M, Smaoui F, Gargouri S, et al. [Ocular tuberculosis : A case series]. La Revue de medecine interne 2018; 39: 326-31.
13. Gupta A, Bansal R, Gupta V, et al. Ocular signs predictive of tubercular uveitis. American journal of ophthalmology 2010; 149: 562-70.
14. Tomkins-Netzer O, Leong BCS, Zhang X, et al. Effect of Antituberculous Therapy on Uveitis Associated With Latent Tuberculosis. American journal of ophthalmology 2018; 190: 164-70.
15. Metin T, Dinç E, Sarı A, et al. Granülomatöz Olmayan Ön Üveit ve Maküler Ödem: Tüberküloz. Journal of retina -vitreous 2015; 23: 209-12.