

# Short-term Vitreoretinal Tamponade with Perfluorodecalin for Retinal Detachment

Emrah Öztürk<sup>1</sup>, Yakup Yıldızlı<sup>2</sup>, Ercan Özsoy<sup>3</sup>, Abuzer Gündüz<sup>4</sup>

## ABSTRACT

**Purpose:** The aim of this study was to use perfluorodecalin (PFD) as a short-term postoperative vitreoretinal tamponade and evaluate its effectiveness in retinal detachment.

**Materials and Methods:** This retrospective case series consisted of eight consecutive patients (four female, four male) who presented with retinal detachment (traumatic, secondary to inferior retinal tear, presence of proliferative vitreoretinopathy) at a tertiary university medical center in 2018–2019. All patients underwent pars plana vitrectomy with short-term PFD tamponade. Patients with a minimum follow-up of 3 months were included in the study. The medical charts were analyzed for patient demographics, retinal attachment rates, pre- and postoperative visual acuity, and postoperative complications.

**Results:** The mean duration of PFD tamponade was  $16.5 \pm 6.3$  (range, 7–27) days. The mean follow-up time for the patients was  $8.63 \pm 2.5$  months. The retina was reattached intraoperatively in all patients. In seven patients (87.5%), the retina was still attached throughout follow-up without further vitrectomies. A statistically significant increase was observed when preoperative mean best-corrected visual acuity (BCVA) was compared with mean BCVA in the last follow-up visit ( $2.9 \pm 0.3$ ,  $1.3 \pm 0.7$  logMAR respectively,  $p=0.018$ ). In seven (87.5%) patients, BCVA improved postoperatively compared with preoperatively. In the postoperative period, pupillary membrane formation was observed in two (25.0%) patients, retrolental membrane in one (12.5%) patient, and epiretinal membrane in one (12.5%) patient.

**Conclusion:** PFD seems to be safe to use as a short-term postoperative vitreoretinal tamponade, and it is useful in retinal detachment.

**Keywords:** Perfluorodecalin, Retinal detachment, Vitrectomy, Vitreoretinal tamponade.

## INTRODUCTION

Perfluorocarbon liquids (PFCLs) are synthetic fluorinated hydrocarbons fluids that are odorless and colorless, and they have a low viscosity and high-specific gravity (1.7–2.03 times greater than that of water).<sup>1</sup> Their optical clarity and refractive index provide the opportunity for surgical maneuvers under a visible PFCL-fluid interface.<sup>1,2</sup> Because of the high gravity feature of the PFCLs, it flattens the separated retina from the posterior to the anterior. It allows the anterior displacement of the subretinal fluid.<sup>3</sup> Additionally, its low viscosity makes PFCLs easier to use during injection and removal.<sup>4</sup> These properties make PFCLs ideal for intraoperative tools in vitreoretinal surgery.

Postoperative endotamponade is often required following

vitreoretinal surgery. While silicone oil (SO), SF<sub>6</sub> gas, and C<sub>3</sub>F<sub>8</sub> gas are commonly used, each has its advantages and potential complications.<sup>5-7</sup> Recently, some reports have demonstrated that PFCLs may be used for short-medium postoperative endotamponade.<sup>8-10</sup> This is particularly useful for patients with inferior RD who cannot tolerate a face-down position or for recurrent RD that is complicated by advanced proliferative vitreoretinopathy (PVR).<sup>9,11</sup> Although it has advantages, PFCL-related complications have also been described, such as cataract progression, transient intraocular pressure (IOP) elevation, and intraocular inflammation.<sup>5,12</sup>

Although using PFCLs has been successful, as mentioned above, they have not been widely used by vitreoretinal

1- Uz. Dr., Malatya Training and Research Hospital, Department of Ophthalmology, Malatya, Türkiye

2- Asist. Dr., Inonu University School of Medicine, Department of Ophthalmology, Malatya, Türkiye

3- Uz. Dr., Haseki Training and Research Hospital, University of Health Sciences, Department of Ophthalmology, İstanbul, Türkiye

4- Prof. Dr., Inonu University School of Medicine, Department of Ophthalmology, Malatya, Türkiye

Received: 01.11.2020

Accepted: 16.02.2021

Ret-Vit 2021; 30:158-162

DOI: 10.37845/ret.vit.2021.30.27

Correspondence Address:

Emrah Ozturk

Malatya Training and Research Hospital, Department of Ophthalmology, Malatya, Türkiye

Phone: +90 505 659 0191

E-mail: marmaraemrah@hotmail.com

surgeons as a postoperative endotamponade, which is possibly because of its potential to increase the long-term IOP and intraocular inflammation.<sup>5</sup> The purpose of the present study was to describe our experience with short-term PFCLs (perfluorodecalin, PFD) endotamponade following vitreoretinal surgery for RD (traumatic, secondary to inferior retinal tear, presence of PVR) in a tertiary ophthalmology department.

## MATERIALS AND METHODS

This is a retrospective case series of eight eyes from eight consecutive patients (four female, four male) who presented with RD (traumatic, secondary to inferior retinal tear, presence of PVR) at a tertiary university medical center between January 2018 and November 2019. All patients underwent pars plana vitrectomy (PPV) with short-term PFD tamponade.

All participants provided informed consent before surgery. The study adhered to the tenets of the Declaration of Helsinki. This retrospective study was completed after local ethics committee approval.

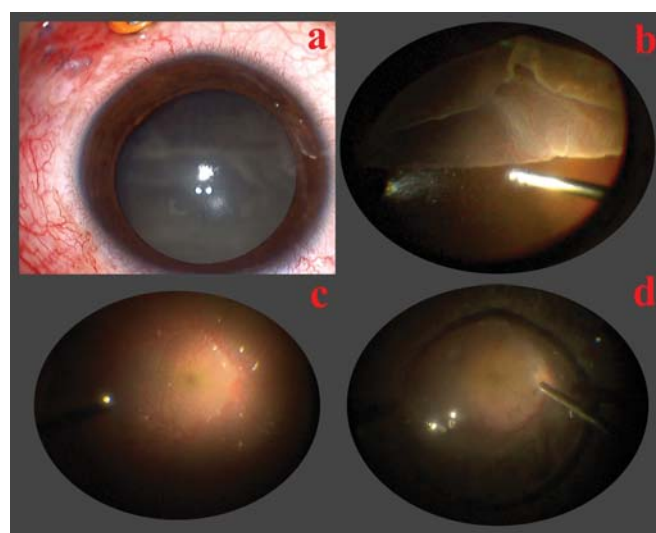
Patients with a follow-up time of 3 months or more were included in the study. Their medical records were reviewed for the following data: patient age and sex, best-corrected visual acuity (BCVA) and IOP at presentation and last visit, indications for vitreoretinal surgery, macula status, PVR grade, duration of intraocular tamponade with PFD and SO, follow-up time, anatomical and functional outcome, and complications. The PVR was classified according to the Retina Society classification system.<sup>13</sup> The BCVA with Snellen, IOP, and dilated retinal examination were evaluated at all pre- and postoperative visits. All BCVA was converted into the logarithm of the minimum angle of resolution (logMAR) for statistical analysis.

The primary outcome measures of the study were the retinal attachment and BCVA at the last follow-up visit, without the need of further vitreoretinal procedures. The secondary outcome measure was complications related to PFD use.

### Surgical technique

All surgeries were performed by the same experienced retinal surgeon using the EVA phaco/vitrectomy system (DORC International). Conventional three-port pars plana 23G vitrectomy was performed with non-contact wide-field viewing system. Cataract surgery was performed for patients who required cataract surgery. A 2.2-mm corneal incision and 5.0–5.5 mm capsulorhexis were performed

in all surgeries. Device parameters were as follows: vacuum limit, 300; aspiration flow rate, 40 mL/min; and ultrasound power, adjusted according to the cataract type and density. The cortical material was removed after phacoemulsification. After implanting the Monofocal Acriva UD 613 (VSY Biotechnology, Istanbul, Turkey) intraocular lens into the capsule bag, the vitrectomy phase was started. After completing core and peripheral vitrectomy, purified PFD (Merdecalin 5, Meran, Istanbul, Turkey) was injected slowly over the optic disc to reattach the retina and continued until a single bubble filled the vitreous cavity (Figure 1). Three to four rows of endolaser photocoagulation were then applied around the tear and to the vitreous base over 360° in all eyes. The sclerotomies were sutured with 7–0 vicryl sutures. The surgery was ended by subconjunctival 8 mg (0.2 mL) triamcinolone acetonide injection.



**Figure 1: Images of preoperative, intraoperative, and perfluorodecalin removal in patient 4.** *a: Primary repair sutures of perforating trauma; b: Giant retinal tear; c: The reattached retina by perfluorodecalin; d: Removal of perfluorodecalin during a second-stage surgery*

Patients were asked to position themselves according to the location of their retinal tears—usually lying on the ipsilateral side or sitting upright for inferior retinal tears. The PFD remained in the vitreous cavity for approximately 16 days, unless otherwise indicated. A second-stage surgery to remove the PFD and replace it with SO (MERSILICON 1000 CST, Meran, Istanbul, Turkey) was performed. During the second stage, endolaser photocoagulation was used for further re-enforcement of the retina if regarded necessary.

**Statistical Analysis**

SPSS for Windows statistical software (ver. 22.0; IBM Corp., Armonk, NY, USA) was used for the analysis. The collected data are summarized using descriptive statistics. The results are expressed as the mean ± standard deviation (SD) or median (min–max). The statistical significance of the changes in IOP and BCVA was determined using a Wilcoxon matched pairs signed rank test. A value of p<0.05 was considered to be statistically significant.

**RESULTS**

Eight patients (eight eyes), four females, and four males were included in the study. The mean age of the patients was 53.50 ± 17.3 years. The preoperative, operative, and outcome parameters are demonstrated in **Table 1**. The mean follow-up time of the patients was 8.63 ± 2.5 months. A history of ocular trauma was noted in three patients, two patients had degenerative myopia, and one underwent a previous vitrectomy. No predisposing factors were detected in two patients. All patients had visual acuity less than counting fingers at 0.5 m, who presented with macula-off RD preoperatively. There was one or multiple

inferior retinal tears in six patients. Two eyes had grade C PVR preoperatively.

The mean duration of PFD tamponade was 16.5 ± 6.3 (range, 7–27) days. The PFD was replaced by SO in all patients. The mean duration of SO tamponade was 5.5 ± 1.8 (range, 3–8) months. The retina was reattached intraoperatively in all patients. In seven patients (87.5%), the retina stayed attached throughout follow-up without further vitrectomies. A patient who had preoperative stage C PVR underwent RD because of new/recurrent PVR formation after initial successful reattachment in the last follow-up visit, and the patient was considered to be inoperable.

A statistically significant increase was observed when preoperative mean BCVA was compared with mean BCVA in the last follow-up visit (2.9 ± 0.3, 1.3 ± 0.7 logMAR respectively, p=0.018). In seven (87.5%) patients, BCVA improved postoperatively compared with preoperatively. There was no statistically significant difference between the mean preoperative IOP and the mean IOP in the postoperative first week (IOP, 13.3 ± 3.2 and 14.8 ± 3.1 respectively, p=0.52). Transient IOP elevation was not observed in any patient during follow-up.

**Table 1:** Preoperative, operative, and outcome parameters in 8 patients treated with vitrectomy and short-term tamponade with perfluorocarbon liquids.

Pt. No.	Predisposing factor	Preoperative fundus status	Preoperative lens status	PFCL time (day)	PVR	BCVA initial	BCVA final	F-U Time (mo)	Final retinal attachment	Complications
1	Degenerative myopia, Pseudophakia	RD due to the inferior retinal tear	Pseudophakic	18	None	HM	,05	8	Yes	-
2	Trauma, Pseudophakia	RD due to the multiple inferior retinal tears	Pseudophakic	14	None	HM	,30	11	Yes	Epiretinal membrane
3	Trauma	RD due to the inferior retinal tear	Phakic	11	None	HM	,10	8	Yes	Lens touch during PPV
4	Perforating trauma	Giant retinal tear	Phakic	14	None	HM	,10	9	Yes	Pupillary membrane
5	Previous ERM surgery	Total RD due to the inferior retinal tear	Pseudophakic	21	None	½ m CF	,10	11	Yes	Retrolental membrane
6	None	Total RD due to the retinal tear	Phakic	20	Stage C	LP	LP	9	No	Pupillary membrane, Posterior synechiae
7	Degenerative myopia, Pseudophakia	Total RD due to the inferior retinal tear	Phakic	7	Stage C	HM	,05	10	Yes	-
8	None	RD due to the inferior retinal tear	Phakic	27	None	HM	2 m CF	3	Yes	-

PFCL, perfluorocarbon liquids; Pt, patient; BCVA, best-corrected visual acuity; F-U, follow-up; mo, months; PPV, pars plana vitrectomy; PVR, proliferative vitreoretinopathy; ERM, epiretinal membrane; LP, light perception; HM, hand motion; CF, counting fingers; RD, retinal detachment.

In the early postoperative period, pupillary membrane formation was observed in two patients (25.0%) and retrolental membrane in one (12.5%) patient. They regressed with medical treatment. Epiretinal membrane development was seen in one patient in the late postoperative period. During the first stage of surgery, in addition to PPV, four patients also underwent cataract surgery. Cataract progression could not be evaluated because we had a limited number of phakic patients, and our follow-up time was relatively short.

## DISCUSSION

Different surgical techniques have been used for RD, including the use of a scleral buckle, SO, intraocular gas, and heavier-than-liquid compounds such as PFD.<sup>14-16</sup> The first use of PFCLs in vitreoretinal surgery was as an adjunct intraoperative tool. Recently, they have been used as a more prolonged duration postoperative endotamponade, with favorable results in cases of RD that are caused by giant retinal tears and inferior retinal tears.<sup>5,9,11,17</sup> The outcomes of our study indicate that a high anatomic success rate can be obtained with short-term postoperative PFD to treat retinal detachment. Despite the requirement for multiple operations and the risk of PFCLs-specific side effects, this technique serves an effective surgical alternative for challenging patients with RD disorders.

The present study demonstrates that the retina was reattached intraoperatively in all patients, and in seven of the patients (87.5%), the retina remained attached throughout follow-up without further vitrectomies. Our findings are consistent with four previous studies that used a similar approach in a series of 13 eyes, 16 eyes, 39 eyes, and 62 eyes.<sup>5,10,17,18</sup> All these studies reported a 100% initial reattachment rate and final reattachment rates of around 93% (92%, 93.5%, 92.4%, and 93.7%, respectively). Failure of RD surgery in eyes with an inferior retinal tear or PVR can be related to the ineffective tamponade to the retina by gas or SO, which can allow fluid to leak under the edge of the tear before the firm chorioretinal adhesion occurs. Postoperative PVR is the major cause of failure and redetachment. Theoretically, PFCLs can reduce postoperative inferior PVR formation as they displace inflammatory cells and mediators from the inferior retinal surface.<sup>12</sup> The use of PFCLs as postoperative endotamponade may have increased surgical success because of effective tamponade and decreased PVR formation. It should be kept in mind as one of the first options, especially in patients with advanced PVR and giant inferior retinal tears.

Mikhail et al. demonstrated that visual acuity increased in 70% of patients with 90.9% final retinal re-attachment in

their study using PFCLs as a postoperative tamponade.<sup>12</sup> Randolph et al. reported that 11 (48%) eyes showed vision improvement, four (17%) eyes had no change, and eight (35%) eyes had decreased vision in their study using PFCLs as a postoperative tamponade. They achieved final retinal re-attachment in 69.5% of the eyes.<sup>19</sup> In our study, visual acuity increased in 87.5% of patients. This higher rate may result from the macular-off retinal detachment in all patients and lower preoperative visual acuity in all patients. Furthermore, the high rate of final retinal re-attachment in our patients may result in high visual acuity because macular detachment is mostly related to lower visual acuity.

Use of short-term perfluorocarbon is aimed to increase surgical success by applying an effective postoperative endotamponade, especially in cases that tolerate a face-down position and for recurrent RD that is complicated by PVR. Furthermore, postoperative PVR, which is the primary cause of failure and redetachment, can be reduced by PFCLs because they displace inflammatory cells and mediators from the inferior retinal surface.<sup>12</sup> Therefore, the use of PFCLs as postoperative endotamponade may have increased surgical success because of effective tamponade and decreased PVR formation.

Although PFCLs have advantages, PFCL-related complications such as cataract progression, IOP elevation and intraocular inflammation have also been described.<sup>5,12</sup> Vitreoretinal surgeons do not widely use PFCLs as postoperative endotamponade due to their potential complications. Our postoperative complications were similar to previously published reports that used PFCLs as a short-term postoperative tamponade.<sup>10,12,18</sup> Only one patient (12.5%) who had an epiretinal membrane in our study developed long-lasting complications that affected the final visual outcome that may be related to PFCLs. In previous similar publications, the frequency of epiretinal membrane formation has been reported as 4.1–25%.<sup>12,18</sup> A well-defined complication of PFCLs is the foreign body reaction. It is characterized by multiple white precipitates within the indwelling PFCLs. Previous studies reported that the frequency of foreign body reaction was 28.0–30.4% with postoperative PFCLs.<sup>19,20</sup> A typical foreign body reaction was not observed in any patient in our study, which may be because of the surgery was completed using subconjunctival triamcinolone acetonide injection. Sigler et al. demonstrated that the frequency of transient inflammation 32% in the study where they used PFCLs postoperatively for 2–3 weeks.<sup>9</sup> Similarly, in our study, transient inflammation was observed in 37.5% of patients, two of whom had a pupillary membrane and one of whom



had retrolental membrane. It was resolved with topical anti-inflammatory treatment.

In conclusion, PFD appears to be safe to use as a short-term postoperative vitreoretinal tamponade, and it is useful in RD. Supine positioning is also more manageable from the patient's perspective. This study may be restricted by the retrospective data collection, the relatively small sample size, and the absence of a control group. A larger randomized, controlled study is required to further compare the safety and efficacy of short-term postoperative PFD tamponade with postoperative SO tamponade.

**Acknowledgments:** The authors have no proprietary or financial interest in any products used in this study. The manuscript was edited by American Manuscript Editors.

## REFERENCES

1. Figueroa MS, Casas DR. Inflammation induced by perfluorocarbon liquid: intra- and postoperative use. *Biomed Res Int*. 2014;2014:907816.
2. Sargent JW, Seffl RJ. Properties of perfluorinated liquids. *Fed Proc*. 1970;29:1699-703.
3. Sparrow JR, Jayakumar A, Berrocal M, et al. Experimental studies of the combined use of vitreous substitutes of high and low specific gravity. *Retina*. 1992;12:134-40.
4. Chang S. Low viscosity liquid fluorochemicals in vitreous surgery. *Am J Ophthalmol*. 1987;103:38-43.
5. Eiger-Moscovich M, Gershoni A, Axer-Siegel R, et al. Short-Term Vitreoretinal Tamponade with Heavy Liquid Following Surgery for Giant Retinal Tear. *Curr Eye Res*. 2017;42:1074-8.
6. Vardanyan AH, Hovakimyan AV, Hambartsumyan AV. Results of surgical treatment of retinal detachments complicated with proliferative vitreoretinopathies with the use of perfluoropropane (C3F8) gas. *Med Sci Monit*. 2000;6:704-7.
7. Zafar S, Bokhari SA, Kamil Z, et al. Outcomes of silicone oil removal. *J Coll Physicians Surg Pak*. 2013;23:476-9.
8. Drury B, Bourke RD. Short-term intraocular tamponade with perfluorocarbon heavy liquid. *Br J Ophthalmol*. 2011;95:694-8.
9. Sigler EJ, Randolph JC, Calzada JI, et al. Pars plana vitrectomy with medium-term postoperative perfluoro-N-octane for recurrent inferior retinal detachment complicated by advanced proliferative vitreoretinopathy. *Retina*. 2013;33:791-7.
10. Rush R, Sheth S, Surka S, et al. Postoperative perfluoro-N-octane tamponade for primary retinal detachment repair. *Retina*. 2012;32:1114-20.
11. Sigler EJ, Randolph JC, Calzada JI, et al. 25-gauge pars plana vitrectomy with medium-term postoperative perfluoro-n-octane tamponade for inferior retinal detachment. *Ophthalmic Surg Lasers Imaging Retina*. 2013;44:34-40.
12. Mikhail MA, Mangioris G, Best RM, et al. Management of giant retinal tears with vitrectomy and perfluorocarbon liquid postoperatively as a short-term tamponade. *Eye (London, England)*. 2017;31:1290-5.
13. The classification of retinal detachment with proliferative vitreoretinopathy. *Ophthalmology*. 1983;90:121-5.
14. Al-Khairi AM, Al-Kahtani E, Kangave D, et al. Prognostic factors associated with outcomes after giant retinal tear management using perfluorocarbon liquids. *Eur J Ophthalmol*. 2008;18:270-7.
15. Goezinne F, EC LAH, Berendschot TT, et al. Low redetachment rate due to encircling scleral buckle in giant retinal tears treated with vitrectomy and silicone oil. *Retina*. 2008;28:485-92.
16. Batman C, Cekic O. Vitrectomy with silicone oil or long-acting gas in eyes with giant retinal tears: long-term follow-up of a randomized clinical trial. *Retina*. 1999;19:188-92.
17. Sirimaharaj M, Balachandran C, Chan WC, et al. Vitrectomy with short term postoperative tamponade using perfluorocarbon liquid for giant retinal tears. *Br J Ophthalmol*. 2005;89:1176-9.
18. Rofail M, Lee LR. Perfluoro-n-octane as a postoperative vitreoretinal tamponade in the management of giant retinal tears. *Retina*. 2005;25:897-901.
19. Randolph JC, Diaz RI, Sigler EJ, et al. 25-gauge pars plana vitrectomy with medium-term postoperative perfluoro-n-octane for the repair of giant retinal tears. *Graefes Arch. Clin. Exp. Ophthalmol*. 2016;254:253-7.
20. Sigler EJ, Randolph JC, Charles S. Foreign body response within postoperative perfluoro-N-octane for retinal detachment repair: clinical features, grading system, and histopathology. *Retina*. 2014;34:237-46.