

Foveal Tear Secondary to Blunt Ocular Trauma

Künt Göz Travmasına Bağlı Gelişen Fovea Yırtığı

Zeynep ALKIN¹, Abdullah ÖZKAYA¹, Ahmet Taylan YAZICI², Ahmet DEMİROK³

ABSTRACT

A thirteen-year-old male presented with sudden visual loss after being hit with a hard object in the right eye five days before. His visual acuity was in hand motions level. Fundus examination showed an envelope-shaped foveal tear, and a shallow retinal detachment at the posterior pole with an additional small retinal break temporal to the fovea. Optical coherence tomography confirmed the presence of full thickness neuroretinal tear in the fovea associated with intact Bruch's membrane/retinal pigment epithelium complex. The patient underwent three-port pars plana vitrectomy, internal limiting membrane peeling and injection of silicone oil tamponade. Visual acuity improved to 20/1250 after three months of follow-up and retina was attached despite the presence of a large neurosensorial retinal defect at the macula. Although foveal tear and retinal detachment were successfully treated by pars plana vitrectomy and silicone oil tamponade, prognosis of this type of injury was not favorable and visual outcome was poor.

Key Words: Blunt ocular trauma, foveal tear, retinal detachment.

ÖZ

On üç yaşında erkek hasta beş gün önce sağ gözüne sopa çarpmasından sonra ani olarak gelişen görme kaybı şikayeti ile başvurdu. Görme keskinliği el hareketleri düzeyindeydi. Fundus muayenesinde zarf şeklinde fovea yırtığı ve arka kutupta fovea temporalinde küçük bir yırtığın daha eşlik ettiği sıg retina dekolmanı mevcuttu. Optik koherens tomografi ile foveada tam kat nöral retinal yırtık ile beraber Bruch membranı/retina pigment epiteli kompleksinin sağlam olduğu saptandı. Hastaya üç girişli pars plana vitrektomi, internal limitan membran soyulması ve silikon yağı tamponadı uygulandı. Üçüncü ayda görme keskinliği 20/1250 seviyesine yükseldi. Foveadaki geniş nörosensoryel retina defektine karşın retina yatışık kaldı. Foveadaki yırtığın ve retina dekolmanının pars plana vitrektomi ve silikon yağı tamponadı ile başarılı bir şekilde tedavi edilmesine karşın, bu tip bir lezyonun prognozunun iyi olmadığı ve görmenin düşük kaldığı görüldü.

Anahtar Kelimeler: Künt göz travması, fovea yırtığı, retina dekolmanı.

INTRODUCTION

Blunt eye traumas may cause a variety of pathologies at the posterior segment due to mechanical deformation and/or energy delivery to the ocular structures. The results of a blunt trauma with high velocity objects include commotio retina, traumatic macular hole, retinal detachment, retinal tears, choroidal rupture or optic nerve avulsion.¹

The traumatic retinal tears or breaks usually occur at the peripheral retina-anterior to the equator.² There were also some occasional case reports of traumatic retinal breaks located along the vascular arcades in patients with pathologic myopia;³ however, to our knowledge, this is the first reported case with a retinal tear formation at the macula after a blunt trauma.

- 1- M.D. Beyoglu Eye Training and Research Hospital, Retina Clinic, Istanbul/TURKEY
ALKIN Z., zalkin@ttmail.com
ÖZKAYA A., abdozkaya@gmail.com
- 2- M.D. Associate Professor, Beyoglu Eye Training and Research Hospital, Retina Clinic, Istanbul/TURKEY
YAZICI A.T., ahmettaylan19@gmail.com
- 3- M.D. Professor, Istanbul Medeniyet University Department of Ophthalmology, Istanbul/TURKEY
DEMİROK A.,

Geliş Tarihi - Received: 08.01.2013
Kabul Tarihi - Accepted: 01.02.2013
Ret-Vit 2014;22:140-142
Yazışma Adresi / Correspondence Address: M.D. Zeynep ALKIN
Beyoglu Eye Training and Research Hospital, Retina Clinic,
Istanbul/TURKEY

Phone: +90 505 270 36 58
E-Mail: zalkin@ttmail.com

CASE REPORT

A thirteen-year-old male was referred to our hospital's retina department five days after a blunt trauma. In the history, the patient reported that he was hit with a hard object in the right eye. The best corrected visual acuity was in hand motions level, in the right eye. Anterior chamber examination showed no abnormality, and intraocular pressure was 12 mmHg, in the right eye. The eye was not myopic and axial length was 21.48 mm, in the right eye. Fundus examination revealed an envelope-shaped, full-thickness retinal tear with folded flaps, one disc in diameter which was located at the macula, and an accompanying smaller retinal tear temporal to the fovea was also noted (Figure 1a). Trace amount of erythrocytes was present in the vitreous cavity and posterior hyaloid surface was attached to the retina along the borders of the tear. Optical coherence tomography (OCT) confirmed the presence of full-thickness retinal tear with accompanying sensorial retinal detachment while Bruch's membrane/retinal pigment epithelium complex remained intact (Figure 1b).

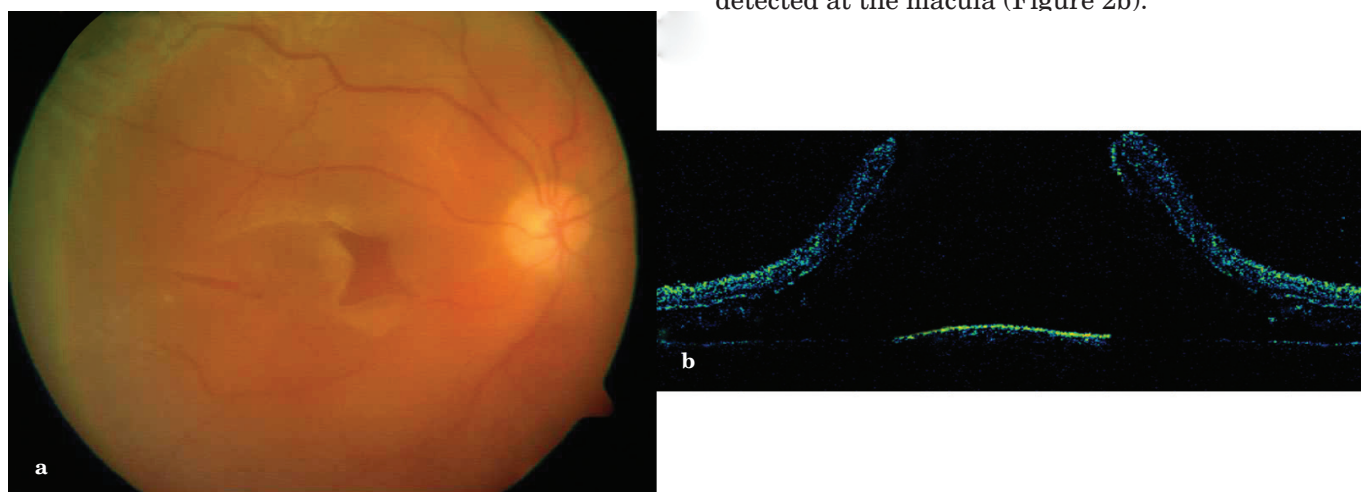


Figure 1a,b: An envelope-shaped full-thickness foveal tear and small retinal tear temporal to the macula (a). Horizontal cross-sectional OCT imaging shows retinal flaps and minimal subretinal fluid (b).

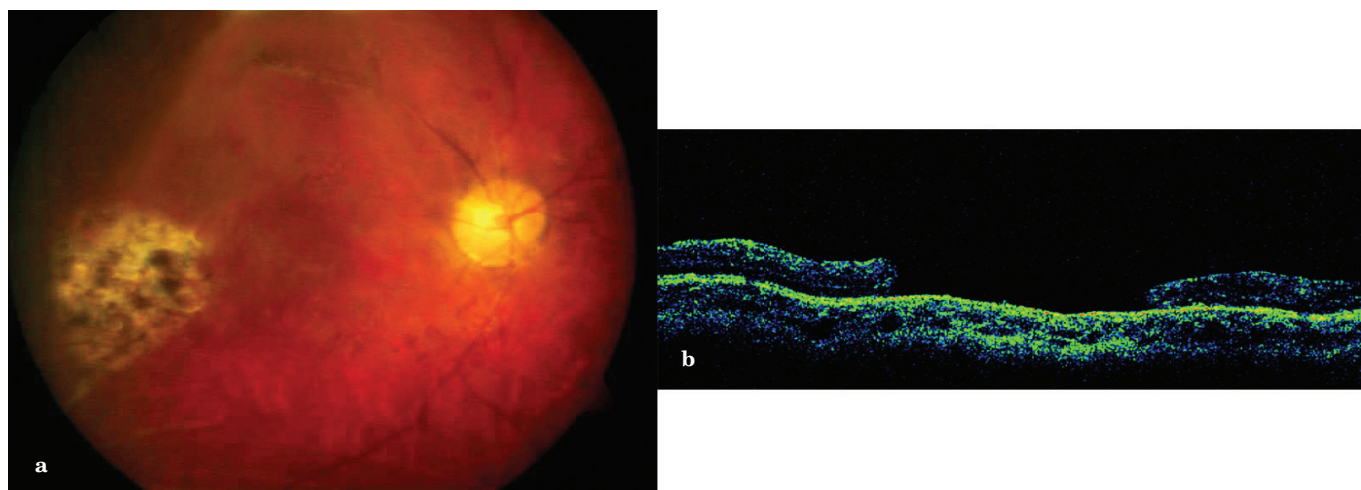


Figure 2a,b: Fundus picture shows retinal pigment epithelial atrophy in the fovea and sealed temporal retinal tear (a). A large neurosensory defect in OCT image three months after surgery (b).

Informed consent for vitreoretinal surgery was obtained from the patient's family and, he underwent a 23 G three-port pars plana vitrectomy (PPV) under general anesthesia. During the operation, a piece of retinal tissue that was assumed to be separated from the borders of the large tear was detected. The retinal flaps along the borders of the tear were folded and rigid. Internal limiting membrane (ILM) peeling was performed using an ILM forceps (DORC, Zuidland, Netherlands) in order to eliminate any possible traction and promote complete retinal attachment. Flaps were unfolded and retinal attachment was achieved by a fluid-air exchange, which was followed by injection of silicone oil.

Three months following the surgery, the best corrected visual acuity improved to 20/1250. The retina remained attached, but a full thickness retinal defect that corresponded to the original retinal tear was present at the macula with an atrophic retinal pigment epithelium layer (Figure 2a). Optical coherence tomography confirmed the absence of retinal detachment, but a large neurosensory retinal defect was detected at the macula (Figure 2b).

DISCUSSION

Previous studies reported that concussion of the posterior pole or the impact of the tangential and anterior-posterior forces at the fovea are usually responsible for the formation of traumatic macular lesions.^{4,5} We suggest that our patient's tear might have been caused by a mechanism similar to that of a traumatic macular hole. The attached posterior vitreous detected at the presentation, supports the hypothesis of direct mechanical injury in this case.

Baba et al.,⁶ reported an unusual vertical splitting of the macula accompanied by a giant retinal tear in a patient with cognitive disorder. They reattached the retina with pars plana vitrectomy, silicone oil tamponade, and scleral buckling. The mechanism of the break formation was not clearly explained in their study. In our patient, we noted that the retinal flaps were folded and stiff during vitreoretinal surgery; therefore, ILM was peeled in order to achieve complete retinal attachment, and to eliminate any possible traction. Proliferative vitreoretinopathy (PVR) might develop following severe ocular trauma-usually after penetrating injuries.⁷ Peeling of ILM and removal of any visible membranes has been suggested as an effective technique in PVR-related recurrent detachments.⁸

Despite the peeling of ILM, end-to-ending the flaps of the tear was not achieved successfully due to the loss of a piece of retinal tissue. We assumed that separated retinal tissue might have originated from the borders of the flap during posterior vitreous detachment, or occurred secondary to the necrosis of the retinal tissue during the initial mechanical impact. Silicon oil usually provides a much longer duration of retinal tamponade, which is also important for prevention of PVR; therefore, we preferred silicone oil as our case was complicated.

Herein, we presented an unusual case with an interesting lesion morphology. The macular tear was successfully treated with pars plana vitrectomy, and silicone oil tamponade. The visual recovery was limited despite the appropriate surgical treatment methods because of the large neurosensorial retinal defect located at the macula.

KAYNAKLAR/REFERENCES

1. Williams DF, Mieler WF, Williams GA. Posterior segment manifestations of ocular trauma. *Retina* 1990;10:35-44.
2. Johnston PB. Traumatic retinal detachment. *Br J Ophthalmol* 1991;75:18-21.
3. Chen L, Wang K, Esmaili DD, et al. Rhegmatogenous retinal detachment due to paravascular linear retinal breaks over patchy chorioretinal atrophy in pathologic myopia. *Arch Ophthalmol* 2010;128:1551-4.
4. Yanagiya N, Akiba J, Takahashi M, et al. Clinical characteristics of traumatic macular holes. *Jpn J Ophthalmol* 1996;40:544-7.
5. Gaudric A, Haouchine B, Massin P, et al. Macular hole formation: new data provided by optical coherence tomography. *Arch Ophthalmol* 1999;117:744-51.
6. Baba T, Tatsumi T, Oshitari T, et al. Case of retinal detachment due to retinal break splitting macula vertically in a patient with cognitive disorder. *Clin Ophthalmol* 2011;5:411-3.
7. Cardillo JA, Stout JT, LaBree L, et al. Post-traumatic proliferative vitreoretinopathy. The epidemiologic profile, onset, risk factors, and visual outcome. *Ophthalmol* 1997;104:1166-73.
8. Minarcik JR, von Fricken MA. Virtual retinectomy: indocyanine green-assisted internal limiting membrane peeling as a surgical adjunct in repair of recurrent rhegmatogenous retinal detachment due to PVR. *Clin Ophthalmol* 2012;6:631-6.