

# Quick Resolution of Serous Macular Detachment After HBO Therapy in an Atypical Toxoplasmic Retinochoroiditis

## Atipik Toksoplazmik Retinokoroiditte HBO Tedavisi Sonrasında Seröz Maküler Dekolmanın Hızlı Rezolüsyonu

Önder AYYILDIZ<sup>1</sup>, Murat KÜÇÜKEVCİLİOĞLU<sup>1</sup>, Gökhan ÖZGE<sup>1</sup>, A. Hakan DURUKAN<sup>2</sup>, Cem ÖZGÖNÜL<sup>3</sup>, Seçkin AYKAŞ<sup>1</sup>

### ABSTRACT

We herein report an atypical toxoplasmic retinochoroiditis case in which serous macular detachment (SMD) responded quickly to HBO therapy. A 24-year-old male patient referred to our department complaining of decreased vision in his left eye. Fundoscopy revealed an old retinochoroidal scar, and deep retinal whitening 2 disc diameters in size adjacent to the old scar with a large SMD exceeding the vascular arcades. Though the antibodies were negative, the diagnosis of toxoplasmic retinochoroiditis was made. Since the main reason for decreased vision was SMD, and ischemic properties of the disease he was offered and then had 20 sessions of HBO therapy. Serous macular detachment was completely resolved after 10 sessions of HBO therapy, and a small scar with full vision was observed at 1-month visit. Based on our current experience HBO therapy may have a potential use in toxoplasmic retinochoroiditis with ischemic complications such as SMD, retinal vascular occlusions, macular edema or choroidal neovascularizations.

**Keywords:** Toxoplasma, retinochoroiditis, hyperbaric oxygen, serous macular detachment.

### ÖZ

Hiperbarik oksijen (HBO) tedavisine hızla cevap veren seröz makula dekolmanının (SMD) geliştiği atipik toksoplazmik retinokoroiditli bir olguyu bildirmekteyiz. Yirmi dört yaşında erkek hasta sol gözünde görme azalması şikayeti ile kliniğimize sevk edildi. Fundoskopide eski bir retinokoroidal skar ve vasküler arkadları aşan SMD ile birlikte eski skar alanına komşu 2 disk çapında derin bir retinal beyazlanma alanı izlendi. Antikorların negatif olmasına rağmen toksoplazmik retinokoroidit tanısı konuldu. Görme azalmasının ana nedeni SMD ve hastalığın iskemik özellikleri olduğundan hastaya HBO tedavisi önerildi ve 20 seans HBO tedavisi aldı. On seans HBO tedavisi sonrasında SMD tamamen düzeldi ve 1 ay sonra küçük bir skarla birlikte görmenin tama çıktığı gözlemlendi. Mevcut tecrübemiz göre SMD, retinal vasküler tıkanmalar, maküler ödem veya koroidal neovaskülarizasyonlar gibi iskemik komplikasyonlar ile birlikte olan toksoplazmik retinokoroiditte HBO tedavisi potansiyel bir kullanıma sahip olabilir.

**Anahtar Kelimeler:** Toksoplazma, retinokoroidit, hiperbarik oksijen, seröz maküler dekolmanı

*\*This work was presented at the June 6-9, 2015 Congress (Vienna / Austria).*

- 1- M.D. GATA Medical Faculty, Department of Ophthalmology, Ankara/TURKEY  
AYYILDIZ O., dronderayyildiz@gmail.com  
KUCUKEVCILIOGLU M., mkucukevcilioglu.gata.edu.tr  
OZGE G., gozge.gata.edu.tr  
AYKAS S., seckinaykas@hotmail.com
- 2- M.D. Professor, GATA Medical Faculty, Department of Ophthalmology,  
Ankara/TURKEY  
DURUKAN H.A., ahakand@yahoo.com
- 3- M.D. Van Military Hospital, Ophthalmology Department, Van, Turkey  
OZGONUL C., cemozgonul@hotmail.com

**Geliş Tarihi - Received:** 28.02.2016  
**Kabul Tarihi - Accepted:** 15.03.2016  
**Ret-Vit 2016;24:327-329**

**Yazışma Adresi / Correspondence Adress:**  
M.D. Onder AYYILDIZ  
GATA Medical Faculty, Department of Ophthalmology, Ankara/TURKEY

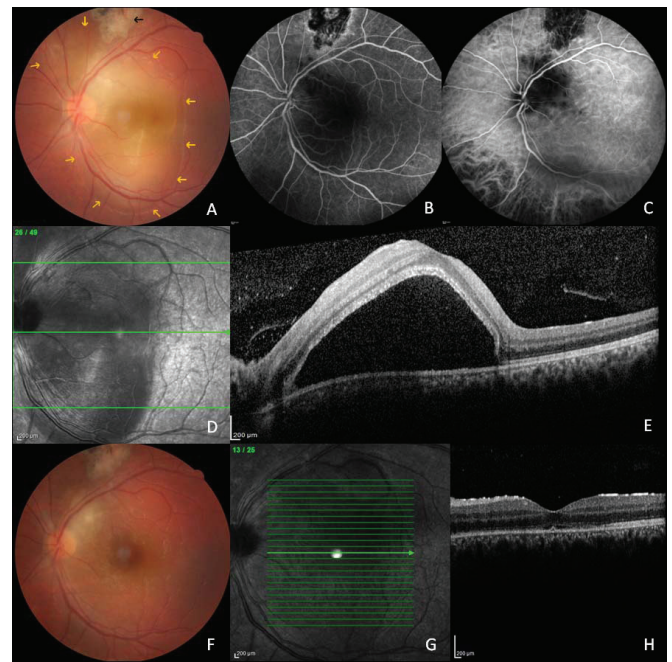
**Phone:** +90 505 253 86 90  
**E-mail:** dronderayyildiz@gmail.com

## INTRODUCTION

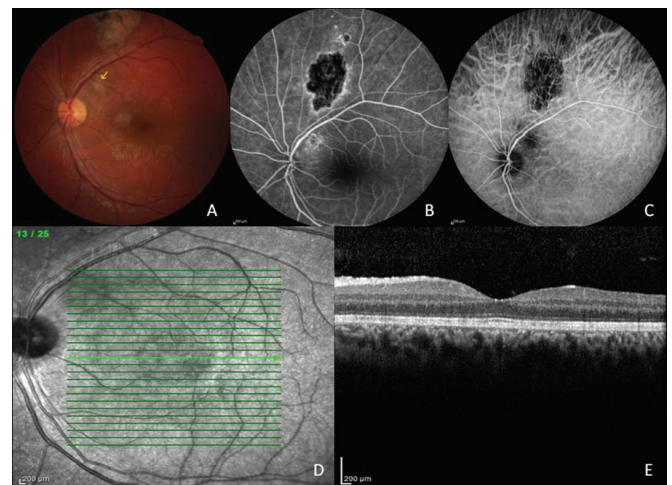
Toxoplasmic retinochoroiditis (RC) is the most common cause of infectious uveitis in many countries.<sup>1</sup> The diagnosis is straightforward in many cases by the observation of unilateral focal necrotising retinochoroiditis with/without associated retinochoroidal scars and the presence of specific IgG antibodies.<sup>2</sup> One of the atypical presentations serous macular detachment (SMD) has rarely been reported.<sup>3,4</sup> In a large series of Khairallah et al (9 out of 60 eyes), SMD in toxoplasmic RC was found to have choroidal ischemia correlates and a good prognosis.<sup>5</sup> With the current case report we want to provide a supportive but infantile data for potential use of hyperbaric oxygen (HBO) therapy in toxoplasmic RC.

## CASE REPORT

A male patient, aged 24 years, referred to our department complaining of a decrease in visual acuity in his left eye, for the duration of 6 hours. At initial visit, the vision was full in the right eye and 0.1 in the left eye. The pupillary reactions, ocular motilities and slit lamp examinations were normal. The intraocular pressures were in normal ranges, and blood laboratories were normal. Fundoscopy of the left eye revealed a pigmented retinochoroidal scar 3-4 disc diameters in size that is just above the upper vascular arcade, and deep retinal whitening 2 disc diameters in size that is adjacent to the old scar with a large SMD exceeding the major vascular arcades (Figure 1A). Optical coherence tomography (OCT) demonstrated a large and high SMD (Figure 1D and 1E). Fluorescein angiography (FA) showed a hypofluorescent area with hyperfluorescence in the center and on borders corresponding to the pigmented scar, and hyperfluorescence in the macula related to SMD (Figure 1 B). Hypofluorescent dots were also seen in the vicinity of retinal whitening throughout the study. Indocyanin green angiography (ICGA) showed a large area of choroidal ischemia with scattered hypofluorescent dots (Figure 1C). Though the specific antibodies were negative, the diagnosis of toxoplasmic RC was made. Since the main reason for decrease in vision was SMD, and ischemic properties of the disease the patient was offered and then had 10 sessions of HBO therapy. After this the area of deep retinal whitening and the height of SMD were decreased, and vision was arised to 0.6 (Figure 1F, 1G and 1H). A 10 sessions HBO therapy was applied again. One month after the admission there was a small scar one disc away from the optic disc, and no SMD on OCT with full vision in the left eye (Figure 2A, 2D and 2E). Fluorescein angiography showed similar characteristics to big scar, and ICGA showed choroidal atrophy with few satellite hypofluorescent dots (Figure 2B and 2C).



**Figure 1A-H:** Fundus photography shows the old scar (black arrow) and deep retinal whitening associated with a large serous macular detachment (yellow arrows) (A); early venous FA demonstrates the hypofluorescent dots which are more evident on intermediate ICGA (B, C); OCT reveals a high SMD (D, E). After ten days of HBO therapy the area of deep retinal whitening and SMD were smaller (F,G and H).



**Figure 2A-E:** At one month visit active focus of RC was healed with a small scar (A; yellow arrow); FA showed similar characteristics to big scar (B); and ICGA showed choroidal atrophy with few satellite hypofluorescent dots (C); and there was no SMD on OCT (D and E).

## DISCUSSION

Hypofluorescent dots seen on ICGA were first thought as inflammatory or infectious foci, however, later non-perfusion of the choriocapillaris or choroid was postulated as the causative mechanism by the same group,<sup>6</sup> which was further supported in Khairallah et al's study.<sup>5</sup> The efficacy of HBO therapy is based on a reduction in volume of gas filled spaces and elevation of the partial pressure of oxygen resulting in hyperoxygenation of targeted tissues.

The primary ocular indications for HBO therapy are mainly of vascular origin with low perfusion conditions (occlusive retinal vascular diseases, macular edema of vascular origin, avascular scleral necrosis, anterior segment ischemia etc.).<sup>7,8</sup> Based on this knowledge and our experience with the current case HBO therapy may have a potential use in toxoplasmic RC with retino-choroidal ischemic complications such as SMD, retinal vascular occlusions, macular edema or choroidal neovascularizations.

#### REFERENCES/KAYNAKLAR

1. Hasanreisoglu M., Sengül Ö. Ocular Toxoplasmosis: Epidemiology, Transmission, Pathogenesis, Population Biology, Clinical Manifestations, Diagnosis and Treatment. *Journal of Retina-Viteus*. 2013;21:235-246.
2. Rothova A. Ocular involvement in toxoplasmosis. *Br J Ophthalmol*. 1993;77:371-77.
3. Kraushar MF, Gluck SB, Pass S. Toxoplasmic retinochoroiditis presenting as serous detachment of the macula. *Ann Ophthalmol*. 1979;11:1513-14.
4. Aslankurt M, Aslan L, Çekiç O. Serous Macular Detachment Related to Extramacular Toxoplasma Chorioretinitis. *Journal of Retina-Viteus*. 2011;19:71-2.
5. Khairallah M, Kahloun R, Ben Yahia S, Jelliti B. Clinical, tomographic, and angiographic findings in patients with acute toxoplasmic retino-choroiditis and associated serous retinal detachment. *Ocul Immunol Inflamm*. 2011;9:307-310.
6. Guex-Crosier Y, Auer C, Bernasconi O, Herbort CP. Toxoplasmic retinochoroiditis: resolution without treatment of the perilesional satellite dark dots seen by indocyanine green angiography. *Graefes Arch Clin Exp Ophthalmol*. 1998;236:476-78.
7. Kiryu J, Ogura Y. Hyperbaric oxygen treatment for macular edema in retinal vein occlusion: relation to severity of retinal leakage. *Ophthalmologica*. 1996;210:168-170.
8. Chang YH, Chen PL, Tai MC, et al. Hyperbaric oxygen therapy ameliorates the blood-retinal barrier breakdown in diabetic retinopathy. *Clin Experiment Ophthalmol*. 2006;34:584-89.