

# Treatment of Subhyaloid Hemorrhages in Valsalva Retinopathy After Cataract Surgery

## Katarakt Cerrahisi Sonrası Valsalva Retinopatisine Bağlı Gelişen Subhyaloid Kanama ve Tedavisi

*İbrahim Çağrı TÜRKER<sup>1</sup>, Semra TIRYAKI DEMİR<sup>2</sup>, Dilek GÜVEN<sup>2</sup>, Yekta ŞENDÜL<sup>2</sup>, Ayşe Burcu DİRİM<sup>2</sup>, Ali OLGUN<sup>2</sup>*

### ABSTRACT

VR is a rare condition that causes a sudden vision loss. Although VR is considered to be rare but a serious complication of surgery. Our case was a 64 years old woman was presented with preretinal haemorrhage including macular area in right eye secondary to VR after an uneventful cataract surgery under general anesthesia. Her vision was counting fingers after the surgery. Although surgical correction or Nd:YAG laser hyaloidotomy was available she was treated with single intravitreal TPA, intravitreal bevacizumab and 0.2cc SF6 gase injection. There was significant reduction of premacular haemorrhage and her vision improved to 7/10 after injection on the final visit.

**Key Words:** Subhyaloid Hemorrhages, Valsalva Retinopathy, Cataract Surgery.

### ÖZ

Valsalva retinopatisi (VR) ani görme kaybına neden olabilen nadir bir durumdur. VR nadir görülmekle birlikte önemli bir cerrahi komplikasyondur. 64 yaşında bayan hastada komplikasyonsuz katarakt cerrahisi sonrası VR'ne bağlı makuler alanı içine alan preretinal kanama saptanmıştır. Cerrahi sonrası hastanın görme seviyesi el hareketi düzeyindedir. Cerrahi tedavi veya Nd:YAG lazer hyaloidotomi mümkün olsa da hastamız intravitreal TPA, intravitreal bevacizumab ve 0.2cc SF6 gaz injeksiyonu ile tedavi edilmiştir. Son muayenede premakuler kanamada gerileme saptanmış ve hastanın görmesi 7/10 düzeyine yükselmiştir.

**Anahtar Sözcükler:** Subhyaloid Kanama, Valsalva Retinopatisi, Katarakt Cerrahisi.

### CASE

A 64 year old female patient presented to our clinic with decreased vision in her both eyes. Ophthalmologic examination revealed cataract. Phacoemulsification surgery was planned. The surgery was performed under general anesthesia because of the anxiety of the patient. She underwent cataract extraction with intraocular lens implantation in the right eye. Successful phacoemulsification with IOL implantation was performed. The patient experienced a sudden painless visual loss in her right eye after cataract surgery. There were no complications in the operation like capsular rupture, vitreous prolapse, iris injuries, or other. There was

an excessive coughing and strain detected when the patient was awakened. First day after surgery; the ocular examination revealed that the visual acuity (VA) in the right eye was counting fingers. There was no relative afferent pupillary defect. The anterior segment examinations were bilaterally normal. Fundus examination showed a dense preretinal hemorrhage located under the internal limiting membrane at the posterior pole (Figure 1). There were no other retinal haemorrhages, cotton wool spots, hard exudates and vitreous haemorrhage. Her medical history was unremarkable.

A clinical diagnosis of VR was made. On the first postoperative day she was treated with single intravitreal TPA, intra-

1- Uz. Dr., Lütfiye Nuri Burat Devlet Hastanesi, Göz Hastalıkları Kliniği, İstanbul, Türkiye

2- Uz. Dr., Şişli Hamidiye Etfal Eğitim ve Araştırma Hastanesi, Göz Hastalıkları Kliniği, İstanbul

**Geliş Tarihi - Received:** 27.03.2016

**Kabul Tarihi - Accepted:** 23.05.2017

*Ret-Vit 2018; 27: 90-93*

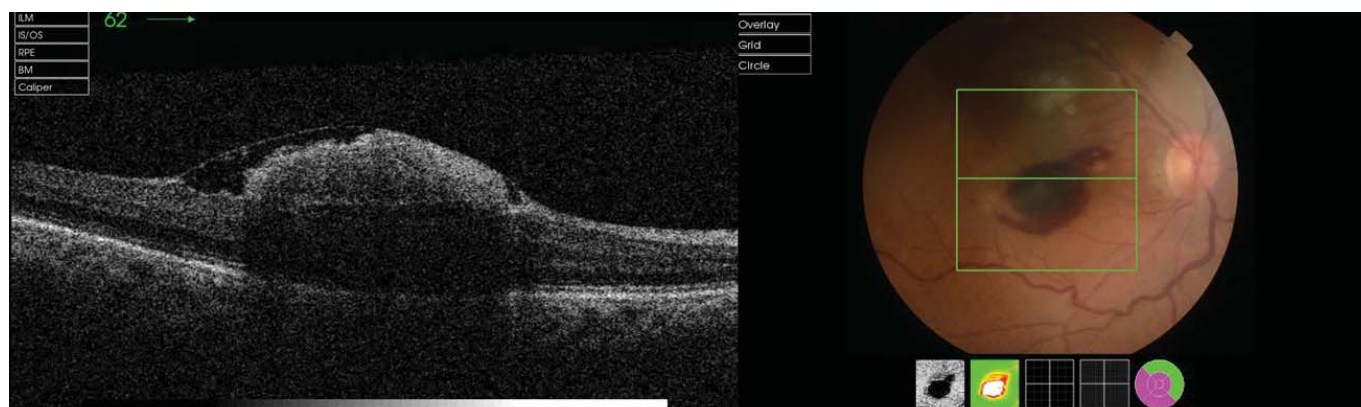
**Yazışma Adresi / Correspondence Address:**

İbrahim Çağrı TÜRKER

Lütfiye Nuri Burat Devlet Hastanesi, Göz Hastalıkları Kliniği, İstanbul, Türkiye

**Phone:** +90 505 748 5831

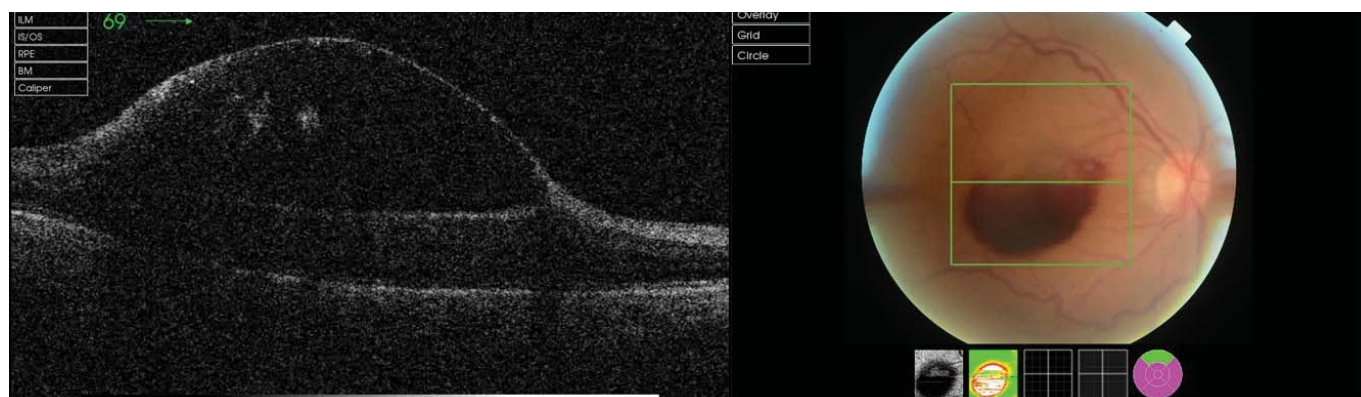
**E-mail:** drcagriturker@hotmail.com



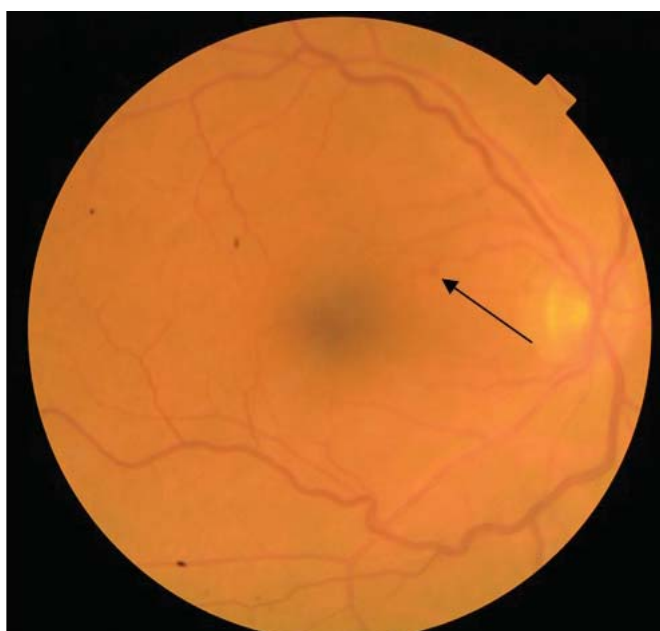**Figure 1.** Preretinal hemorrhage located under the internal limiting membrane

vitreal bevacizumab and 0.2cc SF6 gas, although surgical correction or YAG laser hyaloidotomy was available. With the reason that the patient does not have a systemic hematologic disorder the patient was followed up clinically. Her vision remains poor with slow resolution of her preretinal haemorrhage at the first month after her surgery. (Figure 2) While the bleeding was resorbing we detected a macroaneurysm

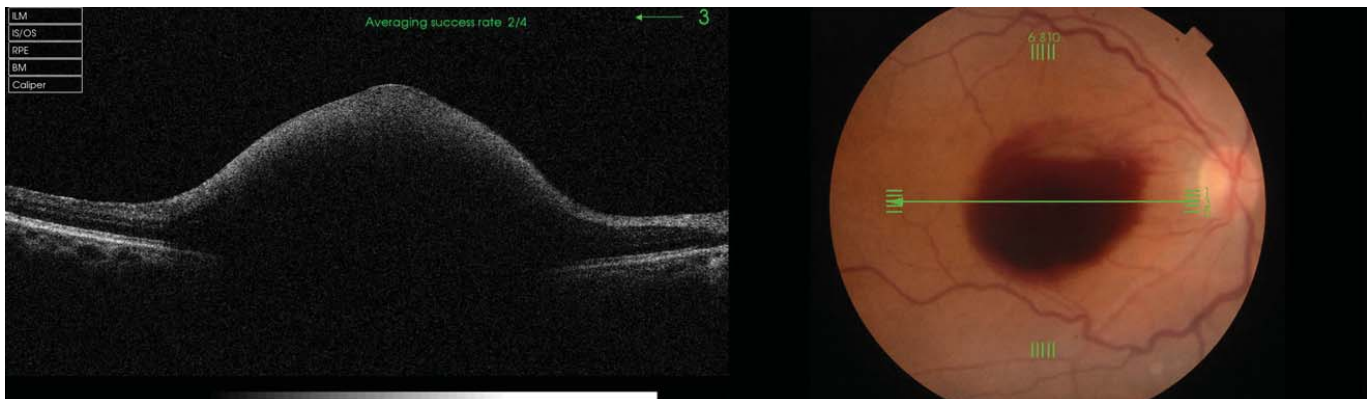
at the superior nasal of the macula. (Figure 3) There was significant resolution of preretinal haemorrhage at 3 months and her best corrected VA was 10/20. Optical coherence tomography showed minimal residual preretinal haemorrhage at the fovea with normal retinal layer (Figure 4). After six months from surgery her vision was 14/20 with resolution of the preretinal hemorrhage. (Figure 5)



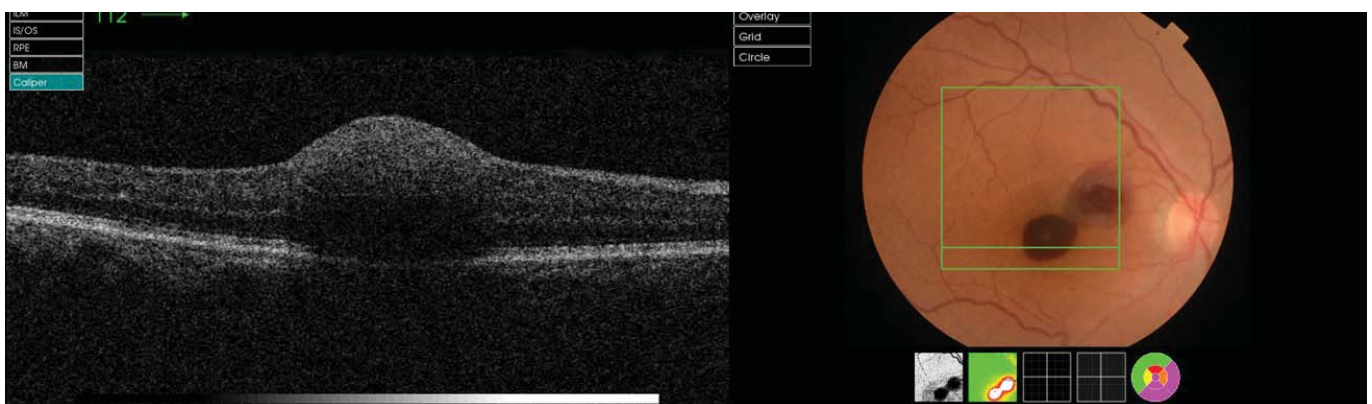
**Figure 2.** Month after initial presentation



**Figure 3.** Macroaneurysm at the superior nasal of the macula



**Figure 4.** Residual preretinal haemorrhage at the fovea with normal retinal layer



**Figure 5.** Resolution of the preretinal hemorrhage

## CONCLUSION

VR is a retinopathy which caused by the bleeding of the premacular area due to sudden rise in intrathoracic or intra-abdominal pressure that may cause a rapid increase in venous pressure in the eye. It is caused by the spontaneous rupture of retinal capillaries. Vascular anomalies are not detected in most valsalva retinopathy cases.<sup>5,6</sup>

The blood is generally localized to the sub-ILM space or the sub-hyaloid space.<sup>7</sup> Small hemorrhages reabsorb spontaneously but larger ones need treatment like laser membranotomy or hyaloidotomy. If the hemorrhage is large and lasts for more than three weeks it must be treated because of the toxic retinal cell damage.<sup>8</sup> Prolonged duration of the blood in the premacular region can lead to permanent and severe visual loss by forming proliferative vitreoretinopathy and preretinal tractional membrane. Hemoglobin and other blood products may also be more harmful than subhyaloid hemorrhage due to the long-term toxic effects on the retina.<sup>1</sup>

Nd:YAG laser treatment in selective patients to disperse and speed up the resolution of the hemorrhages is an option. Subhyaloid hemorrhages can be treated with Nd:YAG, argon laser hyaloidotomy or pars plana vitrectomy.<sup>14</sup> Nd:

YAG laser can be used to evacuate the premacular subhyaloid hemorrhage.<sup>10</sup>

Hyaloidotomy is a treatment option which is less invasive than pars plana vitrectomy (PPV) and therefore it is advantageous because it leads to less complications and because of faster visual recovery.<sup>11</sup> The best response of laser hyaloidotomy is subhyaloid hemorrhages due to the group of valsalva retinopathy.<sup>12</sup> Nd:YAG laser hyaloidotomy for draining the blood into the vitreous cavity combined with intravitreal bevacizumab improves the absorption of the hemorrhages.<sup>15</sup>

Treatment modalities include observation of small and extrafoveal hemorrhages, vitrectomy for refractory and longstanding cases. Surgical treatment may be needed for long-term hemorrhages. Early PPV was recommended for immediate cleaning of the bleeding. The anatomical success rate was % 85 with early PPV and the visual increase was reported as % 54. PPV complications such as intraoperative bleeding (62%), peripheral retinal tear (11%) and macular edema (5%) have been reported. PPV has been suggested to have increased visual acuity and fewer complications when it is done 30 days prior to bleeding without organizing.<sup>13</sup>

**REFERENCES / KAYNAKLAR**

1. Mennel S. Subhyaloidal and macular haemorrhage: localisation and treatment strategies. *British Journal of Ophthalmology*. 2007;91(7):850–852.
2. Russell S. Hemorrhagic detachment of the internal limiting membrane after penetrating ocular injury. *Retina*. 1992;12(4):346–350.
3. Iijima H. Nd:YAG laser photodisruption for preretinal hemorrhage due to retinal macroaneurysm. *Retina*. 1998;18(5):430–434.
4. Meier P. Vitrectomy for premacular hemorrhagic cyst in children and young adults. *Graefe's Archive for Clinical and Experimental Ophthalmology*. 2005;243(8):824–828.
5. Divyalakshmi K. Ocular manifestations of aplastic anaemia following platelet transfusion. *Nitte University Journal of Health Science*. 2014;4(4):104–106.
6. Duane T.D. Valsalva hemorrhagic retinopathy. *Trans Am Ophthalmol Soc*. 1972;70:298–313.
7. Sakamoto S.-I. Double ring sign at the macula in a patient with Valsalva retinopathy. *QJM*. 2014;107:1045–1046.
8. Morris R. Witherspoon C.D., Mester V., Dooner J. Hemorrhagic macular cysts in Terson's syndrome and its implications for macular surgery. *Dev Ophthalmol*. 1997;29:44–54.
9. Bourne RA. Treatment of preretinal Valsalva hemorrhages with neodymium: YAG laser. *Eye*. 1999;13:791–793.
10. Kaynak S. Nd:YAG laser posterior hyaloidotomy in subhyaloid hemorrhage. *Ophthalmic Surg* 1994, 25:474-476.
11. Celebi S. Photodisruptive Nd:YAG laser in the management of premacular subhyaloid hemorrhage. *Eur J Ophthalmol* 2001;11:281-286.
12. Özcan AA. Subhyaloid Hemoraji: Tedavi ve Prognoz. *T Oft Gaz*. 2006;36:430-434.
13. Ramsay RC. Timing of vitrectomy for active proliferative diabetic retinopathy. *Ophthalmology*. 1986; 93:283-289.
14. Özeryürk Y. Subhyaloid kanamada argon lazer posterior hyaloidotomi. *Ret-Vit* 2002;10:227-231.
15. Hua R. Combine intravitreal bevacizumab with Nd: YAG laser hyaloidotomy for valsalva pre-macular haemorrhage and observe the internal limiting membrane changes: aspectralis study. *Int J Ophthalmol*.2013; 6: 242-245