

Anterior Segment Changes in Phakic Eyes After Pars Plana Vitrectomy with Silicone Oil or Gas Tamponade

Pars Plana Vitrektomide Silikon Yağı ve Gaz Tamponat Kullanılmış Gözlerde Ön Segment Değişimi

Erkan ÜNSAL FICO¹, İlkey Kılıç MÜFTÜOĞLU², Kadir ELTUTAR¹

ÖZ

Amaç: Vitreus hemorajisi, yırtıklı retina dekolmanı, proliferatif diabetik retinopati gibi değişik vitreoretinal patolojilerde 23 Gauge pars plana vitrektomi yapılan fakik olgularda ultrasonik biyomikroskop kullanarak ön segment morfolojik değişimini değerlendirmek amaçlanmıştır.

Gereç ve Yöntem: Hastalar internal tamponat kullanımına göre; Grup 1 (Silikon yağı, n=21) ve Grup 2 (C3F8, n=20) olarak 2 gruba ayrıldı. Ön segment parametrelerinden lens kalınlığı (LK), ön kamera derinliği (ÖKD), trabeküler ağ-iris açısı (TİA), sklera kalınlığı (SK), siliyer cisim kalınlığı (SCK), trabeküler meshwork-siliyer proçes mesafesi (T-SPM), iris-siliyer proçes mesafesi (I-SPM) ameliyat öncesi ve postoperatif 1. haftada değerlendirildi.

Bulgular: Grup 2'de; ortalama ÖKD, TİA, SCK, T-SPM ve İ-SPM ameliyat öncesine göre sonrası önemli derecede azalma gösterirken, Grup 1'de önemli derecede değişiklik gözlenmedi. Grup 1'de ortalama LK ve SK operasyon öncesine göre anlamlı artış gösterirken, Grup 2'de anlamlı artış saptanmadı.

Sonuç: Gaz tamponatlar supin pozisyonda, ön segment yapılarında önemli derecede değişikliğe sebep olabilirler.

Anahtar Kelimeler: Ultrasonik biyomikroskop (UBM), vitrektomi, fakik göz, ön segment, siliyer cisim.

ABSTRACT

Purpose: To evaluate the morphological changes on the anterior segment using ultrasonic biomicroscopy imaging (UBM) in phakic patients who underwent 23 Gauge pars plana vitrectomy (PPV) for variety of vitreoretinal pathologies including vitreous hemorrhage, rhegmatogenous retinal detachment, proliferative diabetic retinopathy with either silicone oil or gas (C3F8) tamponade.

Methods: Patients were divided into 2 groups based on the internal tamponade used: group 1 (silicone oil, n=21), group 2 (C3F8, n=20). Several anterior segment variables including lens thickness, scleral thickness (ST), anterior chamber depth (ACD), trabecular meshwork-iris angle (TIA), ciliary body thickness (CBT), trabecular meshwork-ciliary process distance (T-CPD), and iris-ciliary process distance (I-CPD) were assessed before the surgery and at post-operative week 1.

Results: Mean ACD, TIA, CBT, T-CPD, and I-CPD were significantly decreased in group 2 compared to baseline; whereas there was no significant change in these parameters in group 1 after the surgery. Mean LT and ST were significantly increased in group 1 compared to baseline and there was no significant change in these parameters in group 2 after the surgery.

Conclusion: Gas tamponade may cause significant morphological changes in the anterior segment structures in the supine position.

Key Words: Ultrasound biomicroscopy (UBM), vitrectomy, phakic eye, anterior segment, ciliary body.

1- Doç. Dr., İstanbul Eğitim ve Araştırma Hastanesi, Göz Hastalıkları, İstanbul, Türkiye

2- Uz. Dr., İstanbul Eğitim ve Araştırma Hastanesi, Göz Hastalıkları, İstanbul, Türkiye

Geliş Tarihi - Received: 04.11.2017

Kabul Tarihi - Accepted: 06.11.2017

Ret-Vit 2018; 27: 219-225

Yazışma Adresi / Correspondence Address:

Erkan ÜNSAL FICO

İstanbul Eğitim ve Araştırma Hastanesi, Göz Hastalıkları, İstanbul, Türkiye

Phone: +90 505 238 2250

E-mail: erkanunsal@gmail.com

INTRODUCTION

The ultrasonic biomicroscopy imaging (UBM) first became available in the early 1990s, since then, it has been used for imaging and evaluation of the anterior segment structures and anterior chamber angle.¹ This method uses high-frequency ultrasound to produce images with a tissue penetration of approximately 5 mm at lateral and axial resolution, approaching 50 microns and 25 microns of resolution. It enables not only the evaluation of anterior segment structures both quantitatively and qualitatively, but also the recognition of the pathologies of the structures located in the posterior segment, such as the peripheral retina and ciliary body.²

Ultrasound biomicroscopy is an easy imaging technique with a lower cost compared to other imaging techniques such as optical coherence tomography (OCT), it also enhances the visualization of the peripheral retina, pars plana and the vitreous base that may not be seen even by indirect ophthalmoscopy.³⁻⁵ Although OCT has become a routine imaging technique for most of the retina specialists, UBM has the advantage of acquiring cross-sectional images of the ciliary body, lens zonules, and anterior choroid without dilation of the pupils over OCT. By using UBM, it is also possible to detect the complications that occur following pars plana vitrectomy (PPV)⁶⁻¹³ such as shallowing or narrowing of the anterior chamber,^{6,8} and ciliary body detachment leading to hypotonia or glaucoma.

Although there have been some concerns regarding the repeatability of measurements, accuracy, and precision of the acquiring images with UBM,^{14,15} several publications have reported high intra-observer reproducibility with a poor inter-observer reproducibility.¹⁴⁻¹⁸ The main reason for this variability is the quality of the received image. The differences in the selection of the frame to be measured and detection of the location of the scleral spur are the possible causes of low intra-observer reproducibility.

In this study, we aim to show the changes on the anterior segment morphology by UBM during early postoperative period of patients who had PPV with either silicone oil or gas (C3F8) injection for various vitreoretinal pathology.

METHODS

Forty-five eyes of 45 phakic patients that underwent 23 Gauge pars plana vitrectomy for the various of retina diseases between October 2012 and March 2015 at the Ophthalmology Department of the Istanbul Training Research Hospital were evaluated for this prospective study.

The study was conducted in accordance with the tenets of the World Medical Association's Declaration of Helsinki. Approval of the study protocol was obtained from the Ethics Committee of the Istanbul Education and Research Hospital. All patients included in the study were informed about

the details of the surgical procedure and signed an informed consent form.

One or two days before the surgery, all eyes had a complete ophthalmologic examination including best corrected visual acuity, slit-lamp biomicroscopy, intraocular pressure measurement (Goldmann Applanation Tonometry), and dilated fundus examination. The patients' best-corrected vision acuity (BCVA) was measured using the Snellen chart. Patients also were evaluated for the anterior chamber angle with the Goldmann three-mirror lens. Age, gender were recorded, and a detailed medical history including presence of systemic diseases, and drugs used was obtained.

The following situations were excluded: history of prior intraocular surgery; history of ocular trauma history, prior anterior segment laser therapy, history of uveitis or glaucoma; and use of any topical or systemic drug that might affect pupil or accommodation. Patients who required further interventions such as scleral buckling were also excluded. Additionally, patients who showed increase in IOP after the surgery that required further intervention such as laser trabeculoplasty or second surgery to for the removal of silicone oil from anterior chamber were excluded.

Indications for PPV included rhegmatogenous retinal detachments, diabetic retinopathy with persistent vitreous hemorrhage, fibrovascular proliferation, and tractional retinal detachment involving the macula.

All patients underwent 23-gauge pars plana vitrectomy by a single surgeon (EU) using Oertli Faros Machine (Switzerland) and wide-angle viewing system. Twin light was used as a standard aspect of the surgery. After injection of triamcinolone acetonide, the surgeon checked the presence of posterior hyaloid membrane in all cases. In the presence of attached posterior hyaloid membrane, posterior hyaloid was separated using the tip of a vitrectomy probe with vacuum, and after that, it was surgically excised. Three to four rows of 360-degree endolaser photocoagulation were performed prophylactically when needed. In patients with a retinal tear, three to four rows of endolaser photocoagulation were also performed around the retinal tear using an endolaser probe. Silicone oil (1000cs) was used as a long-acting internal tamponade agent; whereas 14% C3F8 was used as short-acting internal tamponade agent. In patients with silicone oil, sclerectomies were sutured with 6/0 vicryl. In cases having gas injection, sclerectomies were sutured only when needed. After the operation, all patients were prescribed 1% Prednisolone acetate (Predforte, Allergan) and Lomefloxacin drops (Okacin, Novartis, Switzerland) in the form of one drop every 2 hours for a month.

Patients were categorized based on the used internal tamponade agent as silicone oil group (group 1) and gas(C3F8) group (group 2).

Ultrasound biomicroscopy examinations were performed by the same surgeon using the same device (SONOMED VuMAX II®) with a 35 mHz transducer. After introducing topical 0.5% proparacaine HCL (Alcaine®, Alcon), a soft silicone eyecup of the appropriate diameter (18, 20, or 22 mm) was inserted between the upper lid and the fornix conjunctiva of the lower lid. Scanning of every patient before and after surgery was performed using the same eyecup. In order to prevent corneal contact, the focus distance of the transducer was set at 12 mm. For the purpose of immersion, the eyecup was filled with an adequate amount of sterile physiological saline. These examinations were performed before (24–48 hours) surgery and at 1 week (5–10 days) (7±3 days) after surgery using the same meridian (temporal quadrant). In order to avoid the side effects of drugs used such as: paralysis of accommodation after atropine, cyclopentolate or tropicamide use, or mydriasis after phenylephrine use, all UBM measurements were performed after the effects of these drugs wore off. Scanning was performed when the patient was in the supine position. In order to use natural pupil dilation, scanning was performed in a room with low illumination. Accommodation was kept constant by asking the patient to stare at a red target on the ceiling.

The axial images of the anterior chamber and the radial section of the angle images from the temporal quadrant were scanned. In order to obtain an ideal image and to have consistent pre- and post-operative measurements, the researchers took care to have stable scanned axial images of the anterior segment (theoretically, aligned with the central horizontal line and symmetrical to it) as well as stable images in the vertical alignment (ideally, the cornea, lens, and anterior and posterior capsules were balanced with the referenced vertical central line). When taking radial cross-sectional images of the angle, the observer made sure that the probe was perpendicular to the limbus of the scanned quadrant and chose the images with the best reflectivity of the iris.¹⁹ In terms of accuracy and ease, the localization of the scleral spur was given close attention in order to choose the images that best showed the ciliary body, the iris, and the reflection of the interface between the ciliary body and the sclera.

The anterior chamber depth (ACD) and lens thickness (LT) were measured from the axial images of the anterior segment using the methods previously recommended by Pavlin et al. and the scales provided in the user's guide for the device.^{20,21}

1. Axial ACD measurement: detected by measuring the distance between the posterior surface of the central cornea and the anterior surface of the lens in the midline of the pupil (Figure 1A).

2. LT: the distance between the anterior and the posterior capsule of the lens (Figure 1A) and then from the radial cross-section images of the temporal quadrant.

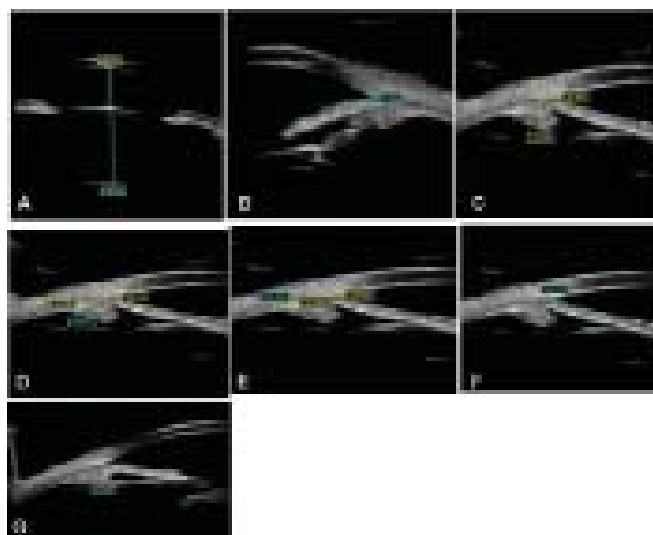


Figure 1. Views of axial images of the anterior chamber and radial section of the angle images from the temporal quadrant.

A; An UBM image of Anterior Chamber Depth (ACT) and Lens Thickness (LT), **B;** An UBM image of Trabecular Meshwork-Iris Angle (TIA), **C;** An UBM image of Ciliary Body Thickness 1, **D;** An UBM image of Ciliary Body Thickness 2, **E;** An UBM image of Ciliary Body Thickness 3, **F;** Trabecular-Ciliary Process Distance (T-CPD), **G;** An UBM image of Iris-Ciliary Process Distance (I-CPD).

3. Trabecular meshwork-iris angle (TIA): measured at the apex of the iris recess with the arms of the angle passing through a point on the trabecular meshwork 500 µm from the scleral spur and a point on the iris perpendicularly opposite (Figure 1B).

4. Ciliary body thickness (CBT) was measured in three regions:

a) the distance 1 mm from the scleral spur (CBT 1), detected by measuring the distance between the posterior surface of the sclera and ciliary body to the border perpendicular to the surface of the sclera (Figure 1C);

b) the distance 2 mm from the scleral spur (CBT 2), detected by measuring the distance between the posterior surface of the sclera and ciliary body to the border perpendicular to the surface of the sclera (Figure 1D);

c) the distance 3 mm from the scleral spur (CBT 3), detected by measuring the distance between the posterior surface of the sclera and ciliary body to the border perpendicular to the surface of the sclera (Figure 1E);

5. Scleral thickness (ST): the distance of the episcleral surface measured perpendicularly to the scleral spur;

6. Trabecular meshwork-ciliary process distance (T-CPD): measured as a line extending from a point 500 µm anterior to the scleral spur along the corneal endothelium and dropped

perpendicularly through the iris to the most anterior ciliary process seen during scanning in that meridian (Figure 1F).

7. Iris–ciliary process distance (I-CPD): the distance measured between the iris pigment epithelium and the ciliary processes (Figure 1G).

The preoperative and postoperative parameters were compared using SPSS 15.00 for Windows Software (SPSS Inc., Chicago, Illinois, USA) For distribution analysis, the Kolmogorov–Smirnov test was used. Since data was not normally disturbed, Mann-Whitney test or Wilcoxon signed test was used. Statistical power analysis was made to avoid type 2 error using on line software (<https://www.stat.ubc.ca/~rolin/stats/ssize/n2.html>). P- values of less than 0.05 were accepted as being statistically significant.

RESULTS

Forty-five eyes underwent PPV with either SO or gas tamponade. Of 45 eyes, 4 eyes (3 eyes with gas tamponade, 1 eye with silicon oil) were excluded due to having acute IOP increase that required further surgical intervention after PPV. Therefore, the study included a total of 41 phakic eyes of 41 patients that had planned PPV with silicone oil (n=21, Group 1) or gas tamponade (C3F8) (n=20, Group 2). The distribution of gender was similar (female/male: 1.15). The mean age of the patients was 63.56±10.78 (range: 40-85, year). Gas tamponade group was significantly older than SO group (66.3±10.6 years versus 58.1±11.9 years, p<0.001). There was no statistically significant difference in the gender (p=0.249) or laterality distribution between the 2 groups (p=0.246).

The indications for the surgery are shown in Table 1. Comparisons of the pre-operative and post-operative parameters of the anterior segment are shown in Table 2. In the measurements, the amount of intraocular gas was between 40-80%. In group 1, the mean LT, ST and IOP significantly increased following the surgery (p=0.014, p=0.035, p<0.001, respectively). In group 2, the mean ACD, TIA, CBT1, CBT2, CBT3, T-CPD, and I-CPD significantly decreased (p<0.001, p=0.042, p<0.001, p=0.002, p=0.038, p<0.001, and p<0.001, respectively) after the surgery.

The comparison of the mean change (=post-pre) in anatomical parameters and the IOP between 2 groups are summarized in table 3. There was a significant difference in the mean change of ACD, CBT1, CBT-3, T-CPD, I-CPD between 2 groups, group 2 showed less decrease in these parameters compared to group 1 (Table 3). The mean change in IOP was statistically higher in group 1 compared to group 2 (5.33±1.2 versus 2.2±1.13, p=0.05), (Figure 2).

When looking at the correlation between preoperative and postoperative IOP and measured parameters, no significant correlation was found between these parameters (p >0.005, for all parameters).

	Group 1 (n=21)	Group 2 (n=20)	Total
PDR	4	6	10
RRD	16	4	20
IVH	1	10	11

PDR: Proliferative diabetic retinopathy; **RRD:** Rhegmatogenous retinal detachment; **IVH:** Intravitreal hemorrhage.

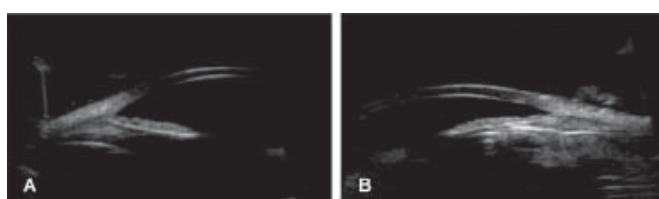
	Group 1 (n=21) (SILICONE OIL GROUP)			Group 2 (n=20) (GAS-C3F8 GROUP)		
	Pre	Post	P*	Pre	Post	P*
ACD, Mean±SD (mm)	2.68±0.46	2.69±0.54	0.557	2.49±0.13	2.21±0.27	0.000
LT, Mean±SD (mm)	4.07±0.56	4.10±0.55	0.012	4.30±0.45	4.29±0.42	0.314
TIA (°), Mean±SD	31.04±1.02	33.00±5.47	0.184	28.2±5.74	25.4±2.70	0.032
CBT 1, Mean±SD (mm)	1.02±0.14	1.00±0.08	0.478	1.07±0.12	0.84±0.89	0.000
CBT 2, Mean±SD (mm)	0.61±0.08	0.59±0.10	0.118	0.62±0.22	0.44±0.06	0.001
CBT 3, Mean±SD (mm)	0.34±0.07	0.36±0.11	0.665	0.34±0.13	0.28±0.04	0.035
ST, Mean±SD (mm)	1.00±0.04	1.07±0.13	0.025	1.01±0.10	1.03±0.14	0.607
T-CPD, Mean±SD (mm)	1.25±0.04	1.25±0.08	0.982	1.27±0.11	1.11±0.15	0.001
I-CPD, Mean±SD (mm)	0.89±0.04	0.88±0.05	0.679	0.87±0.09	0.57±0.17	0.000
IOP, Mean±SD (Range) mmHg	11.66±2.45 (8.5-17)	16.83±3.18 (10-22)	0.000	13.85±3.02 (8-19)	15.95±3.18 (10-21)	0.075

ACD: Anterior chamber depth; **LT:** Lens thickness; **TIA:** Trabecular meshwork-iris angle; **CBT 1,2,3:** Ciliary body thickness 1, 2 and 3 mm; **ST:** Sclera thickness; **T-CPD:** Trabecular meshwork-ciliary process distance; **I-CPD:** Iris-ciliary process distance; **SD,** standard deviation; *paired t test

Table 3. The mean change in the parameters in silicone filled eyes (group 1) and gas filled eyes (group 2)

	MEAN CHANGE FROM PREOPERATIVE VISIT		p
	Group 1 (n=21)	Group 2 (n=20)	
ACD, Mean±SD (mm)	0.11± 0.019	-0.25± 0.04	<0.001
LT, Mean±SD (mm)	0.03± 0.13	-0.12± 0.09	0.075
TIA (°), Mean±SD (°)	1.95± 1.41	-2.8± 1.2	0.078
CBT 1, Mean±SD (mm)	-0.02± 0.02	-0.19± 0.05	0.005
CBT 2, Mean±SD (mm)	-0.07± 0.04	-0.14± 0.05	0.162
CBT 3, Mean±SD (mm)	0.05± 0.01	-0.06± 0.02	0.004
ST, Mean±SD (mm)	0.07± 0.03	0.01± 0.02	0.152
T-CPD, Mean±SD (mm)	0.0± 0.021	-0.16± 0.42	0.001
I-CPD, Mean±SD (mm)	-0.005± 0.01	-0.33± 0.05	<0.001
IOP, Mean±SD, Range) (mmHg)	5.33± 1.2	2.2± 1.13	0.05

ACD: Anterior chamber depth; **LT:** Lens thickness; **TIA:** Trabecular meshwork-iris angle; **CBT 1,2,3:** Ciliary body thickness 1, 2 and 3 mm; **ST:** Sclera thickness; **T-CPD:** Trabecular meshwork-ciliary process distance; **I-CPD:** Iris-ciliary process distance; **IT-1,2,3:** Iris thickness 1,2,3; **SD,** standard deviation; Independent – Samples T Test

**Figure 2.** Views of radial section of the angle images from the temporal quadrant.

A; UBM image of an eye with silicone oil used as internal tamponade agent, **B;** UBM image of an eye with gas (C3F8) used as an internal tamponade agent.

DISCUSSION

In this study, we measured several anterior segment parameters using UBM in patients who underwent planned pars plana vitrectomy for various vitreoretinal pathologies with either silicone oil or gas tamponade. We found that eyes with silicone oil tamponade showed significant increase in the mean lens thickness and scleral thickness at post-operative week. However, gas filled eyes demonstrated significant decrease in several parameters including mean anterior chamber depth, trabecular meshwork-iris angle, ciliary body thickness 1-2-3, trabecular meshwork-ciliary process distance. These results may suggest that gas causes more pressure on the ciliary body in the supine position compared to silicone oil tamponade. We also showed that the mean IOP change was significantly higher in the silicon filled eyes. Since the surface tension of the gas is higher than that of silicone oil, the ciliary body may expose to less pressure resulting in lower intraocular pressure. Silicone oil also leads less angle

narrowing compared to gas due to fact of less compression to the angle.

In contrast to our study, in a small number of patients that underwent vitrectomy without any internal tamponade, Marigo et al.,²² were not able to show any significant difference in the morphological anterior segment parameters at postoperative 1 month. However, the use of internal tamponade and the difference in the timing for acquiring UBM images do not allow us to compare two studies.

Çalik et al.,²³ evaluated anterior segment changes with a Pentacam Scheimpflug camera pre- and post-operatively in patients who underwent pars plana vitrectomy and silicone oil injection. They reported that there was no change in the mean trabecular meshwork-iris angle of PPV patients with or without an internal tamponade of silicone. Similarly, in the present study, there is no change in the mean trabecular meshwork-iris angle values of PPV patients with an internal tamponade of silicone. Different than that study, we also assessed several anterior segment parameters.

As a different study, our group evaluated the morphological changes of the anterior segment using UBM imaging in pseudophakic patients who underwent PPV with silicone oil or gas (C3F8) internal tamponade agent injection.²⁴ In both studies, patients with gas tamponade showed significant decrease in the anterior chamber depth, ciliary body thickness, and T-CPD and I-CPD, compared to preoperative status. Also, patients with silicon oil tamponade demonstrated increase in the mean scleral thickness and intraocular pressure after the surgery. Different than pseudophakic patients undergoing vitrectomy with gas tamponade, in whom

TIA did not show statistically change, phakic eyes with gas tamponade exhibited a significant decrease in the mean TIA after the surgery. This may be related to the spherical structure of posterior surface of lens inside the eye.²⁴

Kim et al.,²⁵ evaluated ciliary body thickness using UBM preoperatively and postoperatively in patients who underwent PPV for diffusing DME. They found that the mean preoperative ciliary body thickness was thicker in DME patients compared to healthy subjects, furthermore, the ciliary body thickness significantly decreased after the surgery in DME eyes and this decrease was correlated with the decrease of the ciliary body edema. In the present study, the decrease in ciliary body thickness in patients with gas tamponade, unlike the lack of change in those with silicone tamponade, may be a result of gases creating pressure on the ciliary body due to of surface tension rather than actual reduction of the ciliary body edema.

Neudorfer et al.,¹¹ evaluated the short-term changes in the anterior segment morphology following vitrectomy with or without gas tamponade using UBM. They found a significant decrease in the anterior chamber depth in eyes with gas tamponade, but not in those that did not have gas tamponade. Similarly, the present study found a significant decrease in the anterior chamber depth in eyes with gas tamponade (Group 2). In Neudorfer's study,¹¹ no correlation was found between the intraocular pressure and the mean anterior chamber depth. In this study, we were not able to show any correlation between intraocular pressure and anterior segment parameters, which may be related with excluding eyes that required further intervention due to increase in intraocular pressure after the surgery.

We found that the mean scleral thickness was statistically significantly higher in silicone oil group compared to gas group, likely because in patients treated with silicone oil, all the access sites were closed by scleral sutures, which may have resulted in episcleral edema, while the access sites of patients treated by gas (group 2) were sutured only when needed.

There are some limitations of the study including small number of patients, not evaluating the long term changes in the anterior segment morphology, having a heterogeneous study population and not comparing the results with different imaging modality such as OCT. Additionally, we excluded eyes that showed acute increase in intraocular pressure that required further intervention which may not have allowed us to evaluate the sole effect of the surgery with tamponade. It would be interesting to see the anterior segment changes in these eyes. Although OCT is a non-invasive technique to

provide high resolution images of the retina, we believe that UBM still has a value in the clinical practice particularly visualizing the ciliary body and peripheral retina. Different than the other studies, we analyzed several parameters in 2 different groups at preoperatively and postoperatively and showed the above-mentioned changes on the anterior segment morphology.

Although many studies showed some changes in some anterior segment after vitrectomy and scleral buckling,^{6-9, 26-28} we evaluated several parameters after the surgery with two different tamponade. We believe that knowledge of the effect of vitrectomy on the anterior segment morphology would enable surgeons to better understand the post-operative status of the patients with tamponade. In conclusion, gases do cause more morphological changes in the anterior segment structures, when patients are treated in the supine position (Figure 3).

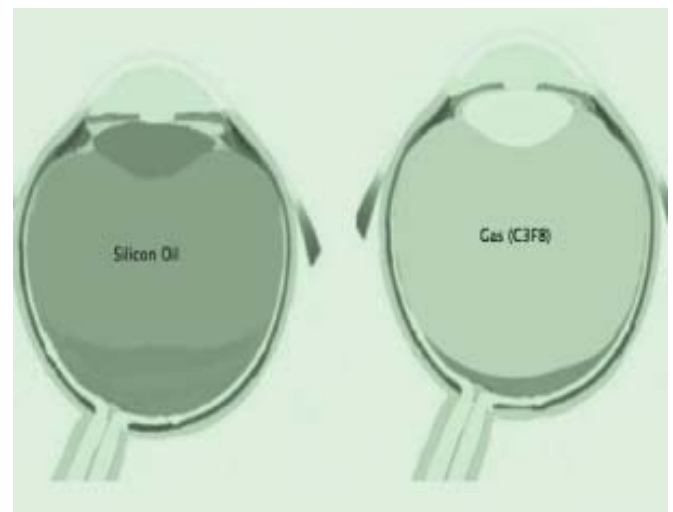


Figure 3. Views of demonstrative image

left: silicon oil internal tamponade; **right:** gas (C3F8) internal tamponade.

Acknowledgments: Financial Support: No financial support was received for this submission.

Conflict of Interest Statement: None of the authors has conflict of interest with this submission.

Author Contributions; UE: Research concept and design. UE: Collection of data. UE: Data analysis and interpretation. UE: made the figures. UE: made the table. UE: Writing the manuscript. UE: Critical revision and Final approval of the manuscript. UE, KMI, EK: supervised the study.

REFERENCES / KAYNAKLAR

1. Pavlin CJ, Sherar MD, Foster FS. Subsurface ultrasound microscopic imaging of the intact eye. *Ophthalmology*. 1990;97:244-50.
2. Friedman DS, He M. Anterior chamber angle assesment techniques. *SurvOphthalmol*. 2008;53:250-73.
3. Kayıkçıoğlu ÖR, Şahin BÖ, Emre S, Bilgin S. Transskleral diod lazer siklofotokoagülasyon sonrası siliyer cisim kalınlığının ultrason biyomikroskop ile değerlendirilmesi. *Glokom-Katarakt*. 2016;11(1):44-47.
4. Ünsal E, Eltutar K, Alıkma MS, Kızılay O, Karini B. Fakik gözlerde, internal tamponat kullanmadan yapılan vitrektomi ile, ön segment morfolojisinin değişimini, ultrasonik biyomikroskopu kullanarak değerlendirilmesi. *Istanbul Med J*. 2016; 17: 14-19.
5. Karaca S, Talay E, Türe G. Geç kapsüler distansiyon tanılı olgularda Nd:YAG kapsülotomi sonrası UBM bulguları ve göz içi basınç değişikliklerinin karşılaştırılması. *Glokom-Katarakt*. 2017;12(3):187-91.
6. Hikichi T, Ohnishi M, Hasegawa T. Transient shallow anterior chamber induced by supraciliary fluid after vitreous surgery. *Am J Ophthalmol*. 1997;124:696-8.
7. Genovesi-Ebert FI, Rizzo S, Chiellini S, Gabbriellini G, Laddaga F, Nardi M. Ultrasound biomicroscopy in the assessment of secondary glaucoma after vitreoretinal surgery and silicone oil injection. *Ophthalmologica*. 1998;212 Suppl 1:4-5.
8. Minamoto A, Nakano KE, Tanimoto S, Mizote H, Takeda Y. Ultrasound biomicroscopy in the diagnosis of persistent hypotony after vitrectomy. *Am J Ophthalmol*. 1997;123:711-3.
9. Liu W, Wu Q, Huang S, Tang S. Ultrasound biomicroscopic features of anterior proliferative vitreoretinopathy. *Retina*. 1999;19:204-12.
10. Chen WL, Yang CM, Chen YF, Yang CH, Shau WY, Huang JS, Ho TC, Chen MS, Hung PT. Ciliary detachment after pars planavitrectomy: An ultrasound biomicroscopic study. *Retina*. 2002;22:53-8.
11. Neudorfer M, Oren N, Barak A. High-frequency ultrasound biomicroscopy of the anterior segment morphometry before and immediately after pars plana vitrectomy. *Eur J Ophthalmol*. 2011;21:173-8.
12. Park SP, Ahn JK, Lee GH. Morphologic changes in the anterior segment after phacovitrectomy for proliferative diabetic retinopathy. *J Cataract Refract Surg*. 2009;35:868-73.
13. Wu N, Zhang H. Ultrasound biomicroscopy of hyperpressurized eyes following pars plana vitrectomy. *Exp Ther Med*. 2013;6:769-72.
14. Urbak SF, Pedersen JK, Thorsen TT. Ultrasound biomicroscopy. II. Intraobserver and interobserver reproducibility of measurements. *ActaOphthalmol Scand*. 1998;76:546-9.
15. Urbak SF. Ultrasound biomicroscopy III. Accuracy and agreement of the measurements. *ActaOphthalmol Scand*. 1999; 77:293-7.
16. Spaeth GL, Azuara-Blanco A, AraujoSV, Augsburger JJ. Intraobserver and interobserver agreement in evaluating the anterior chamber angle configuration by ultrasound biomicroscopy. *J Glaucoma* 1997;6:13-7.
17. Lin Z, Mou da P, Liang YB, Li SZ, Zhang R, Fan SJ, Wang NL, Thomas R. Reproducibility of anterior chamber angle measurement using the Tongren ultrasound biomicroscopy analysis system. *J Glaucoma*. 2014;23:61-8.
18. Chen L, Xiong K, Wu J. [Comparison of anterior chamber depth measured by anterior segment optical coherence tomography and ultrasound biomicroscopy: A meta-analysis]. *Nan Fang Yi Ke Da Xue Xue Bao*. 2013;33:1533-7.
19. Ishikawa H, Liebmann JM, Ritch R. Quantitative assessment of the anterior segment using ultrasound biomicroscopy. *Curropinophthalmol*. 2000;11:133-9.
20. Pavlin CJ, Harasiewicz K, Sherar MD, Foster FS. Clinical use of ultrasound biomicroscopy. *Ophthalmology*.1991;98:287-95.
21. Pavlin CJ, Harasiewicz K, Foster FS. Ultrasound biomicroscopy of anterior segment structures in normal and glaucomatous eyes. *Am J Ophthalmol*. 1992; 113...:381-9.
- 22- Marigo F A, Zisman M, Nehemy M B, Marigo P.V.B. Ultrasound biomicroscopy in the comparison of the anterior segment morphometry before and after pars planavitrectomy. *Arq Bras Oftalmol*. 2006;69:919-22.
23. Çalik B, Öztürk M, Serdarogullari H, Elçioglu M. Evaluation of anterior segment parameters using pentacam in silicone oil-injected patients after pars plana vitrectomy. *Indian J Ophthalmol*. 2013;61:621-5.
- 24- Ünsal E, Eltutar K, Karini B, Kızılay O. Assessment of anterior segment changes in pseudophakic eyes, using ultrasonic biomicroscopic imaging, after pars plana vitrectomy with silicone oil or gas aamponade. *J Ophthalmol*. 2016;2016:8303792. doi: 10.1155/2016/8303792. Epub 2016 May 19.
25. Kim C, Yu HG. Changes in ciliary body thickness in patients with diabetic macular edema after vitrectomy. *Retina*. 2012;32:1316-23.
26. Pavlin CJ, Rutnin SS, Devenyi R, Wand M, Foster FS. Supraciliary effusions and ciliary body thickening after scleral buckling procedures. *Ophthalmology*. 1997;104:433-8.
27. Maruyama Y, Yuuki T, Kimura Y, Kishi S, Shimizu K. Ciliary detachment after retinal detachment surgery. *Retina*. 1997;17:7-11.
28. Kawahara S, Nagai Y, Kawakami E, Ida RY, Takeuchi M, Uyama M. Ciliochoroidal Detachment Following Scleral Buckling Surgery for Rhegmatogenous Retinal Detachment. *Jpn J Ophthalmol*. 2000;44:692-3

Ethical approval: All procedures performed in studies involving human participants were in accordance with the ethical standards of the institutional and/or national research committee and with the 1964 Helsinki declaration and its later amendments or comparable ethical standards.

Informed consent: Informed consent was obtained from all individual participants included in the study.