

# Retina Dekolmanı Cerrahisi Sonrası Spontan Kapanıp Rekürren Açılan Maküla Deliği

## Recurrent Opening of a Spontaneously Closed Macular Hole after Retinal Detachment Surgery

Berna ÖZKAN<sup>1</sup>, Levent KARABAŞ<sup>2</sup>

### ÖZ

Vitreoretinal cerrahi sonrası maküla deliği oluşumu daha önceki yayınlarda bildirilmiştir. Bu delikler takipler sırasında kapanabilseler de sonra tekrar açılabilirler. Hastamızda retina dekolmanı ameliyatı sonrası maküla deliği geliştiği gözlemlendi. Takiplerinde spontan olarak kapanan maküla deliği, kapandıktan 2 hafta sonra tekrar açıldı. Retina dekolmanı ameliyatında tamponad olarak kullanılan silikon yağı'nın alımı sırasında maküla deliği de ILM flebi kullanılarak tamir edildi. Bu olgu sunumumuzda, hastamızın bu süreçteki klinik özelliklerini ve tedavi yöntemimizi bildirmeyi amaçladık.

**Anahtar Kelimeler:** Maküla deliği, retina dekolmanı, vitreoretinal cerrahi.

### ABSTRACT

Macular hole formation after vitreoretinal surgery has been reported in previous publications. Although spontaneous closure may occur in such macular holes, they may also re-open during follow-up. We observed a macular hole formation in a patient who underwent vitreoretinal surgery for retinal detachment. The hole was closed spontaneously; however, it was reopened after 2 weeks. The macular hole was repaired with an ILM flap in the same session with silicone oil removal. In this case report, we aimed to present the clinical characteristics and treatment method in our patient during this process.

**Key Words:** Macular hole, retinal detachment, vitreoretinal surgery.

### INTRODUCTION

A macular hole is a full-thickness defect of retina occurring at fovea. Although majority of macular holes are idiopathic, it may develop due to other causes such as trauma or myopia<sup>1-5</sup>. In recent years, macular holes developing after retina surgery have also been reported<sup>6-9</sup>. Currently, there is no consensus on management of such macular holes.

Here, we aimed to present clinical findings, treatment process and follow-up of a macular hole developed after vitreoretinal surgery which was closed spontaneously but reopened shortly after.

### CASE

A 58-years old man presented to our clinic with decreased visual acuity in right eye. The visual acuity was approximately 0.1. The intraocular pressure was measured as 12 mmHg. Pseudophakia was detected in anterior segment examination with open anterior capsule. Anterior segment examination was considered as normal other than above-mentioned findings. Retinal detachment involving all quadrants was detected in funduscopy. There was a horseshoe tear in inferior nasal quadrant at 5 O'clock and lattice degeneration in superior nasal quadrant. There was also pseudophakia in left eye; however, anterior and posterior segment examination findings were normal with intact vision.

1- Doç. Dr., Acıbadem Üniversitesi, Tıp Fakültesi, Göz Hastalıkları Anabilim Dalı, İstanbul, Türkiye

2- Prof. Dr., Kocaeli Üniversitesi, Tıp Fakültesi, Göz Hastalıkları Anabilim Dalı, Kocaeli, Türkiye

**Geliş Tarihi - Received:** 06.12.2017

**Kabul Tarihi - Accepted:** 12.02.2018

*Ret-Vit 2019; 29: 81-84*

**Yazışma Adresi / Correspondence Address:**

Berna ÖZKAN

Acıbadem Üniversitesi, Tıp Fakültesi, Göz Hastalıkları Anabilim Dalı, İstanbul, Türkiye

**Phone:** +90 532 549 3952

**E-mail:** drbernaozkan@gmail.com

Pars plana vitrectomy was planned due to retinal detachment in right eye. For surgery, three 23 G trocar were inserted at 5, 2 and 10 O'clock positions. An infusion cannula attached to balanced salt solution was connected to trocar at 5 O'clock position. Then, posterior hyaloid membrane was dissected and cleaned following vitrectomy. The macular reattachment was achieved by instillation of liquid perfluorocarbon LPFC (PFCL, Micromed, Rome, Italy). Peripheral vitreous was completely cleansed and flap for horseshoe tear was harvested by excising vitreous probe. The LPFC was filled until tear level and liquid-air exchange was performed. The fluid in vitreous space and under retina was completely aspirated and retinal reattachment was achieved. Laser photocoagulation was performed around tear and 360° prophylactic laser application was performed in peripheral retina. The LPFLC was completely removed under air and silicone oil (PDMS, Micromed, Rome, Italy) was instilled into vitreous space.

In the post-operative control visit on week 2, a macular hole was detected. The hole was visualized by SD OCT (Cirrus OCT with Angioplex Metrix, Carl Zeiss Meditec, Inc, Dublin, USA) (Figure 1). Follow-up was recommended to the patient. In the control visit after one week, it was observed that macular hole was completely closed (Figure 2A) and a control visit was scheduled after 2 weeks. In that control visit, it was seen that macular hole was reopened (Figure 2B); thus, it was planned to repair macular hole during removal of silicon oil. The patient was followed over 3 weeks until repair.

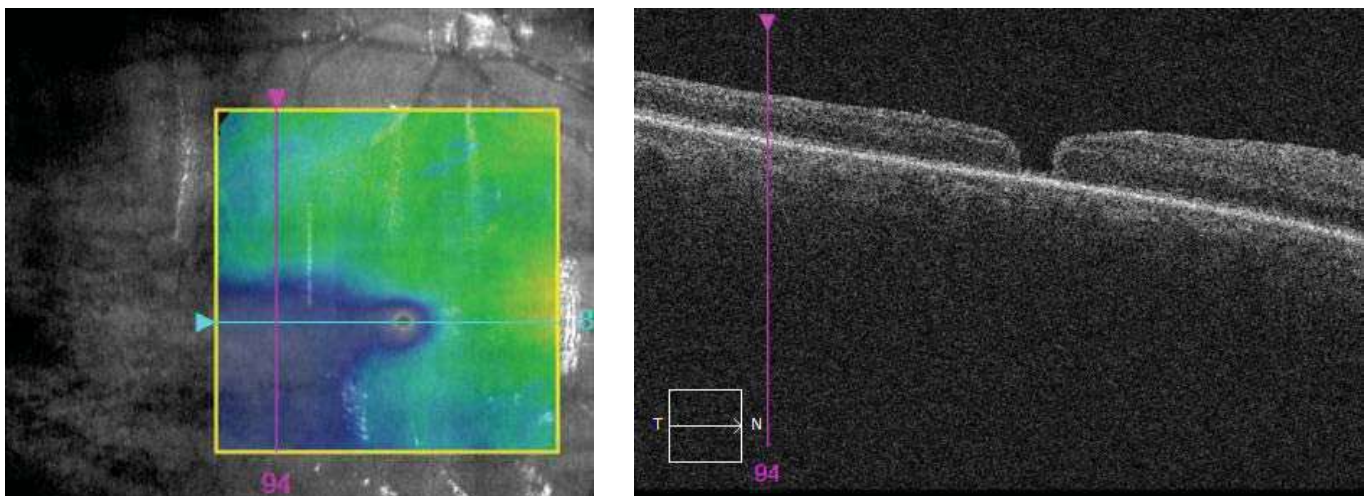
During surgery, all removable silicone particles were cleaned following liquid-air exchange. When silicone highlight disappeared over macula, epiretinal membrane (ERM) was observed. Membrane blue-DUAL (Membrane blue-DUAL, DORC), a combined ophthalmic solution containing 0.15% Trypan blue, 0.025% Brilliant blue G and 4% polyethylene glycol, was administered over macula.

After awaiting 20 seconds, the dye was aspirated and DUAL epiretinal membrane was cleaned. Then, membrane blue was re-administered and internal limiting membrane (ILM) was stained by awaiting 20 seconds. After aspiration of dye, LPLC was given over macula. The ILM was peeled from upper quadrant of macula under LPLC and an ILM flap was created. The macular hole was closed by using ILM flap. All fluid was aspirated over LPLC by liquid-air exchange. Then, LPLC was aspirated by taking attention to not displace flap. One of the trocars was removed and impermeableness was tested. To infusion cannula site, 14% C3F8 gas connection was attached. Air was aspirated from free trocar by back-flush while gas was insufflating slowly. Globe pressure was checked and trocars were removed. Impermeableness was tested at wound sites.

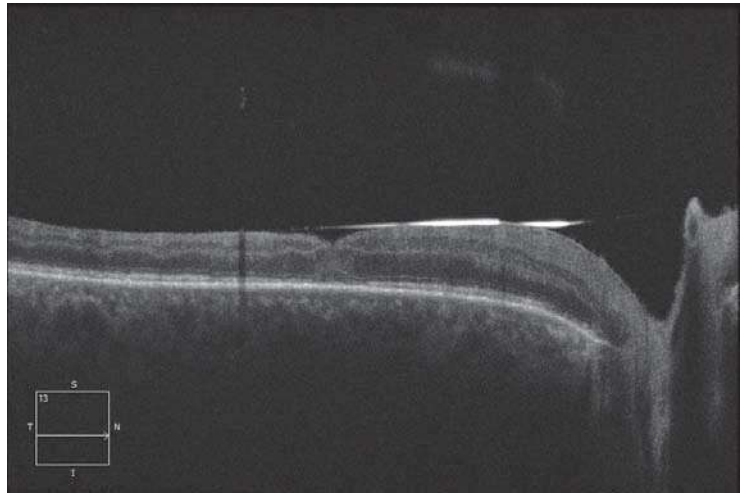

On post-operative month 4, it was seen that visual acuity was improved to 0.4 and macular hole was closed. It was also observed that retinal attachment was achieved (Figure 2C).

## DISCUSSION

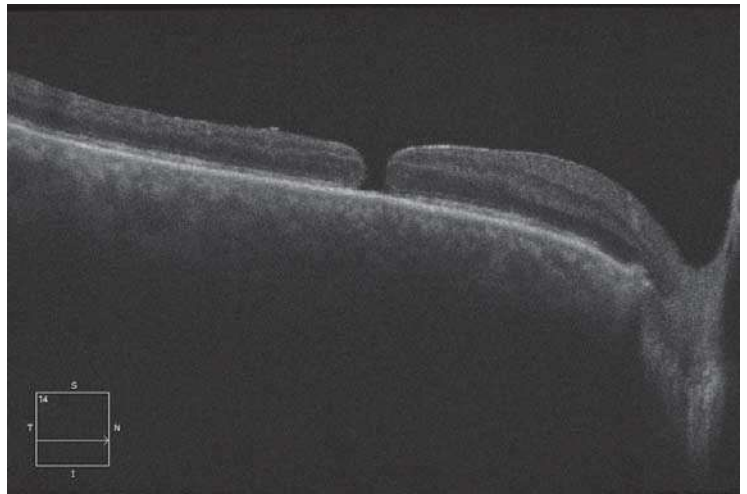

Multiple mechanisms are being implied in the formation of macular holes. Anteroposterior and tangential tractions occurring vitreoretinal surface are the most important one among these mechanisms<sup>1</sup>. In studies using SD-OCT, it was shown that anteroposterior traction occurring after incomplete pathological posterior vitreous detachment causes macular hole. Tangential traction becomes important in later process, resulting enlargement of hole. It is thought that stiffening and shrinking of ILM is primary reason for enlargement of macular hole<sup>10</sup>. Once macular hole is developed, local inflammatory reaction activates trans-Müller cells. These cells differentiate to fibroblast and myofibroblast and proliferate over ILM, resulting in novel collagen type I, III and V. As such, they form an epiretinal membrane covering ILM, leading macular hole even if vitreous traction is abolished.



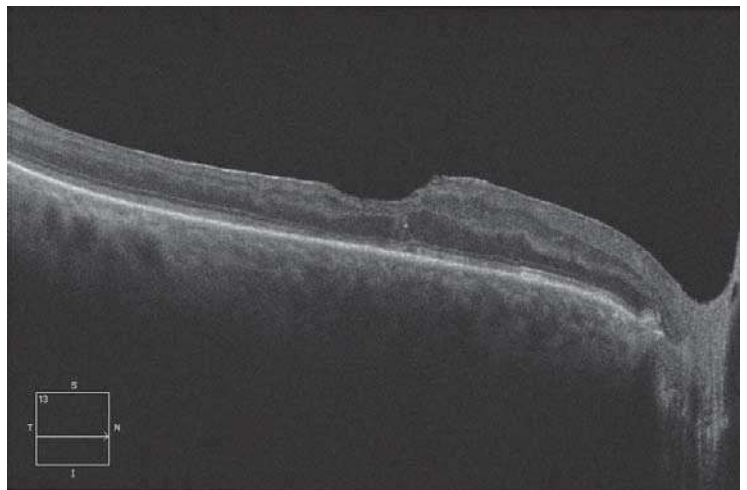
**Picture 1:** Macular hole can be seen on SD OCT image obtained 2 weeks after retinal detachment surgery.



**Figure 2: 2A.** Macular hole developed following detachment surgery was closed after one week



**Figure 2: 2B.** Re-opening of hole was observed in the control visit after 2 weeks



**Figure 2: 2C.** Macula hole was repaired via ILM flap by removing silicone oil on postoperative month 2. SD OCT images 4 months after silicone removal

Macular hole development was previously described<sup>6-9</sup>. It is thought that, as similar to idiopathic macular hole formation, anteroposterior traction at fovea occurs due to posterior hyaloid detachment created during surgery, leading full-

thickness macular hole<sup>8</sup>. Zhang et al. reported macular hole formation in 3 patients, which developed following vitrectomy and spontaneously closed during follow-up. In that report, it was suggested that macular hole diameter was  $<200 \mu\text{m}$  and associated with epiretinal membrane.

Authors have proposed that small macular holes can be closed even in the presence of mild ERM<sup>9</sup>.

It has been proposed that intravitreal gas given at the end of macular surgery induces glial cell proliferation and closes macular hole by contracting retina tissue in centripetal manner<sup>12</sup>. In the inverted flap technique used in large and recurrent macular hole, flap Müller cell fragments stimulates glial cell proliferation and release of basal membrane substrate as well as providing a skeleton for tissue proliferation<sup>13-15</sup>. In our case, vitrectomy was performed due to retinal detachment and vitreous space was filled with silicone oil. We think that silicone oil covering macular hole provided a similar surface for closure of macular hole and that macular hole with vitrectomy and abandoned anteroposterior traction began to close spontaneously for this reason.

It was shown that epiretinal membrane may develop in macula following retinal detachment surgery<sup>16,17</sup>. The membrane can develop under silicone oil in patients with silicone oil<sup>17,18</sup>. Rashad et al. detected epiretinal membrane in 41% of cases in which OCT assessment was performed before silicone removal<sup>17</sup>. It was shown that concentrations of fibrogenic and inflammatory growth factors could be elevated in the fluid behind silicone oil. It was concluded that these factors contribute to peri-silicone proliferation<sup>18</sup>. We think that ERM under silicone oil might have been contributed to reopening of macular hole by applying tangential traction.

In our case, we used ILM flap to close macular hole. The inverted flap technique reduces risk for flat-open appearance after surgery and improves both functional and anatomical success in macular hole<sup>17,18</sup>. During post-operative surgery, no reopening was observed in macular hole.

In conclusion, spontaneous closure can be observed macular holes developed after retinal detachment surgery. Such patients can be managed by follow-up until silicone removal and successfully treated by appropriate surgical techniques during silicone removal.

## REFERENCES

1. Johnson RN, Gass JD. Idiopathic macular holes. Observations, stages of formation, and implications for surgical intervention. *Ophthalmology*. 1988;95(7):917-24.
2. Ho AC, Guyer DR, Fine SL. Macular hole. *Surv Ophthalmol*. 1998;42:393-416.
3. Gill MK, Lou PL. Traumatic macular holes. *Int Ophthalmol Clin*. 2002;42:97-106.
4. Takahashi H, Inoue M, Koto H, Itoh Y, Hirota K, Hirakata A. Inverted internal limiting membrane flap technique for treatment of macular hole retinal detachment in highly myopic eyes. *Retina* 2017 Oct 23. doi: 10.1097/IAE.0000000000001898. [Epub ahead of print]
5. Bakbak B, Gedik Ş, Öztürk BT, Kerimoğlu H. Spontaneous Closure of Macular Hole Induced by Accidental Nd:YAG Laser Injury. *Ret-Vit* 2013;21:124-126
6. Medina CA, Ortiz AG, Relhan N, Smiddy WE, Townsend JH, Flynn HW Jr. Macular hole after pars plana vitrectomy for rhegmatogenous retinal detachment. *Retina*. 2017 Jun;37(6):1065-1072.
7. Ozdemir E, Ozdek S. Recurrent opening and closure of macular hole after pars plana vitrectomy for rhegmatogenous retinal detachment. *Retin Cases Brief Rep*. 2018doi: 10.1097/ICB.0000000000000699. [Epub ahead of print].
8. Lee SH, Park KH, Kim JH, Heo JW, Yu HG, Chung H. Secondary macular hole formation after vitrectomy. *Retina*. 2010;30(7):1072-7.
9. Zhang W, Grewal DS, Jaffe GJ, Mahmoud TH, Fekrat S. Spontaneous Closure of Full-Thickness Macular Hole With Epiretinal Membrane in Vitrectomized Eyes: Case Series and Review of Literature. *Ophthalmic Surg Lasers Imaging Retina*. 2017 Feb 1;48(2):183-190
10. Morescalchi F, Cotagliola C, Gambicorti E, Duse S, Romano M, Semeraro F. Controversies over the role of internal limiting membrane peeling during vitrectomy in macular hole surgery. *Surv Ophthalmol*. 2017;62(1):58-69.
11. Bu SC, Kuijter R, van der Worp RJ, Huiskamp EA, Renardel de Lavalette VW, Li XR, Hooymans JM, Los LI. Glial cells and collagens in epiretinal membranes associated with idiopathic macular holes. *Retina*. 2014 May;34(5):897-906
12. Mester V, Kuhn F. Internal limiting membrane removal in the management of full-thickness macular holes. *Am J Ophthalmol*. 2000;129:769-777
13. Kuriyama S, Hayashi H, Jingami Y, Kuramoto N, Akita J, Matsumoto M. Efficacy of inverted internal limiting membrane flap technique for the treatment of macular hole in high myopia. *Am J Ophthalmol*. 2013;156(1):125-31
14. Shin MK, Park KH, Park SW., Byon IS, Lee JE. Perfluoro-n-octane-assisted single-layered inverted internal limiting membrane flap technique for macular hole surgery. *Retina*. 2014 Sep;34(9):1905-10
15. Michalewska Z, Michalevska J, Adelman RA, Nawrocki J. Inverted flap technique for large macular holes. *Ophthalmology* 2010;117(10):2018-2025.
16. Weng CY, Gregori NZ, Moysidis SN, Shi W, Smiddy WE, Flynn HW Jr. Visual and anatomical outcomes of macular epiretinal membrane peeling after previous rhegmatogenous retinal detachment repair. *Retina*. 2015 Jan;35(1):125-35.
17. Rashad MA, Mohamed AA, Ahmed AI. Value of optical coherence tomography in the detection of macular pathology before the removal of silicone oil. *Clin Ophthalmol*. 2016 Jan 19;10:121-35.
18. Asaria RH, Kon CH, Bunce C, Sethi CS, Limb GA, Khaw PT, Aylward GW, Charteris DG. Silicone oil concentrates fibrogenic growth factors in the retro-oil fluid. *Br J Ophthalmol*. 2004 Nov;88(11):1439-42.