

# Whiplash Makulopatinin Akut Evre Optik Koherens Tomografi Bulguları

## Acute Phase Optical Coherence Tomography Findings in Whiplash Maculopathy

Esra BİBEROĞLU<sup>1</sup>, Özlem ŞAHİN<sup>2</sup>

### ÖZ

Başın savrulmasına sebep olmuş araç içi trafik kazası sonrası her iki gözde görmeye azalma ve merkezi görmeye bozulma şikayeti ile başvuran 52 yaşında erkek hastanın optik koherens tomografisinde (OKT) her iki taraflı foveal pitin ve iç retina mimarisinin korunduğu yaygın maküler ödem, dış retinal segmentte kalınlaşma ve subretinal sıvı mevcuttu. Kazayı takip eden 2 haftada nonsteroid antiinflamatuvar tedavi ile ödem kademeli olarak çözüldü, görsel iyileşme sağlandı. 3. ay sonunda hastanın her iki gözde görme keskinliği tam, OKT' de tüm retina anatomisi normaldi. Whiplash yaralanmaları trafik kazaları sonrası sık görülmesine rağmen, isimlendirmeden dolayı whiplash makulopati tanısı literatürde çok az olguda tanımlanmıştır. Hastalar görme azalması ve merkezi görmeye bozulmadan şikayet eder. Literatürde retina değişikliklerinin kendiliğinden emilebileceği bildirilmiştir. Bizim olgumuzda bu patolojiyi açıkça göstermekle birlikte topikal nonsteroid antiinflamatuvar tedavi ile bulguları gerilemiştir.

**Anahtar Kelimeler:** Whiplash makulopati, travmatik makulopati, maküla ödemi.

### ABSTRACT

Following in-vehicle traffic accident causing whiplash injury, a 52-years old male patient presented with bilateral reduction in visual acuity and loss of central vision. There was diffuse macular edema, thickening at outer retinal segment and subretinal fluid with preserved bilateral foveal pit and inner retinal architecture on optical coherent tomography (OCT). Within 2 weeks following accident, edema was gradually resolved with topical non-steroidal anti-inflammatory treatment and visual improvement was achieved. At the end of the month 3, visual acuity was 20/20 in both eyes and the retinal anatomy was completely normal in OCT. Although whiplash injuries occur commonly after traffic accidents, whiplash maculopathy is extremely rare in the literature due to its denomination. Patients suffer from decreased vision and central scotoma. It has been reported that these retinal changes can be absorbed spontaneously. In our case; similar to previous publications, the pathology is clearly demonstrated. Apart from the others, in our case, findings were recovered with topical NSAID use

**Key Words:** Whiplash maculopathy, traumatic maculopathy, macular edema.

### INTRODUCTION

The whiplash injuries generally occur with consecutive flexion-extension movement of cervical spine due to backward forces subjected during accidents with slow velocity. Following traumas caused by sudden deceleration or stop, head, neck and trunk injuries are frequently seen while ocular injuries are rare. It has been reported that slightly decreased visual acuity, convergence and accommodation problems, oculomotor muscle paresis and vitreous detachment could be seen in association with

whiplash injuries.<sup>1</sup> The Whiplash maculopathy (WM) was first described as slightly decreased visual acuity in one or both eyes, foveolar depression and thickening in peripheral retina following head-neck injury caused by flexion-extension in a case series including 3 patients by Kelley in 1978.<sup>2</sup> In histological study by Parsons et al. photoreceptor impairment and local retinal pigment detachment with edema were shown in a young woman died due to whiplash injury.<sup>3</sup>

1- Uz. Dr., Marmara Üniversitesi Pendik Eğitim Araştırma Hastanesi, Göz Hastalıkları, İstanbul, Türkiye

2- Prof. Dr., Marmara Üniversitesi Pendik Eğitim Araştırma Hastanesi, Göz Hastalıkları, İstanbul, Türkiye

Geliş Tarihi - Received: 17.11.2017

Kabul Tarihi - Accepted: 23.02.2018

Ret-Vit 2019; 29: 85-87

Yazışma Adresi / Correspondence Address:

Özlem ŞAHİN

Marmara Üniversitesi Pendik Eğitim Araştırma Hastanesi, Göz Hastalıkları, İstanbul, Türkiye

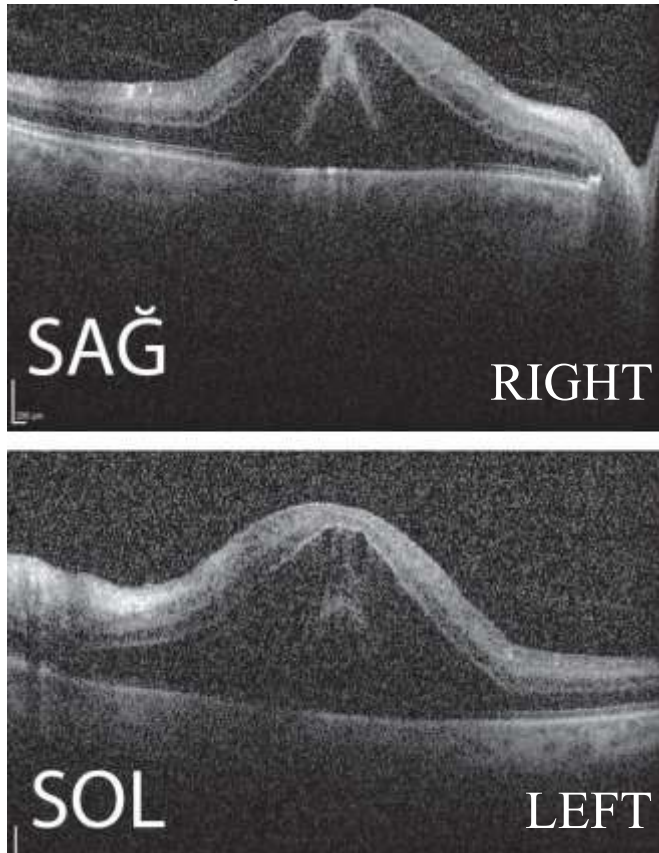
Phone:+90 532 494 1315

E-mail: ozlem.sahin@marmara.edu.tr

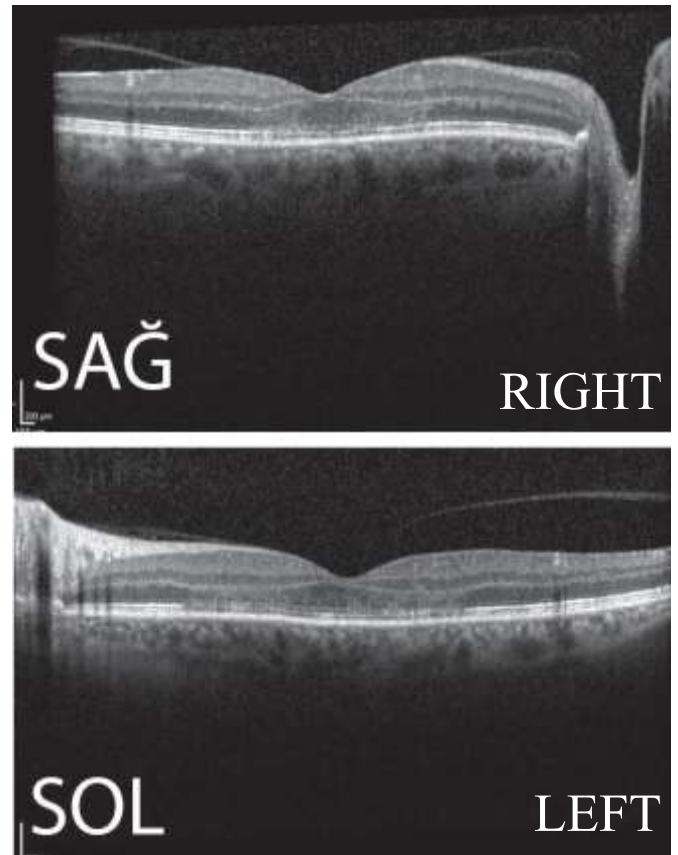
Diffuse macular edema with preserved foveal pit and intact retinal architecture, neurosensory detachment and thickening in outer retina segment have been reported on OCT.<sup>4-5</sup> In the literature, 8 cases with WM have been reported so far; however, no WM case has been reported from Turkey. Thus, this diagnosis could not be denoted in Turkish and mentioned as WM in this paper in accordance to literature.

#### OLGU SUNUMU

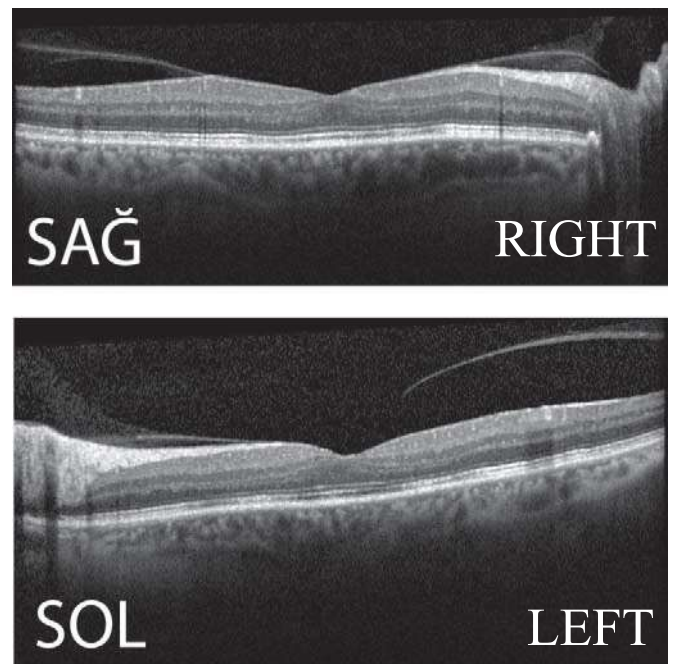
A 52-years old man presented with decreased visual acuity and impaired central vision in both eyes in the same day after in-vehicle traffic accident causing head swing. Visual acuity was 0.6 in left and right eyes. Anterior segment examination and intraocular pressure were considered as normal in both eyes; however, fundoscopy revealed changes in macular pigment epithelium and edema (Picture 1). Peripheral retinal examination was normal. On optic coherence tomography (OCT), there was macular edema with preserved foveal pit and inner retinal anatomy, irregularity and thickening in outer photoreceptor segment and neurosensory detachment (Central macular thickness [CMT], right: 664  $\mu\text{m}$ , left: 947  $\mu\text{m}$ ). During 2 weeks following accident, edema was gradually resolved with non-steroidal anti-inflammatory treatment; however, irregularities in outer photoreceptor segment persisted (CMT right: 226  $\mu\text{m}$ , left: 245  $\mu\text{m}$ ) (Picture 2). At the end of month 8, visual acuity was completely recovered in both eyes and whole retinal anatomy was normal on OCT (Picture 3).



**Picture 1:** Diffuse macular edema with preserved foveal pit and neurosensory detachment on OCT at presentation



**Picture 2.** Resolved macular edema and ongoing photoreceptor irregularity on OCT at week 2



**Picture 3:** OCT imaging on month 8

#### DISCUSSION

Although whiplash injuries are commonly seen following traffic accidents, WM has been described in very limited cases due to its denomination WM.

The disease pathology is poorly understood, progressing with macular edema caused by traction in base of vitreous in eye. The WM patients suffer from decreased visual acuity and impaired central vision. In the literature, retinal changes can be resolved spontaneously.<sup>4,6</sup> In a patient with bilateral traumatic maculopathy, Navarro et al. reported that maculopathy can develop due to vascular factors resulting from increased intravascular pressure by excluding mechanic causes.<sup>7</sup> Differential diagnosis is comprehensive, including toxic maculopathies, shaken baby syndrome, valsalva retinopathy and Purtscher retinopathy.<sup>4</sup> The OCT is valuable in demonstrating WM-related lesions in vitreoretinal interface and abnormalities in outer photoreceptor segment.<sup>8</sup> <sup>9</sup> We could not find a case termed as WM in Turkey. However, there are publications reporting macular edema, macular hole, retinal tear, intravitreal hemorrhage, choroid rupture and retinal detachment caused by blunt trauma.<sup>10-11</sup>

In WM, rapid deceleration and acceleration forces lead focal detachment in retinal pigment-epithelium junction, resulting in vision loss. Despite lacking of direct ocular trauma, extreme acceleration and deceleration forces together with rapid anteroposterior stress of vitreous can cause retinal traction, capillary displacement, fluid leakage, local detachment of retinal layers, resulting in macular edema. Also, our case apparently represents this pathology in agreement with literature. In addition, it is also important as it demonstrated OCT findings of bilateral WM.<sup>5</sup> On contrary to literature, we added NSAID agent to treatment and achieved regression in findings. Although this treatment is controversial, it may spontaneously regress without treatment. Our case might also have been absorbed spontaneously.

## CONCLUSION

The Whiplash maculopathy is associated to local retinal concussion. History is important to define characteristic pathology since patients may fail to give detailed history about trauma. They may overlook sudden deceleration movement or head swing in history. This may result in unnecessary anti-VGEF therapy in patients presenting with cystoid macula edema that may resolve spontaneously if detailed history is lacking. OCT is of important in differential diagnosis as it shows preserved pit and intact inner retinal architecture. Finally, by presenting this case, we aimed to add WM in Turkish literature.

## REFERENCES

1. Burke JP, Orton HP, West J, Strachan IM, Hockey MS, Ferguson DG. Whiplash and its effect on the visual system. *Graefes Arch Clin Exp Ophthalmol.* 1992;230(4):335-9.
2. Kelley JS, Hoover RE, George T. Whiplash maculopathy. *Arch Ophthalmol.* 1978;96(5):834-5.
3. Parsons MA, Talbot JF, Mudhar HS, Ruttly GN. The pathology of whiplash maculopathy and retinopathy : Illustrated observations derived from a fatal roller-coaster accident. *Forensic Sci Med Pathol.* 2005;1(1):19-25.
4. Chronopoulos A, Lipski A, Jonescu-Cuypers CP, Thumann G. Unusual bilateral traumatic maculopathy following whiplash injury. *BMJ Case Rep.* 2014;2014.
5. Pham TQ, Chua B, Gorbатов M, Mitchell P. Optical coherence tomography findings of acute traumatic maculopathy following motor vehicle accident. *American journal of ophthalmology.* 2007 Feb 1;143(2):348-50.
6. Uebbing C, Miller J, Arnold C, Walsh M. Soccer player whiplash maculopathy. *Am J Emerg Med.* 2010;28(1):120 e7-8.
7. Andonegui Navarro J, Prat Madrazo M. [Bilateral traumatic retinopathy associated to whiplash injury]. *Arch Soc Esp Oftalmol.* 2004;79(4):185-8.
8. Mavrakanas N, Dreifuss S, Safran AB. OCT III imaging of whiplash maculopathy. *Eye (Lond).* 2008;22(6):860-1.
9. McCannel CA. OCT III imaging of whiplash maculopathy. *Eye (Lond).* 2011;25(4):531-2.
10. Ocakoğlu Ö, Avras S, Müftüoğlu G, Akar S, AD CTFGH. Künt glob travmalarında arka segment bulguları. *Journal of Retina-Vitreous.* 1994;2(2):170-4.
11. Aslan Ö, Batman C, Çekiç O, Özalp S. Künt ve delici göz yaralanmaları sonrası gelişen retina dekolmanlarında anatomik ve fonksiyonel başarı. *Journal of Retina-Vitreous.* 2000;8(1):74-9.