

Mydriasis as a Sole Sign of Siderosis Bulbi Resulting From an Unnoticed Trauma and Intraocular Metallic Foreign Body

Farkedilmeyen Travma ve Göziçi Metalik Yabancı Cisim Nedeniyle Meydana Gelen Siderosis Bulbinin Tek Bulgusu Olarak Midriasis

Hande ÇELİKER¹, Haluk KAZOKOĞLU², Osman ÇEKİÇ²

ABSTRACT

We aimed to report a case of unnoticed, retained metallic intraocular foreign body that did not show any findings of the ocular siderosis but mydriasis initially. An 8-year-old boy was referred to our clinic for monocular mydriasis. The child as well as the parents denied any recent or past trauma history to the eye. An intraocular foreign body was detected at cranial computed tomography. After the removal of the intraocular foreign body, mydriasis recovered, however, due to the development of proliferative vitreoretinopathy, eventual functional success was poor after several vitrectomies. In conclusion, intraocular foreign body and iron mydriasis should be kept in mind in the differential diagnosis of a dilated and fixed pupil and treatment-resistant uveitis.

Key Words: Intraocular foreign body, Mydriasis, Ocular siderosis, Retinal detachment, Trauma.

ÖZ

Bu raporda, başlangıçta midriasis haricinde hiçbir oküler siderozis bulgusu vermeyen, göz içindeki varlığı bilinmeyen metalik yabancı cisim olan bir olguyu sunmayı amaçladık. Tek gözünde midriyazisi olan 8 yaşında bir çocuk hasta kliniğimize refere edildi. Çocuk ve ailesi bugün ve geçmişte gözde herhangi bir travma öyküsünün olmadığını belirttiler. Çekilen bilgisayarlı beyin tomografisi yabancı cisim izlenmekteydi. Göz içerisindeki yabancı cismin (GİYÇ) çıkarılmasından sonra midriasis normale döndü ancak proliferatif vitreoretinopati gelişmesi nedeniyle uygulanan pek çok vitrektomi cerrahisinin ardından fonksiyonel başarı düşük kaldı. Sonuç olarak, dilate ve fiks pupillasi ve tedaviye dirençli üveiti olan olgularda GİYÇ ve demir midriyazisi ayırıcı tanıda akılda tutulmalıdır.

Anahtar Kelimeler: Göziçi yabancı cisim, Midriasis, Oküler siderosis, Retina dekolmanı, Travma.

INTRODUCTION

It can be difficult to diagnose in cases with mydriasis. Regarding the etiology, two possibilities should initially be considered: one being in the central nervous system (midbrain), the other being in the peripheral nervous system (ciliary ganglion-short ciliary nerves).¹ Association of mydriasis with some other conditions as in the case of a metallic intraocular foreign body (IOFB), is also possible.

The condition that was reported in two patients with a fixed, dilated pupil as the presenting sign of an IOFB, was named as ‘iron mydriasis’.² Iron contamination of intraocular tissues causes a characteristic clinical picture termed siderosis. Iron mydriasis is a component of the siderosis bulbi. We report a case of unnoticed, retained metallic intraocular foreign body that did not show any findings of the ocular siderosis but mydriasis initially.

1- Yrd. Doç. Dr., Marmara Üniversitesi Tıp Fakültesi, Göz Hastalıkları, İstanbul, Türkiye

2- Prof. Dr., Marmara Üniversitesi Tıp Fakültesi, Göz Hastalıkları, İstanbul, Türkiye

Geliş Tarihi - Received: 08.04.2018

Kabul Tarihi - Accepted: 16.10.2018

Ret-Vit 2019; 28: 322-324

Yazışma Adresi / Correspondence Address:

Hande ÇELİKER

Marmara Üniversitesi Tıp Fakültesi, Göz Hastalıkları, İstanbul, Türkiye

Phone: +90 532 215 7740

E-mail: drhandeceliker@yahoo.com

CASE REPORT

An 8-year-old boy was referred to our clinic for fixed monocular mydriasis. The parents stated that they had noticed unequal pupil size after a recent bout of flu with fever in the boy. The child as well as the parents denied any recent or past trauma history to the eye. At presentation, his best corrected visual acuity (VA) was 20/25 in the right eye (RE) and 20/20 in the left eye (LE). Bilateral IOPs were 11mmHg. Bilateral detailed examination of the anterior chamber revealed no abnormality except a fixed dilated pupil in RE. Both irides were the same color, brown and regular except unilateral mydriasis. The right pupil did not react to direct and indirect light stimulation and with maximal near effort, and the direct and indirect pupillary light reflexes were normal in the LE. There was no evidence of ptosis and limitation of extraocular motility. One drop of pilocarpine 1% was applied in two consecutive days, constriction of the both pupil was occurred. The pilocarpine 0.1% was also implemented, constriction of the right pupil was observed, however, it had no effect on the left pupil. Difference of the pupillary sizes are shown in Figure 1. No clinical abnormalities were appreciated upon examination of the retina with binocular indirect ophthalmoscopy of both eyes (Figure 2A and 2B).

Neuropediatricians took over the patient and followed him for a while. His fever got normalized without any treatment but mydriasis persisted for the next 10 days. Two months

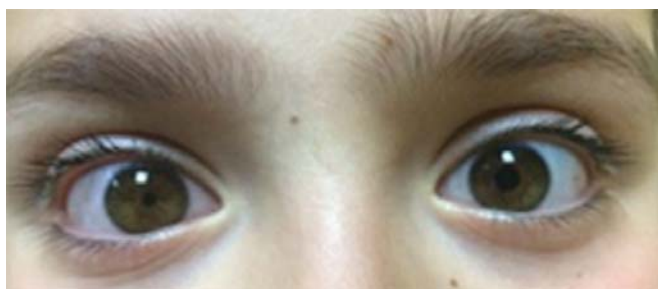

Figure 1. One drop of pilocarpine 1% as well as pilocarpine 0.1% applied in temporally different settings, produced constriction of the right pupil but had no effect on the left pupil. This picture was observed after the instillation of 0.1% of pilocarpine eye drop.

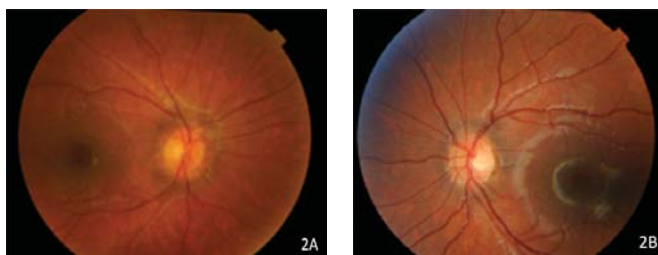

Figure 2A. Retinal examination of right eye revealed normal findings at the first presentation. **2B.** Retinal examination of left eye revealed normal findings at the first presentation.

later, the patient returned with a sudden visual loss to light perception in RE. The pupil was still dilated and nonreactive to light. A severe inflammation of the anterior chamber and dense vitreous was detected. Fundus examination limited due to severe vitritis. This inflammation was resistant to anti-inflammatory treatment. The ocular examination of LE disclosed normal findings. An IOFB was noticed at pars plana with cranial CT (Figure 3). There was no sign of an entry site in the eye, iris laceration, or any lenticular capsular perforation. Lens sparing pars plana vitrectomy (PPV) was carried out immediately and a metallic IOFB, with an overall diameter of 0.2x0.1 cm, (Figure 4) was extracted. Sulfur hexafluoride gas was injected at the end of the surgery. Two weeks later, mydriasis disappeared. One month later, retinal re-detachment due to severe proliferative

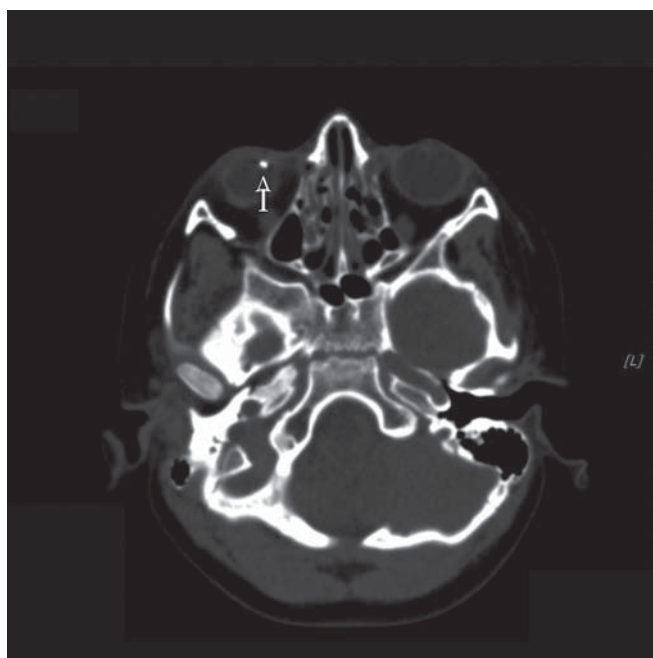


Figure 3. Cranial computerized tomography shows an intraocular foreign body located pars plana (arrow).




Figure 4. Extracted intraocular foreign body.

vitreoretinopathy occurred under the silicon oil. Revision vitrectomy and silicone oil infusion was carried out. Sixteen months following the silicone oil extraction, his VA was hand movements, IOP was 10mmHg, pupil size was normal, and the retina was totally flat.

DISCUSSION

Paralytic mydriasis has long been known as one of the findings in ocular siderosis.³ It was actually the sole presenting sign of a metallic IOFB in this patient. Tuckett⁴ claimed that the sympathetic nerve endings are injured by iron salts and the dilator pupillae muscle loses its function. Verhoeff⁵ reported that it was due to damage to the iris sphincter, since deposition of iron in the iris muscle was demonstrated. Monteiro et al² revealed that the iris muscle is able to contract after observing the pupil constricted to 0.5% pilocarpine eye drops. They suggested that the lesion could be either at the nerve terminals or at the synapses. Adie's tonic pupil is a sign of ocular siderosis in retained metallic IOFB. The pupil responds to pilocarpine 0.1% showing the cholinergic denervation hypersensitivity distinctive of Adie's tonic pupil. In the present case, the pupil responded to one drop of 1% and 0.1% pilocarpine, representing denervation supersensitivity.

Cases of iron mydriasis may lead to diagnostic confusion with third nerve lesions, pharmacologic blockage, Adie's tonic pupil, or local damage to the iris muscle.¹ Tonic pupils constrict poorly to light but usually respond well to near effort. In this case, the right pupil did not react to maximal near effort. Pharmacologic blockage to the pupil is usually diagnosed by a careful medical history taking.¹ Damage to the iris muscle by trauma, acute glaucoma, or iris disease is usually diagnosed by a careful ophthalmic examination. Third nerve lesions can be detected by advanced neuro-radiologic procedures.

There are some reports about cases with missed diagnosis. In our opinion, this may be understandable since iron mydriasis is usually not part of the differential diagnosis of a fixed and dilated pupil.^{1,2,6} Similar to a previous report⁷, we did

not find any evidence of the entrance to the eye, could not realize any intraocular abnormality by using a slit lamp or an indirect ophthalmoscope, therefore, diagnosis was delayed. Weiss et al.⁸ reported that they could not discover IOFB in their cases with CT as well. Nevertheless they emphasized that CT scanning is still considered the gold standard for the detection and localization of an occult metallic IOFB. Barr et al⁹ reported a case with unexplained heterochromia at which CT was used to confirm the presence of IOFB which could not be realized by clinical and X-ray examinations.

In conclusion, iron mydriasis should be kept in mind in the differential diagnosis of a dilated and fixed pupil. Even if there is no sign of ocular trauma and entrance hole, severe and treatment-resistant anterior and intermediate uveitis may be an indicator of an unnoticed IOFB. In addition, CT can be used in patients with unilateral mydriasis who have absence of definite history of trauma to suspect of an IOFB.

REFERENCES / KAYNAKLAR

1. Thompson HS, Newsome DA, Loewenfeld IE. The fixed dilated pupil: sudden iridoplegia or myriatic drops? – a simple diagnostic test. *Arch Ophthalmol* 1971; 86:21-7.
2. Monteiro MLR, Ulrich RF, Imes RK, et al. Iron mydriasis. *Am J Ophthalmol* 1984;97:794-6.
3. Welch RB. Two remarkable events in the field of intraocular foreign body: (1) The reversal of siderosis bulbi. (2) The spontaneous extrusion of an intraocular copper foreign body. *Trans Am Ophthalmol Soc* 1975;73:187-203.
4. Tuckett ILL. A case of siderosis affecting the innervation of the pupil. *Br J Ophthalmol* 1918;2:79-82.
5. Verhoeff FH. Siderosis bulbi. *Br J Ophthalmol* 1918;2:571-3.
6. Rubinfeld RS, Currie JN. Accidental mydriasis from blue nightshade 'lipstick'. *J Clin Neuroophthalmol* 1987;7:34-7.
7. Monteiro ML, Coppeto JR, Milani JA. Iron mydriasis. Pupillary paresis from occult intraocular foreign body. *J Clin Neuroophthalmol* 1993;13:254-7.
8. Weiss MJ, Hofeldt AJ, Behrens M, et al. Ocular siderosis. Diagnosis and management. *Retina* 1997;17:105-8.
9. Barr CC, Vine AK, Martonyi CL. Unexplained heterochromia. Intraocular foreign body demonstrated by computed tomography. *Surv Ophthalmol* 1984;28:409-11.