

An Unusual Presentation of Multifocal Choroiditis in Ocular Bartonellosis

Ibrahim Inan HARBIYELI¹, Ebru ESEN², Selcuk SIZMAZ², Nihal DEMIRCAN³

ABSTRACT

A 38-year-old woman was admitted with a complaint of decreased vision in the right eye for 4 days. Fundus examination of the right eye revealed optic disc edema and macular elevation. Optical coherence tomography (OCT) of the right eye showed a choroidal volcanic configuration and subretinal fluid at the macular area and the peripapillary region. The fluorescein angiographic examination of the right eye revealed a lesion with early hypofluorescence and late hyperfluorescence with leakage, also hyperfluorescence at the optic disc. Regression of volcanic configuration in section through the macula and newly developed choroidal volcanic configuration in sections passing through above the macula was detected in OCT 3 weeks after the first visit. Laboratory investigations showed raised IgM and IgG titres for *Bartonella henselae*. Rifampicin and doxycycline were administered orally. Subretinal fluid and chorioretinal signs disappeared over the ensuing 1 month.

Bartonella involves posterior segment in various clinical forms. In our case, choroidal involvement was presented as shifting foci of choroiditis. To keep this clinical form of multifocal choroiditis in mind may be helpful to identify these lesions and to suggest ocular bartonellosis within differential diagnosis when observed prior to serological diagnosis.

Key Words: *Bartonella henselae*, Multifocal choroiditis, Ocular bartonellosis

INTRODUCTION

Bartonella infection is transmitted to humans through a cat-scratch or bite or superficial wound infection.^{1,2} Localized benign lymphadenopathy may be accompanied by relapsing fever, chills, malaise, and night sweat after transmission.^{1,2,3} Chronic ulcerative conjunctivitis is the first reported ocular manifestation of cat scratch disease.⁴ *Bartonella* infection in the eye presents as unilateral neuroretinitis characterized by optic disc edema with a macular star.^{1,2} We describe a case of ocular bartonellosis in a woman with unilateral sudden painless vision loss, papillitis and choroiditis.

CASE REPORT

A 38-year-old female patient admitted with a complaint of blurred vision in the right eye for 4 days in March 2016. The patient was receiving levothyroxine for Hashimoto's thyroiditis. She did not have any known eye disease, ocular drug use, trauma history or a contact with an animal. Also,

her medical history was unremarkable in the last few months.

Best corrected visual acuity (BCVA) was 20/40 in the right eye and 20/20 in the left eye. There was a relative afferent pupillary defect in the right eye. Anterior segments for both the eyes were normal. The intraocular pressure was 16 mmHg in both eyes. Fundus examination of the right eye revealed optic disc edema with indistinct margins, increased retinal vascular tortuosity, macular elevation, choroidal and subretinal lesions superotemporal to the optic disc (Figure 1). Fundus examination of the left eye and systemic examination were normal.

Optical coherence tomography (OCT) showed choroidal volcanic configuration and subretinal fluid accumulation in sections through the macula in the right eye. (Figure 2A, B, C). In fundus fluorescein angiography (FFA), the lesion revealed hypofluorescence in the early phase and punctate hyperfluorescence in the late phase, as well as hyperfluorescence due to leakage at the optic disc and in the inferotemporal macula in the late phase in the right

1- Assistant Prof., MD., Cukurova University Medical School, Ophthalmology Department, Adana, Turkey

2- Associate Prof., MD., Cukurova University Medical School, Ophthalmology Department, Adana, Turkey

3- Prof. MD., Cukurova University Medical School, Ophthalmology Department, Adana, Turkey

Received: 27.07.2019

Accepted: 23.10.2019

Ret-Vit 2020; 29: 266-269

DOI:10.37845/ret.vit.2020.29.48

Correspondence Address:

Ibrahim Inan HARBIYELI

Cukurova University Medical School, Ophthalmology Department, Adana, Turkey

Phone: +90 322 338 6060

E-mail: inanharbiyeli@hotmail.com

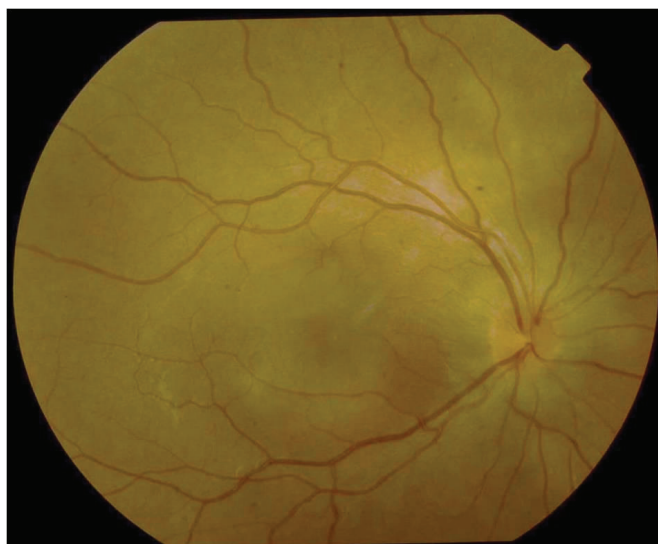


Figure 1. Fundus picture of the right eye at initial presentation. Optic disc edema, macular elevation, choroidal and subretinal lesions superotemporal to disc.

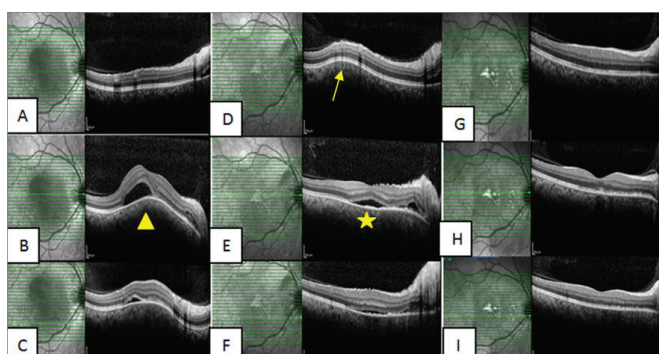


Figure 2. A, B, C) OCT of the right eye showed choroidal "volcanic" configuration (arrowhead) and subretinal fluid accumulation in sections through the macula at initial presentation. D, E, F) Sections at the same localisations 3 weeks after initial examination. Newly developed choroidal "volcanic" configuration in sections passing through above the macula (arrow). Decrease of subretinal fluid in sections passing through the macula and below the macula, regression of "volcanic" configuration in section through the macula (star). G, H, I) Sections at the same localisations 1 month after treatment.

eye (Figure 3A, B). Ocular ultrasonography of right eye showed marked choroidal thickening in the upper temporal quadrant. No significant visual field defect was observed in the visual field examination. Orbital magnetic resonance imaging (MRI) revealed mild choroidal thickening and contrast enhancement at the level of the optic disc in the right eye.

Within the scope of systemic evaluation for etiology, following consultations were requested: thoracic consultation for exclusion of sarcoidosis and tuberculosis,

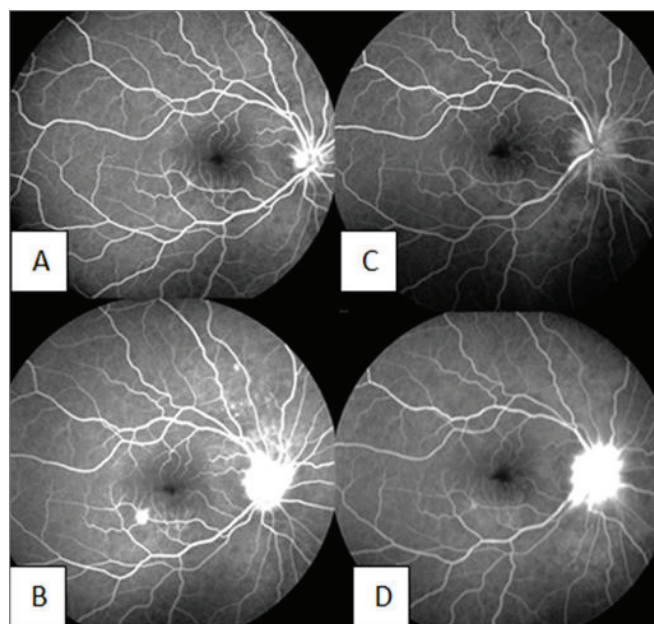


Figure 3. A,B) Fluorescein angiographic photographs of the right eye at initial presentation. Early hypofluorescence and late hyperfluorescence due to leakage on the superotemporal to the disc corresponding to the choroidal and subretinal lesions. Hyperfluorescence due to leakage at the optic disc and inferotemporal to macula in the late phase of the angiography C, D) Angiographic findings 3 weeks after initial examination. Persistent hyperfluorescence at the optic disc and disappeared leakage at inferotemporal to macula.

dermatological consultation for evaluating Behçet's disease, and neurological consultation for investigation of the Vogt – Kayanagi–Harada disease. Serological tests for possible infectious pathogens (hepatitis markers, Salmonella, Brucella, Bartonella, Lyme, TORCH agents) were done.

The patient was followed up closely without treatment while the clinical tests were underway. No significant change was observed during the first 2-week follow-up period. While there was no change in BCVA, decrease of subretinal fluid spontaneously in sections passing through macula and below the macula was observed in OCT 3 weeks after the first visit. Regression of volcanic configuration in section through the macula and newly developed choroidal volcanic configuration in sections passing through above the macula was detected (Figure 2D, E, F). Also, subretinal fluid was observed in the peripapillary region. In the FFA, hyperfluorescence at the optic disc persisted and the leakage detected below the macula in the first FFA was disappeared. (Figure 3C, D).

In the consultations, no pathologic finding was observed except a high thyroid-stimulating hormone level that

is considered to be associated with the Hashimoto's thyroiditis and thyroid ultrasound findings. Indirect immunofluorescence antibody test was positive for *Bartonella henselae* Ig M and Ig G. Other serological tests for possible infectious pathogens were negative. Oral doxycycline 2x100 mg/day and rifampicin 2x300 mg/day was administered. The BCVA improved to 20/25 in the right eye after 2 weeks of treatment. In the examination, the optic disc was mildly edematous and its margins were blurred in the right eye. In OCT, the submacular fluid and the macular thickness significantly decreased and recently developed choroidal volcanic configuration in sections passing through above the macula disappeared. The BCVA was 20/20 in the right eye after 1 month of treatment. In OCT, subretinal fluid was completely resolved. Retinal pigment epithelial changes were noted within the macula (Figure 2G, H, I).

CONCLUSION

In different series of ocular *Bartonella* infection, intermediate uveitis, focal retinitis or choroiditis and neuroretinitis accompanied by macular star formation were reported as distinctive forms of involvement.¹ Neuroretinitis with optic nerve head edema and macular star formation is detected in 1-2% of *Bartonella* infections. Peripapillary serous retinal detachment can be an early finding in these cases.⁵ Involvements in the form of focal or multifocal retinitis, choroiditis, retinochoroiditis may be seen independently without accompanying neuroretinitis, or with optic disc edema.² In our case, ocular involvement appeared as optic disc edema accompanying retinochoroiditis causing subretinal fluid accumulation. Macular star formation was not observed during the follow-up. The choroidal elevated lesion detected by OCT showed a "volcanic configuration" similar to the appearance of solitary idiopathic choroiditis case as described by Kumar et al.⁶ However, our case showed a shift in the localization of this lesion during follow-up. To our knowledge, this clinical presentation has not been described previously in ocular bartonellosis. These findings related to choroidal involvement were remarkable in terms of presentation of multifocal choroiditis in ocular bartonellosis. To keep this clinical form of choroidal involvement in mind may be helpful to suggest *Bartonella* infection within differential diagnosis when observed prior to serological diagnosis. Additionally, these lesions may be more recognizable for the physician who is aware of possible shifting choroidal lesions during course of the disease.

The indirect immunofluorescence for antibodies to

Bartonella henselae has a sensitivity and specificity of 90% in immunocompetents.² A serologic test repeated 2 months later in case of serologic negativity may reveal the agent.⁷ In our case, the detection of both Ig M and Ig G positivity by indirect immunofluorescence antibody test conducted 1 month after the onset of symptoms was important in order that effective treatment could start decisively.

Although ocular findings in *Bartonella henselae* infection may accompany the systemic findings of cat scratch disease, it may be seen as the only finding in many cases.^{1,7} Kalogoropoulos et al. reported that 70% of the cases did not experience a systemic illness preceding the intraocular inflammatory manifestations.⁷ In our case, there was no systemic finding associated with *Bartonella* infection both prior to ocular symptoms and during follow-up examinations.

In *Bartonella* infections, there is a history of contact with animals that may be the source of the agent in many cases.^{1,2,4} However, absence of a suspicious contact in the anamnesis does not exclude the possibility of *Bartonella*.⁶ Thus, there was no suspicious animal contact in the medical history or evidence of a lice or tick infestation in the examination.

Bartonella retinitis, poses an indication for systemic antibiotic therapy in *Bartonella* infections. The combination of doxycycline (100 mg twice daily) and rifampicin (300 mg twice daily) is an effective treatment regimen.¹ In our case, improvement in retinal findings and increase in visual acuity were observed within 2 weeks after treatment. BCVA increased to 20/20 and the chorioretinal findings completely disappeared 1 month after treatment.

With the development in serologic examination methods, the number of cases diagnosed with *Bartonella* infection has been increased in recent years. As, this agent might cause posterior segment involvement in various forms, should be considered in the preliminary diagnosis.

Acknowledgments

Financial support: No financial support was received for this submission.

Conflict of interest: None of the authors has conflict of interest with this submission.

Meeting presentation: The data included in this article were presented at the 10th Congress of the Asia-Pacific Vitreo-retina Society (APVRS), Bangkok, Thailand, December 8-10, 2016.

REFERENCES

1. Biancardi AL, Curi AL. Cat-scratch disease. *Ocul Immunol Inflamm* 2014; 22:148-54.
2. Latanza L, Viscogliosi F, Solimeo A, Calabrò F, De Angelis V, De Rosa P. Choroidal neovascularisation as an unusual ophthalmic manifestation of cat-scratch disease in an 8-year-old girl. *Int Ophthalmol* 2015; 35:709-16.
3. Metz CH, Buer J, Bornfeld N, Lipski A. Bilateral Bartonella henselae neuroretinitis with stellate maculopathy in a 6-year-old boy. *Infection* 2012;40:191-94.
4. Curi AL, Machado D, Heringer G, Campos WR, Lamas C, Rozental T, et al., Cat-scratch disease: ocular manifestations and visual outcome. *Int Ophthalmol* 2010; 30 :553-58.
5. Wade NK, Levi L, Jones MR, Bhisitkul R, Fine L, Cunningham ET Jr. Optic disk edema associated with peripapillary serous retinal detachment:an early sign of systemic Bartonella henselae infection. *Am J Ophthalmol* 2000; 130 :327–34.
6. Kumar V, Khoo CT, Shields CL. Solitary idiopathic choroiditis in the setting of extensive animal exposure. *Retinal Cases and Brief Reports* 2016; 10:386-88.
7. Kalogeropoulos C, Koumpoulis I, Mentis A, Pappa C, Zafeiropoulos P, Aspiotis M. Bartonella and intraocular inflammation: a series of cases and review of literature. *Clin Ophthalmol* 2011;5:817-29.