

# Nivolumab-Related Unilateral Panuveitis in a Patient with Metastatic Malignant Melanoma

Ziya AYHAN<sup>1</sup>, Sadettin USLU<sup>2</sup>, Sefik Can IPEK<sup>3</sup>, Sinan UNAL<sup>4</sup>, Fatos ONEN<sup>5</sup>, Isil SOMALI<sup>4</sup>, Ali Osman SAATCI<sup>6</sup>

## ABSTRACT

Nivolumab is one of the new generation anti-cancer drugs used in the treatment of metastatic malignant melanoma, which acts by stimulating the immune system. Unilateral panuveitis was diagnosed in the left eye of 45 years-old man who was on nivolumab treatment for metastatic cutaneous malignant melanoma and presented with anterior uveitis, vitritis and macular edema. Nivolumab treatment was discontinued and two intravitreal dexamethasone implants were administered to left eye 4-months interval. The signs and symptoms were improved within 6 months of follow-up. We aimed to emphasize the need for the careful review of systemic disease history and the drugs used in patients diagnosed with uveitis and to increase awareness of clinicians regarding potential ocular side effects of new generation anti-cancer drugs.

**Key words:** Dexamethasone implant, Nivolumab, Panuveitis.

## INTRODUCTION

The immunology-based treatment modalities have been increasingly used in the treatment of cancers. There are some inhibitor control mechanisms in the normal immunological balance of body and this system is termed as immune checkpoints. Such checkpoints are important steps in the control of immunologic reactions and inhibit immune response if needed. Cancer cells also express the checkpoints on their cell surface; thus, inhibit immunologic reaction and protect themselves against potential immunologic reaction. In the immune-based cancer treatment, immunological response against cancer cells is enhanced by inhibiting these inhibitor pathways (checkpoint inhibitors). These new generation agents target cytotoxic T lymphocyte antigen 4 (CTLA4, ipilimumab), programmed cell death 1 (PD-1, pembrolizumab, nivolumab) and programmed cell death ligand 1 (PD-L1, atezolizumab, avelumab, durvalumab).<sup>1-4</sup> They are used, either alone or in combination, in the treatment of several malignancies including malignant melanoma, renal cell carcinoma, non-small cell lung cancer, ovarian cancer, Hodgkin lymphoma, head-neck cancers and

urothelial carcinoma. In these agents, mechanism of action is based on production of excessive immune response by preventing function of checkpoints that control immune system activation. Thus, activation of immune system leads immune-related adverse events (IRAEs).<sup>2-5</sup> Ophthalmic IRAEs are infrequent and reported in less than 1% of patients.<sup>4-7</sup> Here, we assessed unilateral panuveitis in the patient receiving nivolumab therapy for malignant melanoma and discussed potential ocular side effects of checkpoint inhibitors.

## CASE REPORT

A 45-years old man was referred to our clinic with initial diagnosis of anterior uveitis by another center where he presented with blurred vision in left eye. In his history, it was found out that he experienced enlargement in the nevus (which is present since birth) at right post-auricular region and that the nevus was excised by plastic surgery in 2009. Again, it was found out that the nevus was diagnosed as stage 2B malignant melanoma and the patients was given high-dose interferon therapy which stabilized disease over one-year; thereafter, he received 12 sessions

1- MD, Assoc. Prof. Ophthalmology Department, Dokuz Eylul University School of Medicine, Balcova, Izmir, Turkey

2- MD, Ophthalmologist, Internal Medicine, Rheumatology Department, Dokuz Eylul University School of Medicine, Balcova, Izmir, Turkey

3- MD, Ophthalmologist, Ophthalmology Department, Dokuz Eylul University School of Medicine, Balcova, Izmir, Turkey

4- MD, Ophthalmologist, Internal Medicine, Medical Oncology Department, Dokuz Eylul University School of Medicine, Balcova, Izmir, Turkey,

5- MD, Prof., Internal Medicine, Rheumatology Department, Dokuz Eylul University School of Medicine, Balcova, Izmir, Turkey

6- MD, Prof., Ophthalmology Department, Dokuz Eylul University School of Medicine, Balcova, Izmir, Turkey

**Received:** 24.11.2019

**Accepted:** 21.05.2020

*Ret-Vit* 2020; 29: 340-344

DOI: 10.37845/ret.vit.2020.29.62

**Correspondence Address:**

Ali Osman SAATCI

Ophthalmology Department, Dokuz Eylul University School of Medicine, Balcova, Izmir, Turkey

**Phone:** +90 532 743 7071

**E-mail:** osman.saatci@deu.edu.tr

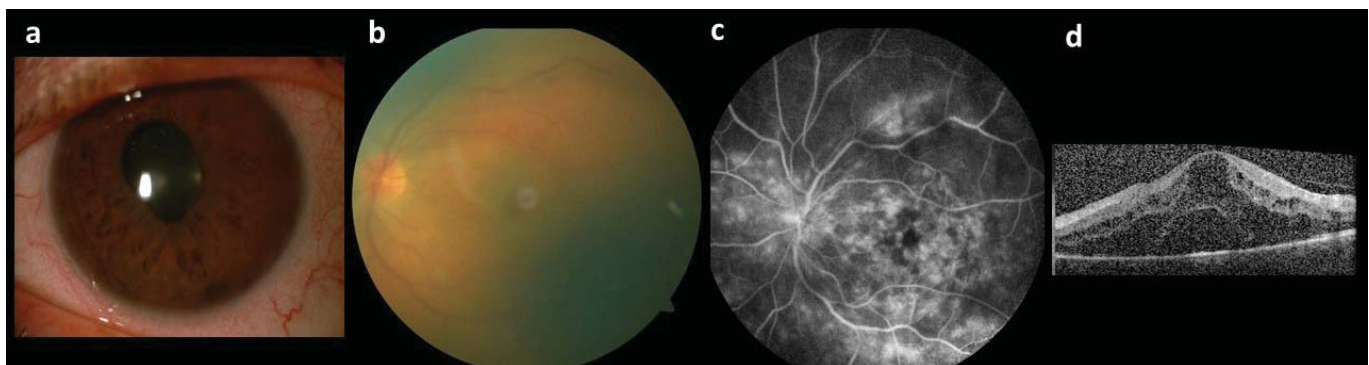
of temozolomide therapy due to hepatic metastasis. The disease was stabilized over one year again after temozolomide therapy but metastatic foci were detected at supraclavicular region and the patient underwent 4 sessions of ipilimumab therapy which achieved 2-years of remission. However, hepatic and pulmonary metastases were detected in the control visits; thus, he was given 4 sessions of ipilimumab plus nivolumab combination. The combination treatment caused immune-related diarrhea which resulted in hospitalization and intravenous steroid therapy. In addition, it was found out that the patient developed swelling at knees and hands during ipilimumab plus nivolumab therapy and was given methotrexate and non-steroidal anti-inflammatory drug therapy with diagnosis seronegative polyarthritis. In the patient, regression was detected with this treatment regimen and he was receiving nivolumab therapy.

In the ophthalmological examination, best-corrected visual acuity (BCVA) as measured by Snellen chart was 1.0 (full vision) in right eye and 0.1 in the left eye. In anterior segment examination, right eye was found to be normal while there was +/+ Tyndall, fine keratic precipitates and 210° posterior synechia were detected in left eye (Picture 1a). Intraocular pressure was within normal range in both eyes. In fundus examination, optic disc, macula and peripheral retina were normal in the right eye while there was grade 4 to 5 vitritis as rated by Miami Scale of Vitreous Haze in left eye (Picture 1b) and no detailed assessment could be performed in retinal tissue. On fundus fluorescein angiography, retinal and vascular structures were normal in right eye while diffuse vascular leakage including posterior pole was observed in the left eye (Picture 1c). On OCT, macular contour was normal in right eye while cystic macular edema (CME) and subretinal fluid were detected in the left eye (Picture 1d). Given these findings, the patient was diagnosed as panuveitis in the left eye and topical prednisolone (12x1) and cyclopentolate hydrochloride (3x1) were prescribed to the patient.

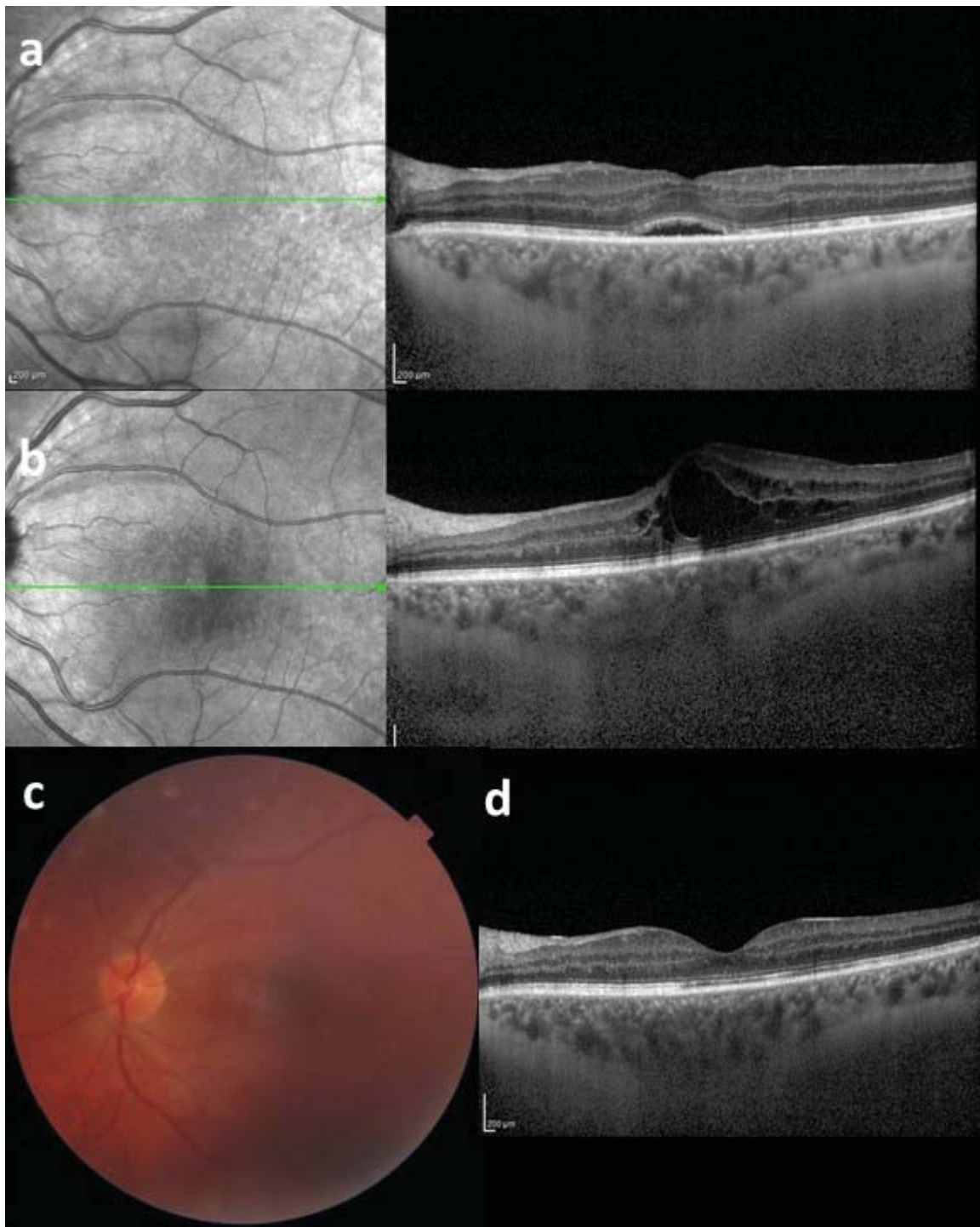
A systemic screening was performed for etiology of panuveitis in the left eye; however, no predisposing finding was detected in the patient. Thus, the patient was assessed by ophthalmology, oncology and rheumatology council regarding systemic diseases, medication and panuveitis in left eye. The council concluded that diarrhea, seronegative polyarthritis and panuveitis in the left eye were due to checkpoint inhibitors (ipilimumab, nivolumab). It was decided to withdraw nivolumab therapy if he was found to be stable and to start systemic prednisolone (48 mg/day). In the control visit on week 2, intravitreal dexamethasone implant was injected to left eye as there was no regression in the findings in ophthalmological examination. In the control visit one month after intravitreal injection, it was found that visual acuity was 0.8 with complete recovery of keratic precipitates and that only posterior synechia was persisted with complete regression in CME and marked regression in subretinal fluid on OCT (Picture 2a). In the control visit at month 4 after intravitreal injection, CME recurrence was detected on OCT (Picture 2b) and a second intravitreal dexamethasone implant was injected. In control visit on week 3 after second injection, it was found that BCVA was 0.9 with more clear visualization of OD and macula on color fundus image (Picture 2c) and normal foveal contour by complete resolution of CME on OCT (Picture 2d). The patient experienced no recurrence during 10-months follow-up.

## DISCUSSION

The checkpoint inhibitors can cause immune-related adverse events in skin, endocrine, metabolic, gastrointestinal, hepatic, immune, renal, respiratory and ocular systems as they act via activation of immune system. Although agent, dose and duration play role in development of adverse events, the organ involved is also important. The onset of adverse events may take a few weeks to months and can persist after withdrawal of drug. It has been reported that adverse event frequency is higher in CTLA4 group agents



**Picture 1:** Left eye, a) color anterior segment image, Tyndall +/++; fine KPs and 210° posterior synechia; b) color fundus image, vitritis +/++, retinal image seemed as unclear; c) fluorescein angiography, diffuse leakage in posterior pole and peripheral retinal vascularity; d) optic coherence tomography (OCT), cystoid macular edema and subretinal fluid



**Picture 2:** Left eye, a) OCT at month 1 after intravitreal dexamethasone implant; CME was resolved minimal subretinal fluid, b) OCT at month 4, CME recurrence, c) color fundus image on week 3 after second intravitreal dexamethasone implant injection; OD and macula can be seen with more details, d) OCT, CME was resolved and normal foveal contour appeared.

and combined therapies.<sup>2,5,9,10</sup> The most common immune-related adverse events include pruritus (1-40), skin swelling (1-43%) and diarrhea (0-40%). The incidence of fatal adverse events is 0.3-1.3%.<sup>7,11,12</sup> The adverse events are generally mild and can be controlled with topical and/or systemic steroid therapy without need for drug withdrawal. Drug withdrawal or cessation can be considered in case

of severe adverse events. In our case, diarrhea and seronegative polyarthritis signs and symptoms were controlled with systemic steroid therapy without need for drug withdrawal.

Ocular adverse events secondary to checkpoint inhibitors are generally immune-related and observed in less than 1%



of patients. Ocular adverse events are more commonly seen with ipilimumab, pembrolizumab and nivolumab. Although most common ocular adverse events include xerophthalmia (1-24%), inflammatory uveitis (generally bilateral, 1%), myasthenia gravis-like ocular involvement, adverse events in ocular, orbital and adnexal structures such as episcleritis, keratitis, neuroretinitis, choroidal neovascular membrane, serous retinal detachment, Vogt-Koyanagi-Harada syndrome-like findings, optic neuropathy, thyroid-associated ophthalmopathy and giant-cell arteritis can also be seen. Topical, periocular, intravitreal or systemic steroid therapies are used in the treatment.<sup>4,-6, 11, 13-19</sup>

Obata et al. reported Vogt-Koyanagi-Harada-like bilateral panuveitis development in a 63-years old patient receiving nivolumab for cutaneous malignant melanoma.<sup>16</sup> The nivolumab therapy was withdrawn due to headache in the patient and only topical steroid therapy was given due to poor general health status preventing use of systemic steroid therapy. Authors reported that granulomatous observed in anterior segment and multiple subretinal fluid areas with fluctating retinal pigment epithelium appearance were resolved on week 3 after initiation of topical steroid therapy and that visual acuity was 1.0 in the right eye and 0.9 in the left eye with normalization of choroidal thickness. Parker et al. reported that corneal ulcer observed in the left eyes of patients on nivolumab due to metastatic malignant melanoma could result from nivolumab use and that successful outcomes were achieved by topical steroid therapy.<sup>17</sup> Sun et al. reported 15 patients with uveitis who were on CTLA4 and PD-1 therapy in 7 centers.<sup>18</sup> Authors reported that there was diagnosis of malignant melanoma in most patients (13/15) and uveitis was developed in 14 patients after initiation of drug therapy (6 patients with anterior uveitis, 6 patients with panuveitis, 1 patient with posterior uveitis, and 1 patient with anterior plus intermedier uveitis) while optic neuritis in one patient. In addition, they reported that uveitis was developed within first 6 months (median: 63 days) after initiation of drugs. In that study, it was emphasized that steroids were effective in majority of patients with permanent loss of vision in 2 patients. In a review by Touhami et al., it was emphasized that masking syndromes, intraocular metastasis and drug-related uveitis presented with similar clinical finding in the association of cancer with intraocular inflammation, which should be taken into consideration in differential diagnosis.<sup>20</sup>

The unilateral panuveitis in our patient occurred approximately 2 years after initiation of nivolumab therapy and involved left eye. Our patient with unilateral panuveitis differed from literature since episcleritis, corneal ulcer and optic neuritis was reported as unilateral but uveitis was reported to be bilateral in the literature.

We aimed to emphasize that systemic disorder can be present in patients with uveitis and there is a need for detailed questioning for medications; in addition, new generation anti-cancer agents may have ocular side effects and that management in collaboration with other disciplines is primary approach in the diagnosis and treatment of the disease.

## REFERENCES

1. Abril-Rodriguez G, Ribas A. SnapShot: Immune Checkpoint Inhibitors. *Cancer cell*. 2017; 31:848.
2. Haanen JB, Robert C. Immune Checkpoint Inhibitors. *Prog Tumor Res*. 2015;42:55-66
3. Tocheva AS, Mor A. Checkpoint Inhibitors: Applications for Autoimmunity. *Curr Allergy Asthma Rep*. 2017; 17:72.
4. Abdel-Rahman O, Oweira H, Petrausch U, et al. Immune-related ocular toxicities in solid tumor patients treated with immune checkpoint inhibitors: a systematic review. *Expert Rev Anticancer Ther*. 2017; 17:387-94.
5. Dalvin LA, Shields CL, Orloff M, et al. Checkpoint inhibitor immune therapy: Systemic Indications and Ophthalmic Side Effects. *Retina*. 2018; 38:1063-78.
6. Antoun J, Titah C, Cochereau I. Ocular and orbital side-effects of checkpoint inhibitors: a review article. *Curr Opin Oncol*. 2016; 28:288-94.
7. Martins F, Sofiya L, Sykiotis GP, et al. Adverse effects of immune-checkpoint inhibitors: epidemiology, management and surveillance. *Nat Rev Clin Oncol*. 2019. 16:563-80
8. Davis JL, Madow B, Cornett J, et al. Scale for photographic grading of vitreous haze in uveitis. *Am J Ophthalmol*. 2010;150:637-41
9. Cully M. Combinations with checkpoint inhibitors at wavefront of cancer immunotherapy. *Nat Rev Drug Discov*. 2015; 14:374-5.
10. Kottschade L, Brys A, Peikert T, et al. A multidisciplinary approach to toxicity management of modern immune checkpoint inhibitors in cancer therapy. *Melanoma Res*. 2016; 26:469-80.
11. Psimaras D. Neuromuscular complications of immune checkpoint inhibitors. *Presse Med*. 2018; 47:253-9.
12. Sood A, Cole D, Abdollah F, et al. Endocrine, Sexual Function, and Infertility Side Effects of Immune Checkpoint Inhibitor *Curr Urol Rep*. 2018; 19:68.
13. Bhatti MT, Salama AKS. Neuro-ophthalmic side effects of molecularly targeted cancer drugs. *Eye* 2018; 32:287-301.
14. Conrady CD, Larochelle M, Pecun P, et al. Checkpoint inhibitor-induced uveitis: a case series. *Graefes Arch Clin Exp Ophthalmol*. 2018; 256:187-91.
15. Makarios D, Horwood K, Coward JIG. Myasthenia gravis: An emerging toxicity of immune checkpoint inhibitors *Eur J Cancer*. 2017; 82:128-36.
16. Obata S, Saishin Y, Teramura K, et al. Vogt-Koyanagi-Harada Disease-Like Uveitis during Nivolumab (Anti-PD-1

- Antibody) Treatment for Metastatic Cutaneous Malignant Melanoma. *Case Rep Ophthalmol.* 2019; 10:67-74.
17. Parker JS, Feagin W, Wang C, et al. Corneal ulceration associated with Nivolumab use. *Am J Ophthalmol Case Rep.* 2019; 14:26-7.
  18. Sun Mm , Levinson R, Filipowicz A, et al. Uveitis in Patients Treated with CTLA-4 and PD-1 Checkpoint Blockade Inhibition. *Ocul Immunol Inflamm.* 2019; 1:1-11.
  19. Thomas M, Armenti ST, Ayres MB, et al. Uveal Effusion After Immune Checkpoint Inhibitor Therapy. *JAMA Ophthalmol.* 2018; 136:553-6.
  20. Touhami S, Audo I, Terrada C, et al. Neoplasia and intraocular inflammation: From masquerade syndromes to immunotherapy-induced uveitis. *Prog Retin Eye Res.* 2019;72:100761.