

# Epiretinal Membrane: Current Data and Treatment Approach

*Dogukan Comerter<sup>1</sup>, Eyup Duzgun<sup>1</sup>*

## ABSTRACT

Epiretinal membrane (ERM) is a common retinal disease characterized by cellular proliferation and metaplasia that lead to the formation of a pathological fibrocellular membrane immediately superjacent to the inner retinal surface. The prevalence of epiretinal membrane (ERM) is 7% to 11.8%, with increasing age being the most important risk factor. Although most ERM is idiopathic, common secondary causes include cataract surgery, retinal vascular disease, uveitis, and retinal tears. The myofibroblastic pre-retinal cells are thought to transdifferentiate from glial and retinal pigment epithelial cells that reach the retinal surface via defects in the internal limiting membrane (ILM) or from the vitreous cavity. Grading schemes have evolved from clinical signs to ocular coherence tomography (OCT) based classification with associated features such as the cotton ball sign. Features predictive of better prognosis include the absence of ectopic inner foveal layers, cystoid macular edema, acquired vitelliform lesions, ellipsoid zone, and cone outer segment termination defects. OCT angiography shows the reduced size of the foveal avascular zone. Vitrectomy with membrane peeling remains the mainstay of treatment for symptomatic ERMs. Additional ILM peeling reduces recurrence but is associated with anatomical changes including inner retinal dimpling

**Keywords:** Epiretinal membrane, Ectopic inner foveal layers, Pars plana vitrectomy, Internal limiting membrane.

## 1. INTRODUCTION

Epiretinal membrane (ERM), previously termed as epimacular membrane, macular pucker, cellophane maculopathy or preretinal macular fibrosis, is a common retinal disorder characterized by formation of pathological fibrocellular membrane just over inner retinal layer as a result of proliferation and metaplasia of myofibroblasts. The recent technological advances enabling retinal imaging have added a new dimension to ERM grading, improving surgical success substantially. In this review, we aim to provide a general definition of ERM as well as up-to-date data about classification and surgical treatment of ERM.

## 2. EPIDEMIOLOGY

Many different risk factors have been identified for the development of ERM, including ethnicity, age, gender, smoking, refractive disorders, diabetes mellitus,

hypertension and hypercholesterolemia. In two large population studies, Blue Mountains Eye Study (BMES)<sup>1</sup> and Beaver Dam Eye Study (BDES)<sup>2</sup>, the prevalence of idiopathic ERM (iERM) was reported as 7.0% and 11.8%, respectively, based on color fundus images with 5-years cumulative incidence of 5.3%. In these studies, it was found that iERM was bilateral in 19.5% and 31% of the cases, respectively. In the BDES study, optical coherence tomography (OCT) was used to detect ERM and prevalence was reported as 34.1%, which was higher than the prevalence found using color fundus images<sup>3</sup>. Advanced age is the most important risk factor for ERM. ERM is diagnosed above 50 years of age in most patients while ERM prevalence reaches peak at seventh decade. Based on previous studies, gender does not seem as an important risk factor. There is no gender preponderance but it may be slightly more common among women. There are great variations in ERM prevalences reported from

1- MD, University of Health Sciences, Sultan Abdülhamid Han Training and Research Hospital, Department of Ophthalmology, Istanbul, Türkiye

2- Assoc. Prof., University of Health Sciences, Sultan Abdülhamid Han Training and Research Hospital, Department of Ophthalmology, Istanbul, Türkiye

**Received:** 12.05.2023

**Accepted:** 12.09.2023

*J Ret-Vit* 2023; 32: 280-291

DOI:10.37845/ret.vit.2023.32.48

**Correspondence Address:**

Dogukan Comerter

University of Health Sciences, Sultan Abdülhamid Han Training and Research Hospital, Department of Ophthalmology, Istanbul, Türkiye

**Phone:** +90 533 712 1270

**E-mail:** dcomerter@hotmail.com

different ethnicities and countries. It is possible that any ethnic difference in ERM prevalence may be due to either genetics or lifestyle variations; however, epidemiological evidence are insufficient to draw a conclusion. No consistent associations have been shown between ERM and refractive disorders with some studies reporting an association between ERM and myopia while others reporting with hypermetropia.<sup>4</sup> Secondary ERM was reported up to 41% in patients with uveitis as being more common in patients with intermediate uveitis, panuveitis and those with posterior involvement.<sup>5</sup> It is known that prevalence of secondary RM is higher in cases with retinal artery or vein occlusions, diabetes, vitreous hemorrhage, retinal detachment and those underwent laser procedures.

### 3. ETIOLOGY AND RISK FACTORS

The ERMs are generally classified based on etiology. The term idiopathic ERM denotes the ERM which occurs without relevant ocular pathology or in the presence of posterior vitreal detachment (PVD) alone. Some others prefer "primary ERM" rather than "idiopathic ERM". The presence of PVD in 78-95% of iERMs suggests that PVD has an important role in the pathophysiology.<sup>6</sup> The term secondary ERM denotes the ERM thought to be related with previous or current ocular disease. In large series, secondary ERM was detected at a rate up to 32.3%.<sup>4</sup> The most common causes include previous cataract surgery, diabetic retinopathy and retinal vein occlusion.<sup>4,7</sup> Table 1 summarizes causes of secondary ERM.

### 4. HISTOPATHOLOGY AND PATHOGENESIS

The ERM formation process includes a series of events leading impairment in normal tissue morphology and function due to fibrotic contractions resulting from substantial production of **extracellular matrix (ECM)**

proteins by myofibroblasts. The ERMs generally consist of two layers covering inner limiting membrane (ILM). The outermost layer overlays on top of ILM and consists of ECM proteins (collagen, fibronectin) containing fibril bundles with random orientation. Overlaying this is a single- or multi-layer or epiretinal cells.<sup>8</sup> Non-cellular ECM forms a primary, structural skeleton which facilitates adhesion and proliferation of epiretinal cells. ECM is synthesized by several cells including glial cells from inner cellular layer of ERM, RPE and myofibroblasts. The major component of ECM is extracellular collagen fibrils containing ILM fragments; it is found that the extracellular collagen fibrils are largely type I, II, III, IV and VI.<sup>9</sup> In iERM, it is considered that differentiation of several precursor cells into myofibroblasts is key pathogenic process. It may be difficult to identify precursor cell types as they drop their characteristic features when they undergo differentiation. Immunohistochemical studies showed that **retinal glial cells, hyalocytes, retinal pigment epithelium (RPE) cells, fibroblasts, myofibroblasts and inflammatory cells (macrophage, lymphocyte, neutrophil)** are often present.<sup>10</sup> In ERM, predominant cell types varies across studies. This may be due to presence of different etiological factors involved in ERM development as well as methodological difference used to identify cell types.

All types of retinal glial cells, including **microglia, Müller cells and astrocytes**, play role in ERM formation. These cells are involved in the development of fibroproliferative structure of ERM and proliferative vitreoretinopathy (PVR) by responding with reactive gliosis against injury.

The cells undergo proliferation, serving as a skeleton for extracellular collagen production an myofibroblast differentiation. In ERM and PVR, they release "TGF-β1" which induces differentiation of epithelial cells into

**Table 1:** Etiological classification of epiretinal membrane

|   |  |
|---|--|
| <p><b>1. Primary or idiopathic ERM</b></p> <ul style="list-style-type: none"> <li>• No pathology other than posterior vitreous detachment (PVD)</li> </ul> <p><b>2. Secondary ERM</b></p> <ul style="list-style-type: none"> <li>• <b>Iatrogenic</b> <ul style="list-style-type: none"> <li>▪ Cataract surgery</li> <li>▪ Vitrectomy</li> <li>▪ Retinopexy</li> </ul> </li> <li>• <b>Retinal vascular diseases</b> <ul style="list-style-type: none"> <li>▪ Diabetic retinopathy</li> <li>▪ Vascular occlusive disorders</li> <li>▪ Coats disease</li> <li>▪ Retinal arterial macro-aneurysm</li> </ul> </li> </ul> | <ul style="list-style-type: none"> <li>• <b>Age-related macular degeneration</b></li> <li>• <b>Retinal tear or detachment</b></li> <li>• <b>Macular hole and vitreomacular traction syndrome</b></li> <li>• <b>Pathological myopia</b></li> <li>• <b>Uveitis</b></li> <li>• <b>Trauma</b></li> <li>• <b>Retinal dystrophy</b></li> <li>• <b>Intraocular tumors</b> <ul style="list-style-type: none"> <li>▪ Retinal capillary hemangioblastoma</li> <li>▪ Vasoproliferative tumors</li> <li>▪ Choroidal melanoma</li> <li>▪ Hamartoma of retinal pigment epithelium</li> </ul> </li> </ul> |
|---|--|

myofibroblasts. The TGF- $\beta$  is the key cytokine playing crucial role in proliferation, myofibroblastic differentiation, fibrosis and apoptosis in ERM.<sup>11</sup> It is suggested that retinal astrocytes serve as a skeleton for collagen production through differentiation into fibroblasts. The Müller cells can be activated by different pathological factors such as mechanical traction, retinal trauma, ischemia or hyperglycemia, and growth factors. The Müller cell differentiation into myofibroblasts and reactive gliosis are significant factors in the formation of fibroproliferative membrane related to PVR, ODR and iERMs. Glial cells undergo mitosis and migrate to retinal surface through ILM cracks, spreading in a single-layer manner over surface of ILM.

**The RPE cells** may access to inner retina through retinal cracks. The RPE cells are the dominant cells in retinal detachment-related PVR and ERM; however, they are typically lacking in iERM or tractional vitreomaculopathy. Although there are studies indicating preponderance of the RPE cells in iERMs, this wasn't supported in additional studies.<sup>12</sup> As similar to glial cells over retinal surface and hyalocytes, the RPE cells may undergo myofibroblastic differentiation via TGF- $\beta$ 2 stimulation. Another possibility is that the retinal cell may transform into pigment epithelium.

**Macrophages** were shown to be present in the iERMs; however, they seem to be more prominent in secondary cases related to vitreous hemorrhage.<sup>13</sup> Macrophages, including microglia, hyalocytes and peripheral monocytes, originates from monocytes. Their role in ERM formation is unknown but it is known that they release cytokines and growth factors contributing myofibroblastic differentiation such as TGF- $\beta$ , insulin-like growth factor and platelet-derived growth factor.

**Hyalocytes** are mononuclear phagocytes embedded into vitreal cortex, which originate from monocytes or macrophages, and are more intensively located at posterior pole and base of vitreous. In vitro studies suggest showed that hyalocytes produce more potent contractile response by TGF- $\beta$ 2 stimulation when compared to remaining epiretinal cells; suggesting that hyalocytes play an important role in the increase of contractility in ERM.<sup>14</sup> It was reported that ERM may develop due to premacular layer retained in posterior vitreal cortex following AVD.<sup>15</sup> Many studies have provided evidence that hyalocytes undergo myofibroblastic differentiation in vitreomacular traction (VMT), lamellar macular hole (LMH) and other proliferative vitreoretinal diseases.<sup>8</sup>

Three main theory have been proposed about how precursor cells initially migrates to inner retinal surface. In classical theory, it is proposed that retinal glial cells migrate to and proliferates at retinal surface through ILM cracks developed after AVD. A similar theory proposes the differentiation of RPE cells which, then, migrate through micro-cracks at ILM and are involved in iERM.<sup>12</sup> In another widely accepted theory, it is proposed that residual hyalocytes at retinal surface following abnormal AVD undergo metaplasia and leads ERM.<sup>16</sup> However, ERM development in the lack of AVD cannot be clearly explained in the theory. Although each theory has its own limitations, there is no consensus in the pathogenesis of ERM.

## 5. CLINICAL FINDINGS AND SYMPTOMS

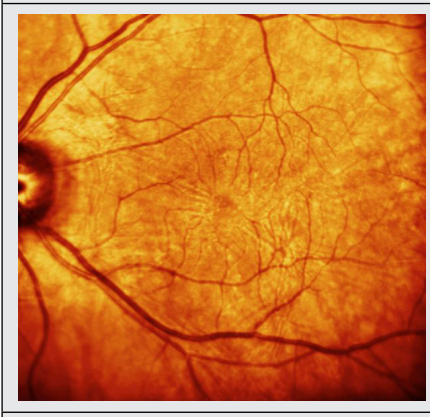
The ERMs are often asymptomatic. There may be various symptoms based on macular location, duration, severity and type of ERM. Visual symptoms may be presented in the involvement of macular or peri-macular region and in the presence of thick membrane leading retinal traction or edema. Common symptoms include decreased visual acuity, blurred vision, metamorphopsia, micropsia, macropsia, loss of depth perception and anisocoria. Another symptoms is need to cover one eye to improve vision despite lack of diplopia or strabismus.<sup>17</sup>

The diagnosis of ERM is made by OCT findings and clinical examination. Early ERMs can be incidentally detected as a reflex at fundus. As ERM advanced, it leads distortion of inner retina and can be seen at various form ranging from superficial radial wrinkle to a form causing the flattening or tortuosity of retinal vascularity. Comorbid AVD may be present up to 95% of ERM eyes.<sup>18</sup> In addition, findings such as ERM-related cystoid macular edema (CME), foveal ectopia, lamellar or full-thickness macular hole and small retinal hemorrhages may also be present concomitantly. Before diagnosis of ERM is established, potential underlying abnormalities such as retinal vascular disorders, uveitis and retinal tear etc. should be carefully assessed. It is also important to examine contralateral eye as the ERM may be bilateral in 10-12% of patients.

## 6. ERM CLASSIFICATION

Gass proposed a classification system to define clinical severity of ERM, which became a reference for ERM (Table 2).<sup>19</sup> However, it is less commonly used after imaging techniques introduced by OCT technology. Several OCT classifications have been proposed for ERM; however, there

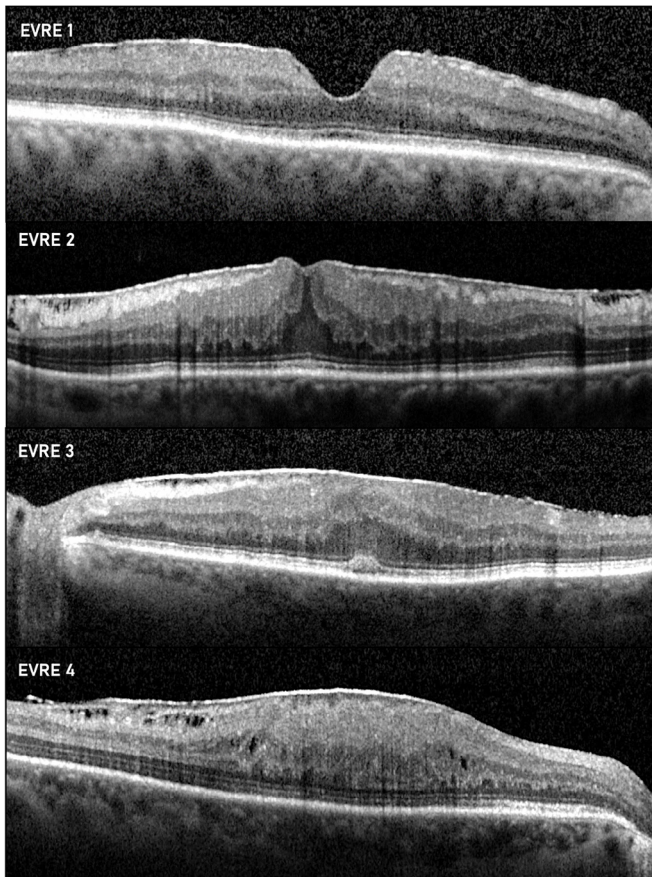
**Table 2:** Different terminologies according to fundoscopic classification and stages by Gass based on colored infrared images

|   |  |
|---|--|
|    | <p>Stage 0</p> <ul style="list-style-type: none"> <li>• Cellophane maculopathy</li> <li>• Early, semi-transparent form of ERM, no retinal abnormality</li> </ul>   |
|   | <p>Stage 1</p> <ul style="list-style-type: none"> <li>• Wrinkled cellophane maculopathy /primary retinal fold</li> <li>• Surface wrinkling maculopathy/retinopathy</li> <li>• Internal limiting membrane wrinkle</li> <li>• Intermediate, semi-transparent form of ERM with retinal impairment.</li> </ul>   |
|  | <p>Stage 2</p> <ul style="list-style-type: none"> <li>• Macular Pucker</li> <li>• Epiretinal pucker/gliosis</li> <li>• Pre-macular/pre-retinal fibrosis</li> <li>• Idiopathic preretinal gliosis</li> <li>• Preretinal connective tissue proliferation</li> <li>• Internal retinal fibrosis/fibroplasia</li> <li>• Late opaque form of ERM with inner retina distortion</li> </ul> |

is no sufficient evidence to suggest superiority of one to other. Many studies defined a morphological grading system involving three grades, normal, mild distortion and severe distortion, when classifying foveal contour abnormality. In these studies, different results were reported, revealing the relationship between postoperative visual acuity and foveal contour. Stevenson et al. proposed a morphological OCT classification based on foveal involvement and the presence or absence of AVD presence.<sup>6</sup> Mathews et al. described a quantitative classification by foveal contour status and ratio of foveal thickness to perifoveal macular retina thickness<sup>20</sup> Kinoshita et al.<sup>21</sup> defined ERM as diffuse type, cystoid macular edema type, pseudolamellar hole type

and vitreomacular traction type by macular contour status. Konidaris et al. developed a 9-category ERM classification schema based on comprehensive categorization of retinal morphology including presence or absence of AVD.<sup>22</sup> However, this is solely anatomical work and descriptive. In recent years, Govetto et al. has proposed a novel, OCT-based, staging scheme which assess presence of ectopic inner foveal layers (EIFL).<sup>(23)</sup> They classified ERMs into 4 stages (Figure 1).

**Stage 1;** early stage where all retinal layers can be described with slight morphological changes; foveal cup is preserved.



**Figure 1:** Govetto et al. with his OCT classification They divided ERMs into four different stages.

**Stage 2;** foveal depression is lost but retinal layers can be identified; there is retinal distortion accompanied by stretch or enlargement of outer nuclear layer.

**Stage 3;** EIFL development throughout central fovea with loss of foveal depression.

**Stage 4;** Marked macula thickening with EIFL and anatomical disruption with retinal disorganization not allowing identification of retinal layers .

## 7. MULTIMODAL IMAGING AND DIAGNOSIS

### A. Optical Coherence Tomography (OCT and ERM-related

OCT is most useful test in the diagnosis of ERM; in addition, it is more sensitive than clinical examination alone. It is also more advantageous than descriptive classification systems as it allows quantitative analysis. By high-resolution OCT, novel definitions are introduced in retinal diseases which can be difficult to distinguish using biomicroscopy.

**Classical ERM** is defined as an irregular, hyper-reflective layer characterized by retinal wrinkles over ILM on retinal

surface and hypo-reflective gaps ILM and retina (Figure 2a).

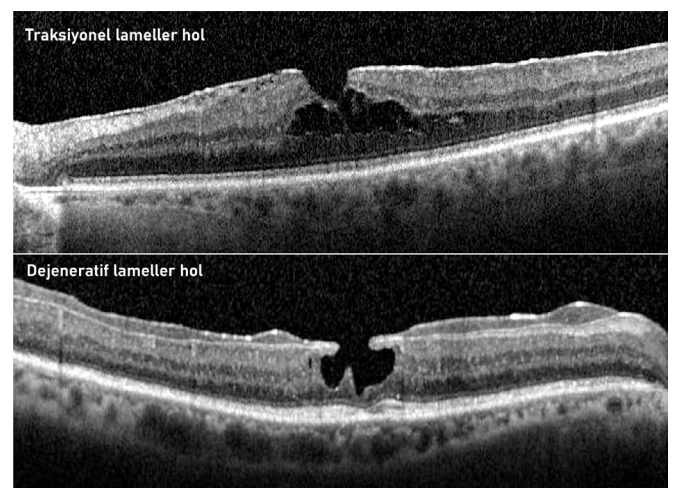
**Epiretinal Proliferation (EP)** is defined as a thick material with homogeneous reflectivity. Occasionally, it appears as a thin, hyper-reflective layer and hypo-reflective gaps between ILM are lacking. EP related to degenerative lamellar macular hole is less contractive characteristic compared to ERM (Figure e2b).<sup>24</sup>

**Lamellar Macular Hole (LMH)** is partial-thickness tissue defect resulting from dehiscence of inner layers from deeper layers due to traction. On OCT, it is diagnosed with certain characteristics including irregular foveal contour, loss of inner foveal tissue, intraretinal detachment, absence of full-thickness foveal defect and intact foveal photoreceptors. On OCT, detachment in the form of cavitation, ellipsoid zone damage and epiretinal proliferation are seen in cases with "degenerative lamellar macular hole" while schisis-like detachment and classical ERM in cases with "tractional lamellar macular hole" (Figure 2).<sup>25</sup>

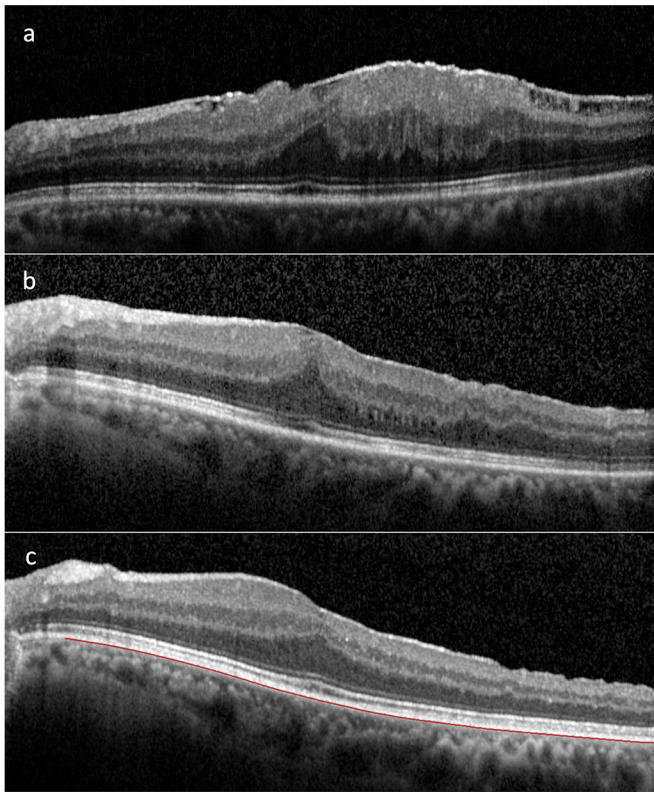
**Pseudohole** is the pseudo-hole appearance caused by well-defined, steep foveal depression related to ERM with central gap. On OCT, central foveal thickness is almost normal and outer retinal layers are intact (Figure 4a).

**Full-thickness macular hole** is an anatomical defect in fovea where all neural retinal layers from ILM to RPE are disrupted.<sup>26</sup>

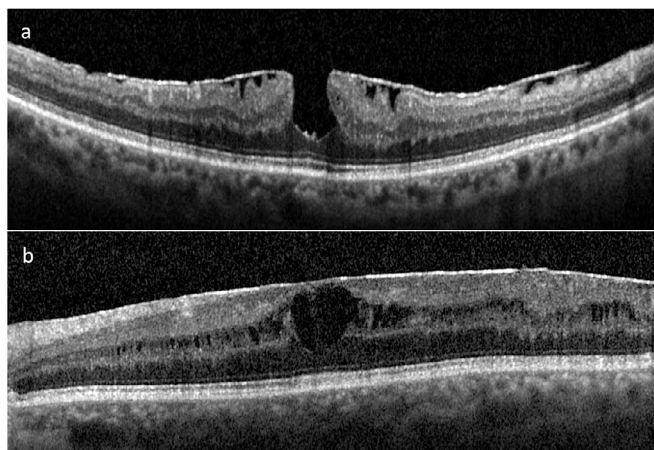
**Foveoschisis** is dehiscence of retinal layer at the level of outer nuclear layer (ONL) and outer plexiform layer (OPL) due to traction (Figure 4b). In the presence of contractile ERM, the foveoschisis at the level of Henle layer is defined as ERM-derived foveoschisis.



**Figure 2:** The lamellar holes are divided into two groups: Tractional and Degenerative lamellar holes.



**Figure 3:** This picture shows a stage 3 ERM. A decrease in retinal thickness is observed at 1 month and 1 year after ERM peeling. Also, recurrent ERM is seen in the late stage.

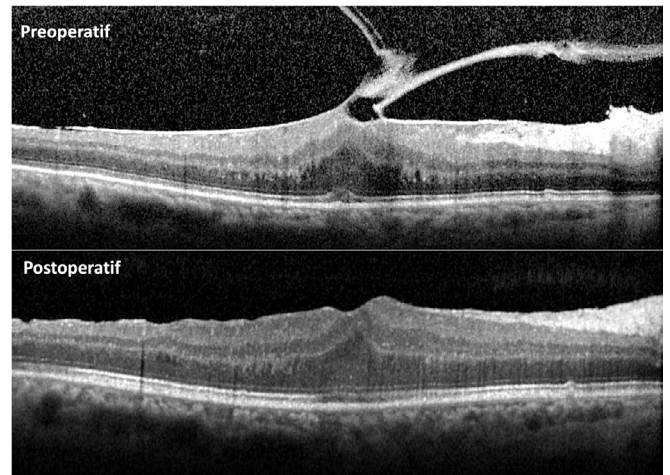


**Figure 4:** Pseudohole and foveaschisis are observed in a case with ERM.

**Vitreomacular traction syndrome (VMTS)** is a disorder of vitreoretinal interface characterized by incomplete posterior vitreous detachment which leads, in part, dehiscence between vitreous and retina and morphological changes via traction on retinal surface; thus, resultant visual dysfunction (Figure 5).

**Ectopic Inner Foveal Layers**

EIFL is defined as a hypo- or hyper-reflective band extending from inner nuclear layer (NL) to inner



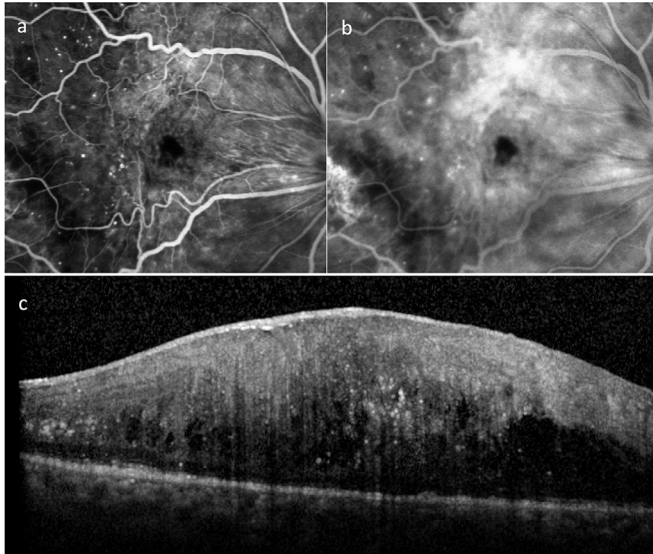
**Figure 5:** Preoperative and postoperative OCT images are shown in a case with ERM and VMTS.

plexiform layer (IPL) along with fovea. It is thought that EIFL develops as a result of damaged retina due to gliosis and Müller cell proliferation caused by tractional forces induced by ERM. Govetta et al.<sup>23</sup> first described an OCT-based ERM classification system involving 4 stages according to lack of foveal pit, presence of EIFL and irregularity of retinal layers on OCT (Figure 1). Based on this classification system, advanced ERMs are associated with decreased visual acuity, higher CMT, increased CME prevalence, ellipsoid zone (EZ) disruption and decreased fovea avascular zone (FAZ) size. In many studies using this staging system as reference, it was shown that visual prognosis and metamorphopsia were associated to presence and thickness of EIFL. (27) Mavi Yildiz et al.<sup>28</sup> investigated correlation between pre- and post-operative EIFL and visual acuity on 147 ERM patients and reported that stage 3 and 4 ERMs were associated with worst visual outcomes. In a study including 216 eyes with iERM, Yang et al. found that presence of EIFL was an unfavorable factor for preoperative vision disorder and postoperative anatomical improvement but a minor factor for postoperative visual acuity.<sup>29</sup>

**Cotton Ball Sign and Central Bouquet**

Cotton ball sign is defined as a round, diffuse hyper-reflective area between EZ and cone outer segment tips (COST) line at central fovea.<sup>30</sup> It was found that mean CMT was higher in eyes with cotton ball sign than those without. Authors suggested that chronic traction and cotton wool sign might be correlated with severity of ERM.

Based on cotton ball sign, Govetto et al. suggested that an areas (100 µm in diameter), termed as central bouquet, is most sensitive region to tractional injury in ERM.



**Figure 6:** In the early stages of FFA, vascular tortuosity becomes clearly visible (a) Vascular leakage increases in the late stages. (b) Also, many hyperreflective foci are observed within the retina. (c)

It is proposed that central bouquet abnormalities lead transduction of mechanical force to Müller cells via Müller cells and manifest in three distinct forms, namely "**cotton ball sign, foveolar detachment or acquired vitelliform lesions**", on OCT. Tractional pathology was detected in 58 of 263 eyes with ERM with most being cotton ball sign (62%). It was found that visual acuity was better in the presence of cotton ball sign while it was worse in the presence of acquired vitelliform lesions. In a smaller series, it was reported that central bouquet abnormalities were drastically disappeared after surgery with no adverse effect on visual prognosis.<sup>31</sup> Although no ERM classification system including these findings has been developed yet, it is thought that they play role important in ERM.

### **Prognostic Markers on OCT**

Although pars plana vitrectomy (PPV) plus membranectomy is considered as primary treatment for ERM, timing of surgery is controversial. Many studies have been performed to identify OCT biomarkers in order to assess EZ and outer photoreceptor segments, ganglion cell layer-inner plexiform layer (GCL-IPL) and choroidal thickness.<sup>32</sup> It is advocated that these biomarkers should be integrated ERM classification systems by demonstrating their relationship with visual acuity.

In a systematic review by Miguel and Legris,<sup>33</sup> various factors were demonstrated about visual gain following ERM surgery. The OCT biomarkers indicating better visual outcomes include:<sup>33</sup>

- **Presence of preoperative thinner CMT,**
- **No EIFL on OCT,**
- **No irregular inner retinal layers,**
- **No CME or acquired vitelliform lesions,**
- **Preserved photoreceptor outer segment length and EZ and COSTS integrity,**
- **Thinner GCL-IPL** was considered as predictors for better prognosis.
- **Increased inner nuclear layer thickness and central foveal thickness** were linked to metamorphopsia.

Several studies have emphasized the importance of outer retinal layers, particularly integrity of EZ and COST line, in the prediction of postoperative visual acuity (VA).<sup>34</sup> However, the presence of traction at inner retinal layers has indicated that assessment of outer retinal layers alone is inadequate in prediction of postoperative prognosis. The area and depth of traction is positively correlated with severity of intraretinal changes while negatively correlated with visual acuity. In different studies including patients underwent surgery for ERM, it was shown that the presence and thickness of preoperative EIFL were associated with markedly poorer prognosis when compared to control groups without EIFL.<sup>35</sup> These studies indicate that optimal timing for surgery is before development of EIFL. In addition, Okamoto et al. reported that higher INL thickness showed better correlation with preoperative and postoperative metamorphopsia in iERM.<sup>36</sup> Although higher GCL-IPL thickness is associated to poorer surgical outcomes, postoperative thinning of GCL-IPL is associated to decreased visual acuity. This may be due to iatrogenic damage caused by ERM traction and/or ERM peeling. In 2016, Cho et al.<sup>37</sup> proposed an "inner retinal irregularity index" as measured by ratio of IPL length to RPE in a fovea-centered circular area (3 mm in diameter). This ratio can be calculated more readily than measurement of GCL-IPL thickness. It was found that inner retinal irregularity index was significantly correlated with VA at baseline and on postoperative month 6.

### **B. Fundus Autofluorescence**

Fundus autofluorescence may show irregular hypo-autofluorescent area at macula, increased tortuosity of retinal vascularity or presence of acquired vitelliform lesion. (38) It can be helpful to detect foveal displacement following ERM surgery and macular hole surgery.<sup>39</sup>

### C. Angiography: Fluorescein and OCT Angiography

Fundus fluorescein angiography (FFA) or OCT angiography (OCTA) can be used to define comorbid retinal vascular disorders, retinal vasculitis, age-related macular degeneration or tumors in ERM before surgery. The ERMs may alter macular micro-vascularity or lead vascular damage by exerting tangential and anteroposterior forces over retina. The OCTA analysis of ERM showed FAZ narrowing or loss due to stretch and displacement of vessels in both superficial capillary plexus (SSCP) and deep capillary plexus (DCP).<sup>28</sup> In addition, foveal vascular density was increased while parafoveal vascular density was significantly increased when compared to healthy eyes.<sup>40</sup> A decrease in vascular density was decreased in SCP while parafoveal vascular density was increased following ERM peeling.<sup>41</sup>

### D. Microperimetry

Microperimetry allows assessment of dysfunction which cannot be detected in VA or visual field but may explain visual disorder reported by ERM patients. In microperimetry, decreased mean retinal sensitivity is associated to ONL thickening due to ERM. Preferential hyperacuity perimetry (PHP) is a distinct psychophysical perimeter testing used to detect and measure visual abnormalities including metamorphopsia and scotoma. M-charts can also be used for quantitative assessment of metamorphopsia. It was reported that postoperative improvements in metamorphopsia as measured by PHP were correlated to postoperative improvements in VA and CMT. (42) However, in some studies, it was reported that ILM peeling might lead reduction in retinal sensitivity and micro-scotoma at region where ILM was engaged by the forceps.<sup>43</sup>

### E. Electroretinography (ERG)

In ERMs, a decrease was shown in multi-focal electroretinography (mfERG) responses at both fovea and perifovea. Low responses (particularly P1 amplitude density in central ring) are associated to foveal thickness and best-corrected visual acuity. although, double peeling in ERM surgery is linked to micro-scotoma on microperimetry, it was shown to be improve ERG responses. In mfERG, delayed P1 implicit time is an important predictor for poorer recovery in vision after ERM surgery.<sup>44</sup> However, mfERG isn't routinely used in many clinics due to limited access and longer test duration. In a study using mfERG Hwang et al.<sup>45</sup> reported that ERMs with foveal adhesion and inner retinal thickening significantly impaired retinal function when compared to those not involving fovea.

## 8. TREATMENT AND APPROACH

### A. Conservative Approach

ERM is a chronic, slowly progressing disease not requiring emergent intervention. Available treatment modalities include close follow-up or surgery. The dilemma faced when employing conservative approach is the risk for progression and decrease in likelihood of therapeutic benefit in advanced ERM patients with no or minor symptoms. The ERM progression must be followed by assessing retinal morphology and functional vision.

### Anatomical Features and Progression in ERM

In BMES study in which ERM eyes were followed over 5 years using color fundus images, it was reported that there was no progression in majority of eyes and ERM was regressed or recovered in one-fourth, with progression from cellophane maculopathy to preretinal fibrosis in only 10% of eyes. ERM can lead LMH due to traction over retina. LMH development is generally translated as stability due to reduced tangential forces over retina. ERMs do not require surgery in most cases unless VA reduction and progressive retinal thickening are present.

Byon et al.<sup>46</sup> classified iERMs in 62 eyes with minimum follow-up of 24 months and VA 20/40 into two categories as total and partial macular involvement. Authors found that 11 of 33 eyes (33% progressed from total macular involvement to partial involvement. In addition, it was seen that vitreoretinal attachment affected iERM progression. Progression and VA loss was observed in 4 of 10 eyes (40%) without AVD at presentation and in only 2 of 52 eyes (3.8%) with AVD at presentation. It was proposed that the progression observed in eyes with vitreomacular and vitreopapillary adhesion may be secondary to increased pro-inflammatory factors.

In another study by Lee et al.,<sup>47</sup> it was reported that there was visual acuity loss of  $\geq 2$  letters in 15 of 112 patients (13%) with VA > 20/40 during mean follow-up of 31 months. When iERM patients with worse progression, changes in ERM configuration was noted from total macular involvement towards partial involvement. These results showed that iERM starts with total macular involvement; followed by gradual progression to unstable partial involvement. In addition, authors measured the disc-fovea vascularity (DFV) length to assess tangential traction in iERM patients and found that DFV length was decreased in 15 patients with vision loss.

In summary, morphological progression is anticipated in 17-39% of iERM cases followed minimum 24 months.



Rapid progression and need for surgery are less likely in asymptomatic eyes with good vision ( $\geq 20/40$ ). The factors predicting anatomical progression include total macular involvement by ERM, no AVD at presentation, decreased DFV length during follow-up and early stages without EIFL. There is a consensus that the cases with above-mentioned findings will show progression.

### Functional Progression in ERM

The functional progression of ERM is generally assessed by visual acuity. In a previous study, it was reported that visual acuity remained unchanged over 24 months follow-up despite anatomical changes in one-third of patients with iERM. It was reported that VA was decreased in 10% during follow-up while it was improved in 7% of patients due to spontaneous resolution of iERM. The factors associated with rapid visual deterioration include presence of metamorphopsia and cysts in INL at baseline and lamellar hole formation.<sup>48</sup>

### B. Medical Approach

Currently, there is no available medical treatment effective in ERM, although macular edema in secondary ERMs (diabetic retinopathy, retinal vein occlusion, uveitis) can respond to intravitreal anti-VGEF agents, steroids or non-steroidal anti-inflammatory agents. Vitreopharmacolysis investigates benefits of biological enzymes in resolution of ERM. Intravitreal ocriplasmin was studied in ERM-related VMT; however, no data was provided regarding membrane degradation.<sup>49</sup> No significant effect was observed when ocriplasmin was used in ERM subjects with VMT.

### C. Surgical Approach

In ERM, surgery is generally performed in the presence of vision loss or symptoms affecting daily living activities. To prevent irreversible damage, optimal timing for surgery remains to be unclear; however, recent studies concluded that surgery should be performed before onset of EIFL on OCT imaging. In surgery, the goal is to remove membrane and eliminate retinal traction. Given the cell proliferation function of ILM, ERM/ILM double peeling has become a widely adopted procedure. The ILM peeling allows more complete ERM removal, decreasing need for re-operation. However, it was seen that ILM peeling was associated with substantial number of micro-scotoma and did not improve VA outcomes. Thus, some authors recommended double only in cases with recurrent ERM.<sup>50, 51</sup> Some surgeons routinely prefer phacoemulsification plus vitrectomy as it abolishes need for a second surgery for cataract in the

future and has favorable cost-effectiveness and safety profile.<sup>52</sup>

Suture-free, transconjunctival 3-port pars plana Micro-incision (23-, 25- or 27-gauge) Vitrectomy Surgery (MIVS) is the standard procedure for ERM peeling. Many studies reported no surgical superiority for certain gauge for vitrectomy; however, some studies suggested early improvement in VA and more effective CMT reduction in surgeries performed using 27 gauge when compared to those performed using 25 gauge.<sup>53</sup>

### ILM Peeling During Surgery

Typically, iERM is strongly adhered to ILM. In patients underwent ERM peeling alone, ILM fragments at varying degrees were observed in vitreous specimens isolated during vitrectomy. Park et al.<sup>54</sup> published a case series including patients underwent double peeling and those underwent ERM peeling alone. Authors concluded that ILM peeling was not associated with harmful effects with decrease in recurrence rate. However, many randomized-controlled meta-analyses showed no significant benefit on visual acuity with ILM peeling. In a controlled study by Tranos et al.<sup>55</sup> no significant improvement was shown in metamorphopsia in patients underwent double peeling. In meta-analyses, only consistent result is that ILM peeling decreases ERM recurrence. Somewhat Müller cell dysfunction can be expected as Müller cell fragments at varying amounts are also removed during ILM peeling.<sup>56</sup> Based on damage induced, foveal thickness was increased while FAZ area was narrowed.<sup>41</sup> In addition, a characteristic appearance resembling dissociated optic nerve fiber layer (DONFL) can be detected due to swelling of arcuate nerve fiber layer in eyes underwent ILM.

In summary, available evidence showed that ILM peeling during iERM surgery has no positive effect on final visual acuity and metamorphopsia. However, recurrence rate is lower in eyes underwent ILM peeling. In most cases, en bloc ILM peeling occurs spontaneously during ERM peeling and the question whether additional ILM peeling will be performed isn't taken into account. However, attempting to peel ILM in cases where ERM is readily removed with clear and regular ILM surface confers risk for retinal trauma.

Secondary iERMs generally occur in younger patients. Surgical removal of secondary ERM has no difference but underlying etiology should be taken into account in order to prevent recurrence. They tend to have worse postoperative VA due to frequent occurrence of optic disc

and extra-macular involvement. Postoperative visual gain is better when compared to iERMs.

In addition, intraoperative OCT-guided ERM surgery minimizes unnecessary maneuvers, decreases rate of residual ERM and allows better assessment of retinal architecture. In addition, head-up glasses providing 3-D imaging and robotic surgery may contribute ERM surgery.

#### D. Surgical Complications and Postoperative OCT Changes

In vitrectomy surgery, general complications include cataract, endophthalmitis, hemorrhage, hypotonia and retinal detachment.<sup>57</sup> In addition, postoperative OCT imaging provides information about retinal damage induced by ERM/ILM double peeling. "**Arcuate Nerve Fiber Layer Swelling**" is the earliest postoperative change seen on OCT. It is linked to direct surgical trauma on RNFL due to ILM peeling or Müller cell end-plate injury.<sup>58</sup> It may persist up to 3 months and hyper-reflective bulginess of RNFL in papillomacular bundle appears as hypo-reflective on infrared imaging and hypo-autofluorescent.<sup>59</sup> Almost one-half of patients underwent ERM exhibits dark, curved striate which can be seen along with RNFL with blue light filter. This layer was first described as "**Dissociated Optic Nerve Fiber Layer**" (DONFL) by Tadayoni et al.,<sup>60</sup> which was subsequently termed as "**Inner Retinal Dimpling**" by Spaide.<sup>61</sup> Inner retinal dimpling is best visualized on en face OCT images. It is thought that the layer may be due to regeneration of traumatized Müller cells as well as it may represent successful peeling.<sup>59</sup>

Although **Microcystic Macular Edema** is more commonly seen after ERM/ILM double peeling, it may also be observed before surgery. It most frequently effect nasal quadrant with thickened INL and thinned GCL. It is linked to poorer visual outcome when presents in central and temporal quadrants in particular. It has been proposed that microcystic macular edema may develop as retrograde maculopathy as result of impaired in water-pump function of Müller cells due to ganglion cell loss.<sup>62</sup> On OCT, **foveal displacement towards optic disc** after surgery ERM presumably occurs due to imbalance between nasal and temporal biomechanical forces after release of ERM traction. Retinal stretching and thinning generally occurs at temporal to fovea. **Full-thickness paracentral macular holes** are rare; however, it is more likely after combined ERM/ILM removal. It is thought that MHs are iatrogenic as they originate from peeling area or at the edge of peeled ILM. They are generally asymptomatic and have good prognosis not requiring treatment unless they are close to fovea.<sup>63</sup>

#### E. Visual Outcomes After Surgery

In ERM cases, vitreoretinal surgery is a safe and effective procedure with good visual outcomes. Patients with better VA at baseline have better postoperative VA; however, the extent of postoperative visual gain is greater in patients with poorer preoperative VA.<sup>64</sup> It was reported that postoperative VA is similar in patients underwent single or double membran peeling with mean 2 lines of improvement in VA. It is known that metamorphopsia was recovered in many patients without improvement in VA.<sup>65</sup> Postoperative OCT imaging revealed findings suggestive of improvement in retinal micro-structure such as gradual restoration of foveal structures, recovery of epiretinal contour and partial restoration of outer retinal configuration. (Figure 3). It was found that VA can continue to improve up to 3 years following resolution of intraretinal edema and restoration of retina after surgery.<sup>66</sup>

#### 9. CONCLUSION

Current histopathological studies and advances in imaging techniques enable us to better understand ERM pathology. In recent studies, significant decrease in VA, metamorphopsia and lack of anisocoria were taken as reference when considering surgery in ERM patients. Current classification using OCT and careful assessment of prognostic factors on OCT can provide valuable information on ERM progression, surgical timing and postoperative visual gain. Although it was reported that visual outcomes are better when baseline visual acuity is higher, it is known that the extent of visual gain is greater in patients with poorer baseline vision. There is no consensus on optimal timing of surgery. AI systems integrated into OCT devices have potential to help identifying patients who will have benefit from surgery by automatic assessment of prognostic factors for each patient. Based on these data, surgical indication relies on clinician's judgment and subjective symptoms of a patient.

#### REFERENCES

1. Mitchell P, Smith W, Chey T, et al. Prevalence and associations of epiretinal membranes. The Blue Mountains Eye Study, Australia. *Ophthalmology*. 1997;104:1033-40.
2. Klein R, Klein BE, Wang Q, et al. The epidemiology of epiretinal membranes. *Trans Am Ophthalmol Soc*. 1994;92:403-25; discussion 25-30.
3. Xiao W, Chen X, Yan W, et al. Prevalence and risk factors of epiretinal membranes: a systematic review and meta-analysis of population-based studies. *BMJ Open*. 2017;7:e014644.
4. Kawasaki R, Wang JJ, Mitchell P, et al. Racial difference in the prevalence of epiretinal membrane between Caucasians and Asians. *Br J Ophthalmol*. 2008;92:1320-4.

5. Nicholson BP, Zhou M, Rostamizadeh M, et al. Epidemiology of epiretinal membrane in a large cohort of patients with uveitis. *Ophthalmology*. 2014;121:2393-8.
6. Stevenson W, Prospero Ponce CM, Agarwal DR, et al. Epiretinal membrane: optical coherence tomography-based diagnosis and classification. *Clin Ophthalmol*. 2016;10:527-34.
7. Fong CS, Mitchell P, Rohtchina E, et al. Incidence and progression of epiretinal membranes in eyes after cataract surgery. *Am J Ophthalmol*. 2013;156:312-8.e1.
8. Kohno RI, Hata Y, Kawahara S, et al. Possible contribution of hyalocytes to idiopathic epiretinal membrane formation and its contraction. *Br J Ophthalmol*. 2009;93:1020-6.
9. Kritzenberger M, Junglas B, Framme C, et al. Different collagen types define two types of idiopathic epiretinal membranes. *Histopathology*. 2011;58:953-65.
10. Joshi M, Agrawal S, Christoforidis JB. Inflammatory Mechanisms of Idiopathic Epiretinal Membrane Formation. Mediators of Inflammation. 2013;2013:192582.
11. Bu S-C, Kuijter R, van der Worp RJ, et al. Immunohistochemical Evaluation of Idiopathic Epiretinal Membranes and In Vitro Studies on the Effect of TGF- $\beta$  on Müller Cells. *Investigative Ophthalmology & Visual Science*. 2015;56:6506-14.
12. Smiddy WE, Maguire AM, Green WR, et al. Idiopathic epiretinal membranes. Ultrastructural characteristics and clinicopathologic correlation. *Ophthalmology*. 1989;96:811-20; discussion 21.
13. Bringmann A, Wiedemann P. Involvement of Müller glial cells in epiretinal membrane formation. *Graefes Arch Clin Exp Ophthalmol*. 2009;247:865-83.
14. Hirayama K, Hata Y, Noda Y, et al. The involvement of the rho-kinase pathway and its regulation in cytokine-induced collagen gel contraction by hyalocytes. *Invest Ophthalmol Vis Sci*. 2004;45:3896-903.
15. Kishi S, Shimizu K. Oval defect in detached posterior hyaloid membrane in idiopathic preretinal macular fibrosis. *Am J Ophthalmol*. 1994;118:451-6.
16. Sebag J. [The vitreoretinal interface and its role in the pathogenesis of vitreomaculopathies]. *Ophthalmologie*. 2015;112:10-9.
17. Hatt SR, Leske DA, Iezzi R, Jr., et al. Binocular Interference vs Diplopia in Patients With Epiretinal Membrane. *JAMA Ophthalmol*. 2020;138:1121-7.
18. Bu SC, Kuijter R, Li XR, et al. Idiopathic epiretinal membrane. *Retina*. 2014;34:2317-35.
19. Gass J. *Stereoscopic Atlas of Macular Disease: Diagnosis and Treatment*. 3th edition ed. St. Louis, Mosby.; 1987. 693-5.
20. Mathews NR, Tarima S, Kim D-G, et al. Foveal Contour Changes Following Surgery for Idiopathic Epiretinal Membrane. *Investigative Ophthalmology & Visual Science*. 2014;55:7754-60.
21. Kinoshita T, Kovacs KD, Wagley S, et al. Morphologic Differences in Epiretinal Membranes on Ocular Coherence Tomography as a Predictive Factor for Surgical Outcome. *Retina*. 2011;31:1692-8.
22. Konidaris V, Androudi S, Alexandridis A, et al. Optical coherence tomography-guided classification of epiretinal membranes. *Int Ophthalmol*. 2015;35:495-501.
23. Govetto A, Lalane RA, Sarraf D, et al. Insights Into Epiretinal Membranes: Presence of Ectopic Inner Foveal Layers and a New Optical Coherence Tomography Staging Scheme. *Am J Ophthalmol*. 2017;175:99-113.
24. Hubschman JP, Govetto A, Spaide RF, et al. Optical coherence tomography-based consensus definition for lamellar macular hole. *Br J Ophthalmol*. 2020;104(12):1741-7.
25. Govetto A, Dacquay Y, Farajzadeh M, et al. Lamellar Macular Hole: Two Distinct Clinical Entities? *Am J Ophthalmol*. 2016;164:99-109.
26. Un Y, Öztürk M, Elçioğlu M, et al. İdiopatik makula deliği cerrahisi sonuçlarımız. *Retina-Vitreus*. 2010;18:129-33.
27. Alkabes M, Fogagnolo P, Vujosevic S, et al. Correlation between new OCT parameters and metamorphopsia in advanced stages of epiretinal membranes. *Acta Ophthalmol*. 2020;98:780-6.
28. Mavi Yildiz A, Avci R, Yilmaz S. The predictive value of ectopic inner retinal layer staging scheme for idiopathic epiretinal membrane: surgical results at 12 months. *Eye (Lond)*. 2021;35:2164-72.
29. Yang X, Wang Z, Yu Y, et al. Effects of Ectopic Inner Foveal Layers on Foveal Configuration and Visual Function After Idiopathic Epiretinal Membrane Surgery. *Retina*. 2022;42:1472-8.
30. Tsunoda K, Watanabe K, Akiyama K, et al. Highly reflective foveal region in optical coherence tomography in eyes with vitreomacular traction or epiretinal membrane. *Ophthalmology*. 2012;119:581-7.
31. Ortoli M, Blanco-Garavito R, Blautain B, et al. Prognostic factors of idiopathic epiretinal membrane surgery and evolution of alterations of the central cone bouquet. *Graefes Archive for Clinical and Experimental Ophthalmology*. 2021;259:2139-47.
32. Watanabe K, Tsunoda K, Mizuno Y, et al. Outer retinal morphology and visual function in patients with idiopathic epiretinal membrane. *JAMA Ophthalmol*. 2013;131:172-7.
33. Miguel AI, Legris A. Prognostic factors of epiretinal membranes: A systematic review. *J Fr Ophthalmol*. 2017;40:61-79.
34. Shimozone M, Oishi A, Hata M, et al. The significance of cone outer segment tips as a prognostic factor in epiretinal membrane surgery. *Am J Ophthalmol*. 2012;153:698-704.
35. González-Saldivar G, Berger A, Wong D, et al. Ectopic Inner Foveal Layer Classification Scheme Predicts Visual Outcomes After Epiretinal Membrane Surgery. *Retina*. 2020;40:710-7.

36. Okamoto F, Sugiura Y, Okamoto Y, et al. Inner Nuclear Layer Thickness as a Prognostic Factor for Metamorphopsia After Epiretinal Membrane Surgery. *Retina*. 2015;35:2107-14.
37. Cho KH, Park SJ, Cho JH, et al. Inner-Retinal Irregularity Index Predicts Postoperative Visual Prognosis in Idiopathic Epiretinal Membrane. *Am J Ophthalmol*. 2016;168:139-49.
38. Gomes NL, Corcostegui I, Fine HF, et al. Subfoveal pigment changes in patients with longstanding epiretinal membranes. *Am J Ophthalmol*. 2009;147:865-8.
39. Rodrigues IA, Lee EJ, Williamson TH. Measurement of Retinal Displacement and Metamorphopsia After Epiretinal Membrane or Macular Hole Surgery. *Retina*. 2016;36:695-702.
40. Chen H, Chi W, Cai X, et al. Macular microvasculature features before and after vitrectomy in idiopathic macular epiretinal membrane: an OCT angiography analysis. *Eye (Lond)*. 2019;33:619-28.
41. Kumagai K, Furukawa M, Suetsugu T, et al. Foveal Avascular Zone Area Internal Limiting Membrane Peeling for Epiretinal Membrane and Macular Hole Compared with that of Fellow Eyes and Healthy Controls. *Retina*. 2018;38:1786-94.
42. Bae SH, Kim D, Park TK, et al. Preferential hyperacuity perimeter and prognostic factors for metamorphopsia after idiopathic epiretinal membrane surgery. *Am J Ophthalmol*. 2013;155:109-17.e3.
43. Deltour JB, Grimbert P, Masse H, et al. Detrimental Effects of Active Internal Limiting Membrane Peeling During Epiretinal Membrane Surgery: Microperimetric Analysis. *Retina*. 2017;37:544-52.
44. Kim JH, Kim YM, Chung EJ, et al. Structural and functional predictors of visual outcome of epiretinal membrane surgery. *Am J Ophthalmol*. 2012;153:103-10.e1.
45. Hwang JU, Sohn J, Moon BG, et al. Assessment of macular function for idiopathic epiretinal membranes classified by spectral-domain optical coherence tomography. *Invest Ophthalmol Vis Sci*. 2012;53:3562-9.
46. Byon IS, Pak GY, Kwon HJ, et al. Natural History of Idiopathic Epiretinal Membrane in Eyes with Good Vision Assessed by Spectral-Domain Optical Coherence Tomography. *Ophthalmologica*. 2015;234:91-100.
47. Lee YJ, Yoo YJ, Han SB. Age-related Changes of Macular Ganglion Cell-inner Plexiform Layer Thickness in Korean Elderly Subjects. *Korean J Ophthalmol*. 2020;34:404-12.
48. Luu KY, Koenigsaecker T, Yazdanyar A, et al. Long-term natural history of idiopathic epiretinal membranes with good visual acuity. *Eye (Lond)*. 2019;33:714-23.
49. Folk JC, Adelman RA, Flaxel CJ, et al. Idiopathic Epiretinal Membrane and Vitreomacular Traction Preferred Practice Pattern(®) Guidelines. *Ophthalmology*. 2016;123:P152-81.
50. Schechet SA, DeVience E, Thompson JT. The Effect of Internal Limiting Membrane Peeling on Idiopathic Epiretinal Membrane Surgery, with a Review of the Literature. *Retina*. 2017;37:873-80.
51. Jung JJ, Hoang QV, Ridley-Lane ML, et al. Long-Term Retrospective Analysis of Visual Acuity and Optical Coherence Topographic Changes After Single Versus Double Peeling During Vitrectomy for Macular Epiretinal Membranes. *Retina*. 2016;36:2101-9.
52. Fajgenbaum MAP, Neffendorf JE, Wong RS, et al. Intraoperative and Postoperative Complications in Phacovitrectomy for Epiretinal Membrane and Macular Hole: A Clinical Audit of 1,000 Consecutive Eyes. *Retina*. 2018;38(9):1865-72.
53. Naruse S, Shimada H, Mori R. 27-gauge and 25-gauge vitrectomy day surgery for idiopathic epiretinal membrane. *BMC Ophthalmol*. 2017;17:188.
54. Park DW, Dugel PU, Garda J, et al. Macular pucker removal with and without internal limiting membrane peeling: pilot study. *Ophthalmology*. 2003;110:62-4.
55. Tranos P, Koukoura S, Charteris DG, et al. The role of internal limiting membrane peeling in epiretinal membrane surgery: a randomised controlled trial. *Br J Ophthalmol*. 2017;101:719-24.
56. Díaz-Valverde A, Wu L. To Peel or not to Peel the Internal Limiting Membrane in Idiopathic Epiretinal Membranes. *Retina*. 2018;38 Suppl 1:S5-s11.
57. Fabian ID, Moisseiev J. Sutureless vitrectomy: evolution and current practices. *Br J Ophthalmol*. 2011;95:318-24.
58. Scupola A, Grimaldi G, Abed E, et al. Arcuate Nerve Fiber Layer Changes After Internal Limiting Membrane Peeling in Idiopathic Epiretinal Membrane. *Retina*. 2018;38:1777-85.
59. Pichi F, Lembo A, Morara M, et al. Early and late inner retinal changes after inner limiting membrane peeling. *Int Ophthalmol*. 2014;34:437-46.
60. Tadayoni R, Paques M, Massin P, et al. Dissociated optic nerve fiber layer appearance of the fundus after idiopathic epiretinal membrane removal. *Ophthalmology*. 2001;108:2279-83.
61. Spaide RF. "Dissociated optic nerve fiber layer appearance" after internal limiting membrane removal is inner retinal dimpling. *Retina*. 2012;32:1719-26.
62. Hsieh MH, Chou YB, Huang YM, et al. Inner Nuclear Layer Microcyst Configuration, Distribution, and Visual Prognosis in Patients With Epiretinal Membrane After Vitrectomy and Membrane Peeling. *Sci Rep*. 2019;9:11570.
63. Sandali O, El Sanharawi M, Basli E, et al. Paracentral retinal holes occurring after macular surgery: incidence, clinical features, and evolution. *Graefes Arch Clin Exp Ophthalmol*. 2012;50:1137-42.
64. Dawson SR, Shunmugam M, Williamson TH. Visual acuity outcomes following surgery for idiopathic epiretinal membrane: an analysis of data from 2001 to 2011. *Eye (Lond)*. 2014;28:219-24.
65. Ghazi-Nouri SM, Tranos PG, Rubin GS, et al. Visual function and quality of life following vitrectomy and epiretinal membrane peel surgery. *Br J Ophthalmol*. 2006;90:559-62.
66. Elhusseiny AM, Flynn HW, Jr., Smiddy WE. Long-Term Outcomes After Idiopathic Epiretinal Membrane Surgery. *Clin Ophthalmol*. 2020;14:995-1002.