

The importance of preoperative retrobulbar injection in the removal of intraocular foreign body perforating the posterior pole

Fikret Ucar¹

ABSTRACT

In this report, we wanted to present a case showing how surgical difficulties were managed in the removal of a metallic intraocular foreign body accompanied by posterior pole perforation. A 43-year-old male patient sustained an accidental penetrating injury to his left eye while working. Biomicroscopic examination revealed a foreign body entry site and iris prolapse at the corneascleral junction in the inferotemporal quadrant, while fundus examination revealed a vitreous hemorrhage covering the optic disc and macula. Computed tomography showed an intraocular foreign body perforating the posterior pole between the optic disc and the macula and localizing between the globe and the retrobulbar area. A retrobulbar injection involving epinephrine was administered to the patient under general anesthesia at the beginning of the surgery to reduce intraoperative bleeding and prevent the intraocular foreign body from escaping into the retrobulbar space. Following the closure of the primary wound with 10.0 nylon, a standard three-port-25-gauge pars plana vitrectomy was performed and the intraocular foreign body was captured by advancing through the posterior pole defect with ERM forceps. The 6*5 mm sharp-edged intraocular metallic foreign body was removed through a 6 mm pars plana incision. The procedure was terminated by injecting silicone oil into the vitreous cavity. At the last visit 8 months after surgery, best-corrected visual acuity was 20/80. In the management of intraocular metallic foreign body injuries perforating the posterior pole, preoperative retrobulbar injection of an anesthetic agent involving epinephrine can be very useful in removing the foreign body and ensuring intraoperative hemostasis.

Keywords: Intraocular foreign body, pars plana vitrectomy, posterior pole perforation, open globe injury.

INTRODUCTION

Management of intraocular foreign body perforating globe injuries and posterior scleral perforations has always been challenging for surgeons.¹ While intraoperative difficulties include detachment of the posterior hyaloid, intraoperative hemorrhage, the escape of an intraocular foreign body into the retroorbital space and closure of the posterior defect, the postoperative period includes concerns such as the development of endophthalmitis, proliferative vitreoretinopathy (PVR), and late-onset retinal detachment.² In this study, we wanted to present a case showing how surgical difficulties were managed in the removal of a metallic intraocular foreign body presenting with posterior pole perforation.

CASE REPORT

A 43-year-old male patient sustained an accidental penetrating injury to his left eye while working, and his visual acuity in the affected eye was at the level of hand movements. Biomicroscopic examination revealed a foreign body entry site and iris prolapse at the corneascleral junction in the inferotemporal quadrant, while fundus examination revealed a vitreous hemorrhage covering the optic disc and macula. Computed tomography showed an intraocular foreign body perforating the posterior pole between the optic disc and the macula and localizing between the globe and the retrobulbar area (Fig.1A). The surgery was initiated 12 hours after the injury under general anesthesia. A retrobulbar injection of 2.5 ml of 20 mg/ml lidocaine hydrochloride + 0.0125 mg/

1- Konyagoz Hospital, Department of Ophthalmology, Konya, Türkiye

Received: 28.03.2024

Accepted: 22.04.2024

J Ret-Vit 2024; 33: 217-219

DOI:10.37845/ret.vit.2024.33.34

Correspondence author:

Fikret Ucar

Email: fikretucar@konyagoz.com

ml epinephrine was administered to the patient at the beginning of the surgery to reduce intraoperative bleeding and prevent the intraocular foreign body from escaping into the retrobulbar space. Following the closure of the primary wound with 10.0 nylon, a standard three-port-25-gauge pars plana vitrectomy was performed. After the separation of the posterior hyaloid, a core vitrectomy was performed, and the hemorrhage on the macula and optic disc was removed. While the foreign body could not be seen, there was posterior scleral perforation adjacent to the optic disc and on the papillomacular bundle (PMB). The intraocular foreign body was captured with a single attempt by advancing through the posterior pole defect with ERM forceps, without missing the retrobulbar space. Through a 6 mm pars plana incision, the 6*5 mm sharp-edged intraocular metallic foreign body was removed (Fig.1B,1C). After the vitreous base was removed and the peripheral retina was controlled, the incarcerated retinal tissue was removed with a vitreous cutter. Since intraocular hemorrhage did not occur during surgery, endodiathermy was not used. Because of the proximity of the lesion to the optic nerve head and papillomacular bundle, cryotherapy

or endolaser photocoagulation was not applied. The procedure was terminated after the injection of silicone oil into the vitreous cavity (see video 1). At the postoperative visit, the full-thickness posterior pole defect was closed and the anatomical integrity of the globe was achieved without proliferative vitreoretinopathy (PVR) (Fig. 1D). Two months after the primary surgery, silicone oil explantation was performed and it was noticed that approximately half of the silicone oil had migrated to the retrobulbar area. At the last visit 8 months after surgery, best-corrected visual acuity was 20/80 and intraocular pressure (IOP) was 12 mmHg. No complications developed during the follow-up period.

DISCUSSION

In vitreoretinal surgeries performed after open globe injuries, ensuring intraoperative hemostasis and preventing bleeding in the early period was critical.³ Furthermore, in our case, there was a risk that the metallic intraocular foreign body, which ruptured the posterior segment full thickness, would escape into the retrobulbar space, complicating the surgery significantly. To eliminate these risks, we

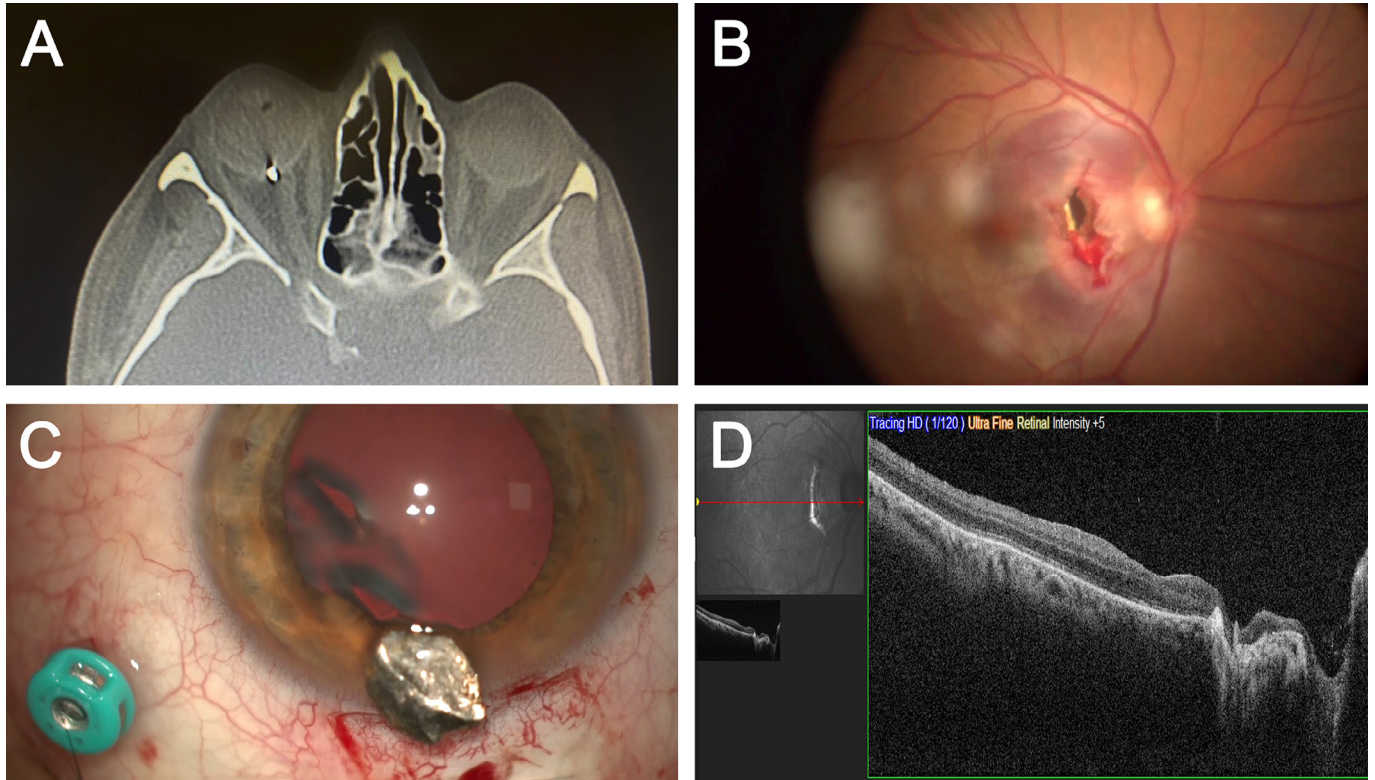


Figure 1 (A): An intraocular foreign body perforated the posterior pole between the optic disc and the macula and was located between the globe and the retrobulbar area, according to computed tomography; **(B-C)** The 6*5 mm sharp-edged intraocular metallic foreign body was captured with a single attempt by advancing through the posterior pole defect with ERM forceps, without missing the retrobulbar space and removed through a 6 mm pars plana incision; **(D)** Closure of the full-thickness posterior pole defect on the papillomacular bundle in the eighth postoperative month optical coherence tomography (OCT) image.

preoperatively injected a small amount of retrobulbar anesthetic agent involving epinephrine in a controlled manner. This intervention contributed significantly to the achievement of intraoperative hemostasis and the removal of the foreign body without it escaping into the retrobulbar area. However, in open globe injuries, adjusting the injection amount correctly and avoiding excessive injection is critical.

Poor visual and anatomical outcomes after perforated globe injuries have been found to be associated with proliferative vitreoretinopathy (PVR), which develops as a result of proliferation of retinal pigment epithelium (RPE) and fibrous tissue.⁴ Kuhn et al.⁴ performed prophylactic chorioretinectomy for perforation repair early after injury. In this technique, after all the retinal tissue trapped in the perforation area was removed with a vitrector, the retina and choroid in a 1 mm ring around the exit wound were also destroyed by diathermy. In our case, we could not apply cryotherapy and endolaser photocoagulation due to the proximity of the lesion to the optic nerve head and papillomacular bundle. However, after a meticulous surgery performed early after the injury and including prophylactic chorioretinectomy, PVR did not develop in our case during the follow-up period and visual acuity of 20/80 was achieved. Although some of the publications recommend late surgery performed 2 weeks after injury due to clearer cornea, development of posterior hyaloid detachment, and absence of new bleeding, early surgery is extremely critical to prevent PVR.^{3,6} Therefore, we performed vitreoretinal surgery combined with primary repair on the first day (within 12 hours). Moreover, with preoperative retrobulbar injection containing epinephrine, concerns such as bleeding and foreign body escape to the intraconal area could also be overcome.

CONCLUSION

In the management of intraocular metallic foreign body injuries perforating the posterior pole, preoperative retrobulbar injection of an anesthetic agent involving epinephrine can be very useful in ensuring intraoperative hemostasis and removing the foreign body.

Acknowledgements:

None

Declaration of conflicting interests:

The author declared no potential conflicts of interest with respect to the research, authorship, and/or publication of this article.

Funding

The author received no financial support for the research, authorship, and/or publication of this article.

Patient consent

Informed consent for the patient's information to be published was obtained.

REFERENCES

1. Ma J, Zhang Y, Moe MC, Zhu TP, Yao K. Transocular removal of a retrobulbar foreign body and internal patch of the posterior exit wound with autologous tenon capsule. *Arch Ophthalmol* 2012;130:493-6. <https://doi.org/10.1001/archophthalmol.2011.1482>
2. Szijártó Z, Gaál V, Kovács B, Kuhn F. Prognosis of penetrating eye injuries with posterior segment intraocular foreign body. *Graefes Arch Clin Exp Ophthalmol* 2008;246:161-5. <https://doi.org/10.1007/s00417-007-0650-1>
3. Ozdek S, Hasanreisoglu M, Yuksel E. Chorioretinectomy for perforating eye injuries. *Eye (Lond)* 2013;27:722-7. <https://doi.org/10.1038/eye.2013.18>
4. Kruger EF, Nguyen QD, Ramos-Lopez M, Lashkari K. Proliferative vitreoretinopathy after trauma. *Int Ophthalmol Clin* 2002;42:129-43. <https://doi.org/10.1097/00004397-200207000-00015>
5. Cupples HP, Whitmore PV, Wertz FD, Mazur DO. Ocular trauma treated by vitreous surgery. *Retina* 1983;3:103-7. <https://doi.org/10.1097/00006982-198300320-00006>

Video 1, Supplemental Digital Content 1. The removal of intraocular metallic foreign body perforating the posterior pole. Access link: <https://www.dropbox.com/scl/fi/nbshdip3zm0lcek18rzze/Video-1.mp4?rlkey=bobg7r2o8n64yg2udyywj17zd&dl=0>