

Fundus Autofluorescence Findings in Pigmented Paravenous Chorioretinal Atrophy

Pigmente Paravenöz Koryoretinal Atrofinin Fundus Otofloresans Bulguları

Canan Aslı UTİNE¹, Sinan TATLIPINAR¹, Ebru GÖRGÜN¹, Umut Aslı DİNÇ¹, Melda YENEREL¹, Ali AYATA², Levent Murat ALİMGİL¹

Case Report

Olgu Sunumu

ABSTRACT

To report fundus autofluorescence (FAF) imaging findings of a patient with pigmented paravenous chorioretinal atrophy (PPCRA). In a patient with incidentally detected bilateral PPCRA, FAF images were recorded with a new-generation confocal scanning laser ophthalmoscope (Heidelberg Retina Angiograph 2, Heidelberg, Germany). Atrophic areas typically appeared as hypoautofluorescent on FAF imaging, and borders of the chorioretinal atrophy areas appeared hyperautofluorescent, where RPE metabolism was presumably disturbed but chorioretinal atrophy has not yet appeared. It was remarkable that in some paravenous areas, hyperautofluorescence was seen where there were no evident abnormal findings in funduscopy. PPCRA has a typical appearance by FAF imaging. FAF imaging may be a useful noninvasive tool in the recognition of the activity and predicting the progression of the disease.

Key Words: Fundus autofluorescence, Pigmented paravenous chorioretinal atrophy.

ÖZ

Tesadüfen saptanan bilateral pigmentte paravenöz koryoretinal atrofi (PPKA) olan bir hastada, bir yeni-jenerasyon konfokal tarayıcı laser oftalmoskop (Heidelberg Retina Angiograph 2, Heidelberg, Germany) ile fundus otofloresans (FOF) görüntüleri kaydedildi. Atrofik alanlar FOF görüntülerinde tipik olarak hipo-otofloresan görünürken; RPE metabolizmasının olasılıkla bozulduğu ancak atrofinin henüz belirmediği koryoretinal atrofi alan sınırları hiperotofloresan görüldü. Fundoskopide aşikar anormal bulgu olmayan bazı paravenöz alanlarda da hiperotofloresans görülmesi kayda değerdi. PPKA'nın tipik görünümü nedeniyle, hastalığın aktivitesinin saptanması ve progresyonunun takibinde FOF görüntülemenin faydalı invazif-olmayan bir araç olduğu sonucuna varıldı.

Anahtar Kelimeler: Fundus otofloresansı, pigmentte paravenöz koryoretinal atrofi.

Ret-Vit 2009;17:285-287

INTRODUCTION

Pigmented paravenous chorioretinal atrophy (PPCRA) is a rare disorder with the typical fundoscopic appearance of retinal pigment epithelial (RPE) atrophy and clumping in a paravenous distribution.¹ Fundus autofluorescence (FAF) is the emission of fluorescence without any fluorescent dye in the eye. The major source of FAF is considered to be the lipofuscin in the RPE cells.²

The aim of the present study was to report FAF imaging findings of a patient with PPCRA. To the best of our knowledge, this is only the second report of FAF imaging findings for PPCRA.³

Geliş Tarihi : 13/11/2008

Kabul Tarihi : 24/12/2008

Received : November 13, 2008

Accepted : December 24, 2008

- 1- Yeditepe Üniversitesi Göz Hastanesi, İstanbul, Yard. Doç. Dr.
- 2- GATA Haydarpaşa Eğitim ve Araştırma Hast., Göz Hastalıkları, İstanbul, Yard. Doç. Dr.

- 1- M.D. Assistant Professor, Yeditepe University Eye Hospital, İstanbul/TURKEY
UTİNE C. A., cananutine@gmail.com
GÖRGÜN E., ebrugorgun@gmail.com
YENEREL M., meldayen@hotmail.com
DİNÇ U. A., umutdinc@yahoo.com
- 2- M.D. Associate Professor, Yeditepe University Eye Hospital, İstanbul/TURKEY
TATLIPINAR S., statlipi@yahoo.com
- 3- M.D. Assistant Professor, GMMMA Haydarpaşa Training Hospital, Department of Ophthalmology İstanbul/TURKEY
AYATA A., ali_ayata@yahoo.com
- 4- M.D. Professor, Yeditepe University Eye Hospital, İstanbul/TURKEY
ALİMGİL L., levalim@ttnet.net.tr

Correspondence: M.D. Assistant Professor, Canan Aslı UTİNE
Yeditepe University Eye Hospital, Şakir Kesebir Sokak İstanbul/TURKEY

CASE REPORT

A 69-year-old man was admitted for routine ophthalmological control. He had medically regulated diabetes mellitus and arterial hypertension for 1 year. He had undergone pterygium excision surgery from his left eye, with no recurrence. He did not report any ocular problem in his family, any drug allergies or use of any drug potentially toxic to the eye.

He had 20/20 visual acuity bilaterally, with +1.75 (-0.75x90) OD and +1.50 (-0.50x100) OS. He had bilateral nuclear sclerosis and nasal corneal scar in the left eye, secondary to pterygium excision. His intraocular pressures were 19 mmHg OD, 17 mmHg OS. In funduscopy, optic nerves and maculae were normal, bilaterally. Perivenous chorioretinal atrophy with patches of pigment accumulations were seen in both eyes, which extended from a distance to the optic nerve to peripheral retina. There were no changes in the periarterial areas. Atrophy of deep retinal layers including RPE and

choriocapillaris was noted along retinal veins (Figure 1a,b). The vitreous body seemed degenerated in the left eye, with posterior hyaloid detachment. On the basis of clinical appearance, the diagnosis of PPCRA was made.

A new-generation confocal scanning laser ophthalmoscope (HRA2, Heidelberg, Germany) was used for the detection of infra-red (IR) and FAF images. It uses argon blue laser of 488nm wavelength as stimulating light. Its barrier filter allows passage of wavelengths ≥ 500 nm. The FAF images were recorded in fluorescein angiography mode without injecting fluorescein dye, after focusing in the IR mode. The mean function (ie, averaging 9 consecutive images) was used to achieve images with less noise.

The IR images revealed increased hyperreflectivity that corresponded to chorioretinal atrophy along the major veins (Figure 2a,b). On FAF imaging, atrophic areas typically appeared as hypoautofluorescent and borders of the chorioretinal atrophy areas appeared

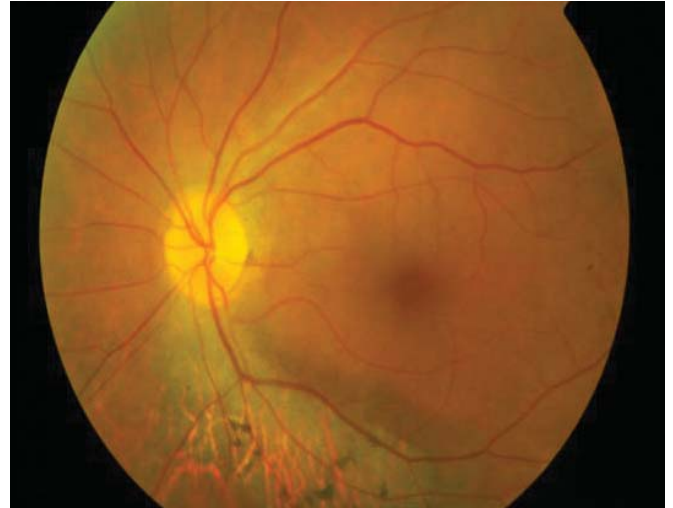
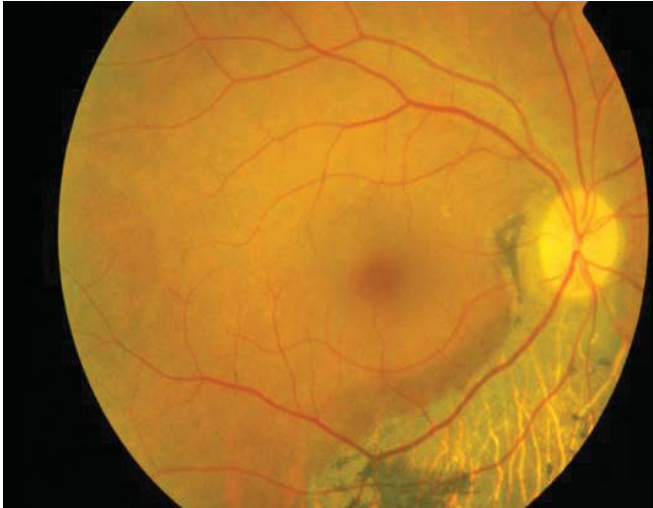
Figure 1a-b: Fundus photographs of the right and left eye displayed the progressive atrophy of deep retinal layers including RPE and choriocapillaris along retinal veins.

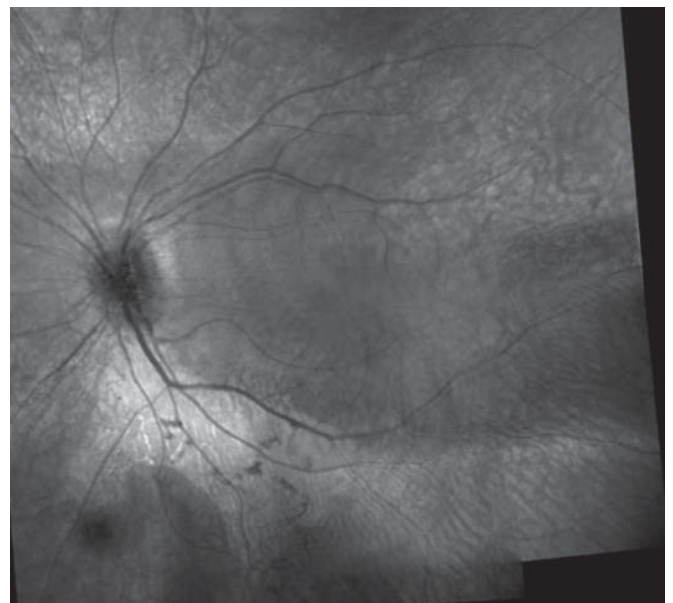
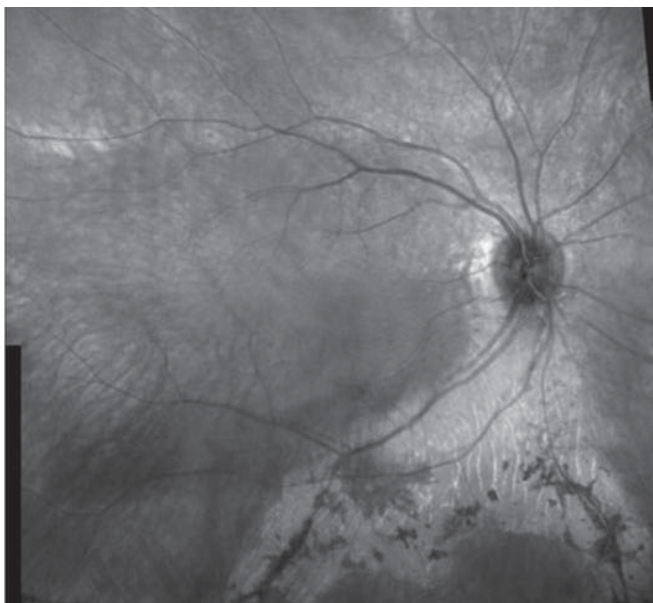


Figure 2a-b: Composite IR images of the right and left eye showed increased hyperreflectivity that corresponds to chorioretinal atrophy along the major veins.

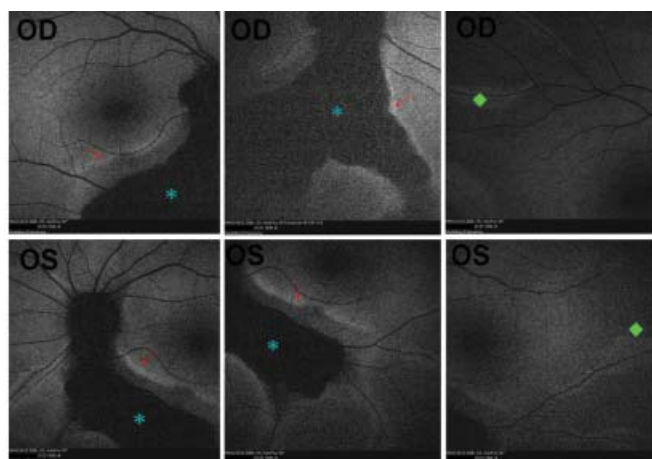


Figure 3a-f: FAF images revealed atrophic areas as hypoautofluorescent (asterisk), and borders of the chorioretinal atrophy areas as hyperautofluorescent (arrow). In some paravenous areas, hyperautofluorescence was seen where there were no evident abnormal findings in funduscopy (diamond).

hyperautofluorescent (Figure 3a,b). The line of increased FAF did not show a prominent correlation with the lesions in fundus photography. It was remarkable that in some paravenous areas, hyperautofluorescence was seen where there are no evident abnormal findings in funduscopy.

DISCUSSION

PPCRA is a slowly progressive disease with respect to the loss of peripheral vision and electroretinogram amplitudes.⁴ The disease progression could be assessed by the changes in visual field and electroretinogram amplitudes, beside fundus photographs and fluorescein angiographies.

FAF signal mainly derives from RPE lipofuscin,² which is a wear-and-tear product and has AF properties due to the photoreactive components which form during the oxidative breakdown. Therefore, FAF has been regarded as non-invasive RPE examination method.⁵ Hypoautofluorescence is due to RPE atrophy or blockage (eg., retinal hemorrhage); hyperautofluorescence is due to increased metabolic activity or increased visibility of RPE (eg., macular hole).

Recently, with the advent of confocal scanning laser ophthalmoscopy using appropriate excitation wavelengths and barrier filters, it is now possible to record topographic variations of lipofuscin-related AF in specific planes in vivo.

RPE cells are known to accumulate large amounts of lipofuscin in a variety of retinal diseases, which induce RPE apoptosis.⁶ In our case, FAF images seem to delineate the pathological process. Hyper-AF was revealed in areas where RPE metabolism was presumably disturbed but chorioretinal atrophy has not yet appeared. It seems that the area of lipofuscin-laden RPE at the border of the expanding lesion leads to RPE cell death and subsequent choriocapillaris atrophy which give hypo-AF to the center of the lesion in PPCRA.

Hyper-AF could be accepted as an indicator of disease activity and expected progression. On the other hand, the other aforementioned tests can provide only the disease status at that moment and give no clue about the future progression. Additionally, FAF imaging reveals the exact borders of the pathology, which is wider than revealed by fundus photographs or invasive fundus fluorescein angiographies.

In conclusion, PPCRA has a typical appearance by FAF imaging. FAF imaging may be a useful noninvasive tool in recognition of the activity and predicting the progression of the disease.

REFERENCES/KAYNAKLAR

1. Traboulsi EI, Maumenee IH.: Hereditary pigmented paravenous chorioretinal atrophy. *Arch Ophthalmol.* 1986;104:1636-1640.
2. Sparrow JR.: Lipofuscin of the Retinal Pigment Epithelium. In: *Atlas of Fundus Autofluorescent Imaging.* Eds: Holz FG, Schmitz-Valckenberg S, Spaide RF, Bird AC. Springer, Inc. 2007;17.
3. Charbel Issa P, Scholl HP, Fleckenstein M, et al.: *Klin Monatsbl Augenheilkd.* 2007;224:791-793.
4. Choi JY, Sandberg MA, Berson EL.: Natural course of ocular function in pigmented paravenous retinochoroidal atrophy. *Am J Ophthalmol.* 2006;141:763-765.
5. Delori FC, Dorey CK, Staurengi G, et al.: In vivo fluorescence of the ocular fundus exhibits retinal pigment epithelium lipofuscin characteristics. *Invest Ophthalmol Vis Sci.* 1995;36:718-729.
6. Kawaji T, Hirata A, Inomata Y, Koga T, et al.: Morphological damage in rabbit retina caused by subretinal injection of indocyanine green. *Graefes Arch Clin Exp Ophthalmol.* 2004;42:158-164.