

# Multiple Evanescent White Dot Syndrome Presenting that as Central Serous Chorioretinopathy

## Santral Seröz Koryoretinopati Şeklinde Prezente Olan Multipl Geçici Beyaz Nokta Sendromu

Gülizar DEMİROK<sup>1</sup>, Yasemin TOPALAK<sup>2</sup>, Burcu TABAKCI<sup>3</sup>, Ahmet ŞENGÜN<sup>4</sup>

### ABSTRACT

A 28-year-old man presented to the clinic with metamorphopsia, central scotoma, and visual loss in his right eye. After detailed ophthalmic examination, funduscopy showed localized elevation of the macula, and optical coherence tomography also showed subretinal serofibrinous accumulation temporal to the fovea. He was evaluated as idiopathic central serous chorioretinopathy (CSCR). At the fifth day of presentation he was seen by the retinal consultant with fluorescein angiography (FA) and indocyanine green angiography (ICGA) which were characteristic of multiple evanescent white dot syndrome (MEWDS) in the right eye. The diagnosis was changed as MEWDS presenting that as CSCR, and it was seen that the serofibrinous elevation began to decline after the first week of presentation. Symptoms and visual disturbance recovered without any further treatment at sixth month in this case.

**Keywords:** Multiple evanescent white dot syndrome, subretinal serofibrinous exudate, central serous chorioretinopathy.

### ÖZ

Yirmisekiz yaşında erkek hasta metamorfozi, santral skotom ve görme kaybı ile kliniğimize başvurdu. Detaylı oftalmolojik muayenede fundusta makulada lokalize seröz dekolman, optik koherens tomografi ile de foveanın temporalinde subretinal seröfibrinöz birikim tespit edildi ve hastamız idiopatik santral seröz koryoretinopati (SSKR) tanısı ile retina bölümüne yönlendirildi. Beşinci günde tekrar görülen hastanın fundus flöresein ve indosiyenin yeşili anjiografisinde multipl geçici beyaz nokta sendromuna (MGBNS) karakteristik bulgular saptandı. Hastanın tanısı SSKR şeklinde prezente olan MGBNS olarak değiştirildi. Birinci haftadan sonra seröfibrinöz elevasyon azalmaya başladı. Semptomlar ve görme bozukluğu 6. ayın sonunda hiçbir tedavi gerektirmeden tamamiyle düzeldi.

**Anahtar Sözcükler:** Multipl geçici beyaz nokta sendromu, subretinal serofibrinöz eksuda, santral seröz koryoretinopati.

### INTRODUCTION

Multiple evanescent white dot syndrome (MEWDS) is a relatively rare chorioretinal condition with transient unilateral white dots located at posterior pole.<sup>1</sup> It causes visual loss of variable degrees and associated clinical features include flu-like prodrome, blind spot enlargement, foveal granularity, and rarely vitritis, vasculitis or papillitis.<sup>2</sup> Fluorescein angiography (FA) shows early hyperfluorescence and late staining corresponding to the spot areas.<sup>3</sup> In contrast, indocyanine green angiography (ICGA) typically shows

hypofluorescence spots which they are more numerous than in FA or clinical presentation.<sup>4</sup>

Central serous chorioretinopathy (CSCR), which is characterized by detachment of the neurosensory retina in the macular area, is a common clinical diagnosis, particularly in young to middle-aged adults.<sup>5</sup> Previous studies attempting to determine the pathogenesis of the disease have focused on the retina pigment epithelium (RPE) and choroidal dysfunction. MEWDS is also considered as RPE inflammation and acute choroidal ischemia and especially affects the macula.<sup>4</sup>

1- Doç. Dr., Ankara Eğitim ve Araştırma Hastanesi, Göz Hastalıkları, Ankara, Türkiye

2- Uz. Dr., Aksaray Eğitim ve Araştırma Hastanesi, Göz Hastalıkları, Ankara, Türkiye

3- Yrd. Doç. Dr., Medipol Üniversitesi, Göz Anabilim Dalı, Ankara, Türkiye

4- Prof. Dr., Ufuk Üniversitesi Tıp Fakültesi, Göz Anabilim Dalı, Ankara, Türkiye

**Geliş Tarihi - Received:** 10.06.2018

**Kabul Tarihi - Accepted:** 21.06.2018

*Ret-Vit 2019; 28: 213-216*

**Yazışma Adresi / Correspondence Address:**

Gülizar DEMİROK

Ankara Eğitim ve Araştırma Hastanesi, Göz Hastalıkları, Ankara, Türkiye

**Phone:** +90 505 821 9498

**E-mail:** gulizardemirok@hotmail.com

Although, in the literature there is no MEWDS case that have been described as CSCR initially, overlap of these two entities is not very unreasonable because of the similar pathophysiology.

Herein, we report an unusual presentation of a MEWDS case that evaluated as CSCR initially who has no white spots in fundoscopy, but shows multiple hyper/hypofluorescence spots in FA and ICG examination in addition to subretinal elevation of macula.

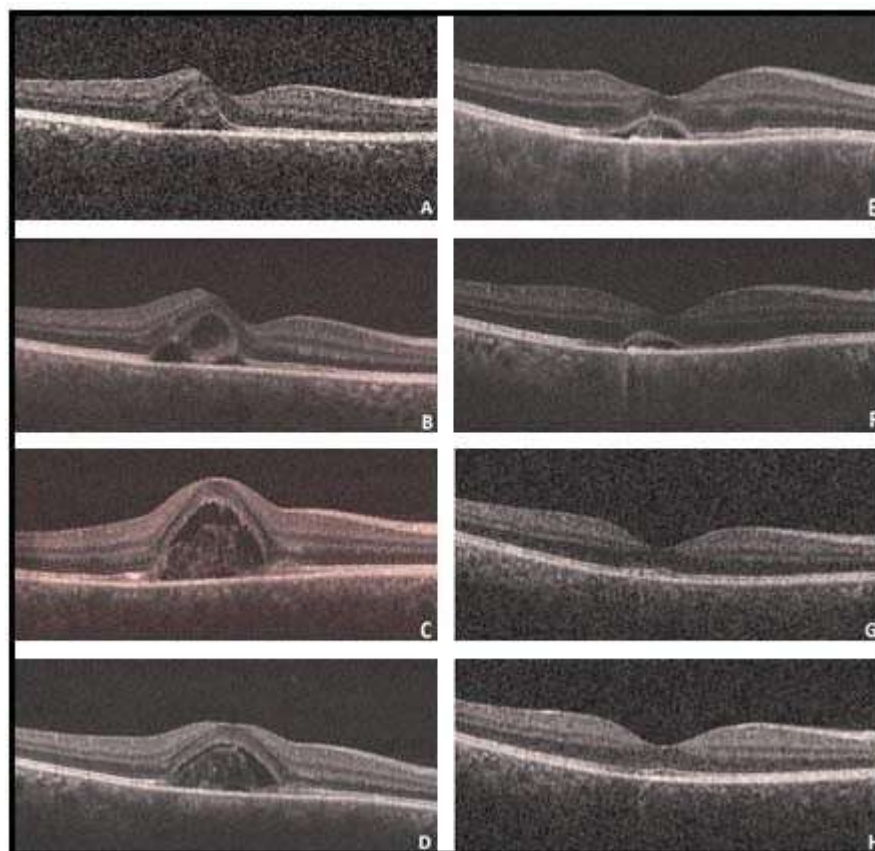
### CASE REPORT

A 28-year-old man presented with complaints of metamorphopsia and visual loss in his right eye for two days. His best-corrected visual acuity was 20/80 in the right eye and 20/20 in the left eye. Slit-lamp examination, pupillary reactions, ocular motility, and intraocular pressures were normal. Dilated fundus examination in the right eye revealed mild elevation of fovea and two separate focus of leakage, optic disc was normal, no vitreous cell and no white dots were seen. The left eye was fully normal (Figure 1). Optical coherence tomography (OCT) of the right eye demonstrated

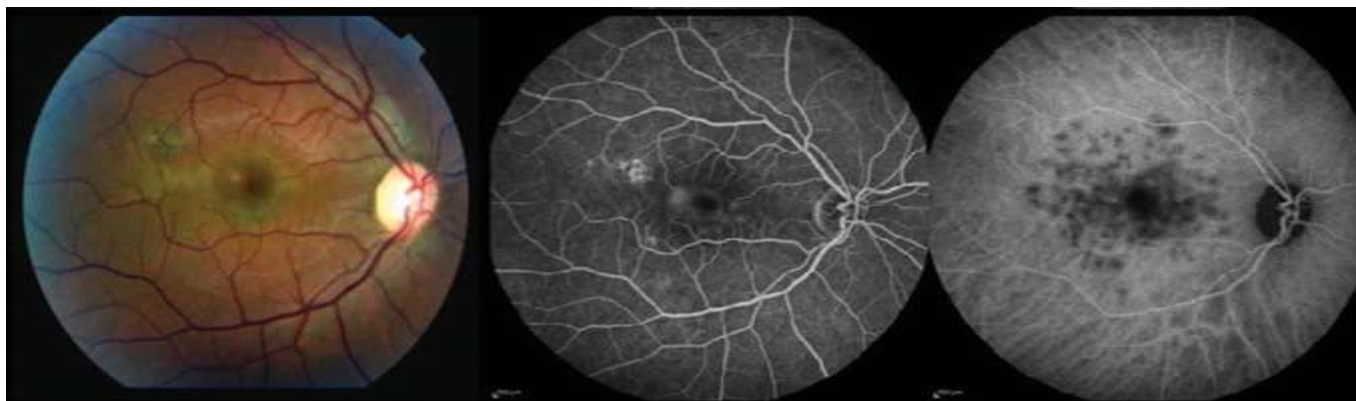detachment of the neurosensory retina in the macular area and temporal to fovea. The fluid beneath the detached area was not completely serous (Figure 2A). The patient was evaluated as CSCR, and was followed up without any treatment.

At the next day of presentation, he complained that increased metamorphopsia and visual loss in the right eye. Increased serous elevation and fibrin content under the detached retina were seen in OCT (Figure 2B). On the fifth day of presentation his vision level reduced to 20/100 in the right eye, and it was seen that the serous elevation progressed towards to fovea in OCT (Figure 2C). The patient was seen at the fifth day of follow-up with FA and ICGA by the retinal consultant because of the increased serofibrinous exudation of macula and loss of vision. The color fundus photography demonstrated subretinal fluid involving the fovea and FA showed several early hyperfluorescence spots near the fovea which were not seen in the fundus examination. In contrast ICGA revealed hypofluorescent spots that more numerous than the spots seen with FA (Figure 3).

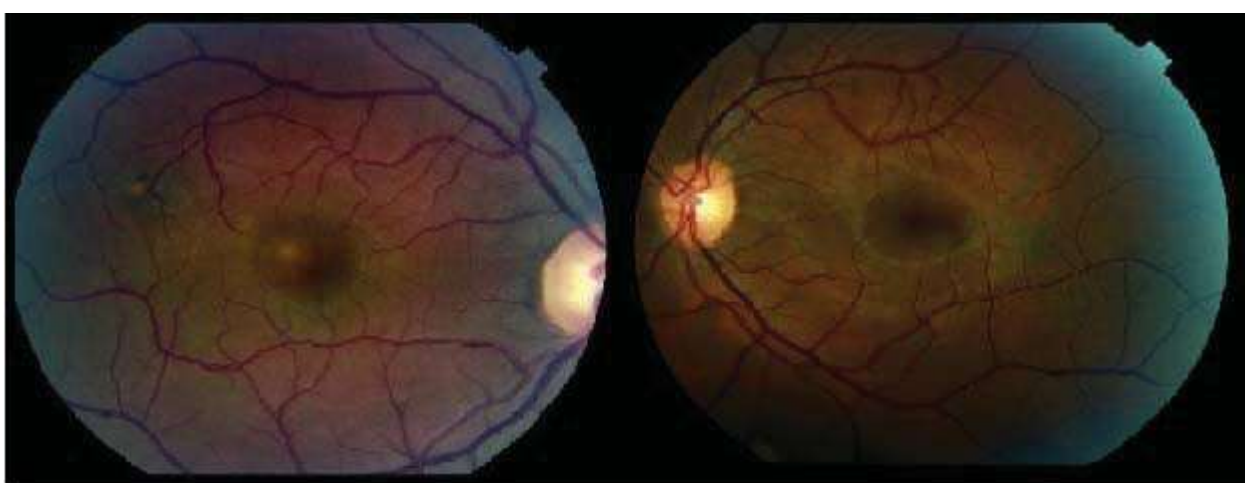
Results of visual field testing revealed enlarged blind spot and a central scotoma. The diagnosis was changed as multiple



**Figure 1.** A: The optical coherence tomography (OCT) of the right eye at the initial presentation. B: The OCT of the right eye at the next day of presentation. C: The OCT of the right eye at the fifth day of presentation D: The OCT of the right eye at the first week of presentation E: The OCT of the right eye at the tenth day of presentation F: The OCT of the right eye at the twentieth day of presentation G: The OCT of the right eye at the first month of presentation H: The OCT of the right eye at the sixth month of presentation



**Figure 2.** The fundus fluorescein angiography and indocyanine angiography of the right eye at the fifth day of presentation.



**Figure 3.** The color fundus photography, fluorescein angiography and indocyanine angiography of the right eye at the fifth day of presentation.

evanescent white dot syndrome presenting that as CSCR. Due to benign prognosis of MEWDS, he was followed-up without any treatment. with OCT The serofibrinous elevation progressively reduced after the first week of presentation (Figure 2D, 2E, 2F, 2G) and completely disappeared at sixth month (Figure 2H). The visual acuity reached 20/20 at the end of follow-up.

## CONCLUSION

MEWDS is characterized as acute and unilateral multifocal chorioretinopathy, typically affecting young women. A viral prodrome is reported in half of cases.<sup>2</sup> Our patient was men and had no flu-like prodrome, and in contrast to clinical knowledge, on ophthalmoscopy, there was no white dots. Because of finding a localized serous macular elevation in OCT, we evaluated the patient as CSCR, and did not need any further examination.

Several hypotheses have been suggested regarding the pathogenesis of CSCR, but none have been definitively proved. The most current mechanism is malfunction of the

RPE pump, leading to RPE leakage.<sup>5</sup> In MEWDS studies have demonstrated the involvement of RPE and photoreceptors. It may be hypothesized that CSCR and MEWDS share a similar mechanism of pathogenesis. Therefore these two entities may overlap, or serous detachment of macula may be a consequence of MEWDS. Despite Chao et al. reported four patients diagnosed with MEWDS presented with peripapillary serous detachments that can occur secondary to choroidal inflammation<sup>6</sup>, there is no MEWDS case in the literature that presented with serous detachment in the posterior pole. Macular serous detachments have been reported in punctate inner chorioretinopathy and acute posterior multifocal placoid pigment epitheliopathy, which are considered in the same group of disease with MEWDS.<sup>7,8</sup>

Whereas, MEWDS was identified with easily visible multifocal small white lesions in fundus examination, in this case no white dots were seen clinically despite the detection in FA and ICGA. Similarly, Shelsta et al. reported a case series that consist of three MEWDS cases without any white dots in fundus examination.<sup>9</sup> The diagnosis confirmed with mild disc swelling, peripapillary whitening, foveal

granularity, and full recovery of vision in all three patients without any therapy. Unlike our case, no characteristic lesions were seen on FA or ICGA in their cases.

In MEWDS, the visual field demonstrates enlarged blind spot and central or cecentral scotoma, whereas CSCR is characteristic with blind spot in the central field. Although, in patients with CSCR, FA no longer perform as a rutin examination or follow-up test because of invasive feature, performing visual field test which is noninvasive and relatively less costly, and identifying blind spot enlargement may help to think MEWDS among the differential diagnosis. On the other hand, this finding may give a clue that detachment will have good prognosis.

Although in the majority of patients with CSCR fluid under detached retina serous and transparent, in this case prominent fibrin content, depending on the accompanying choroidal inflammation, was remarkable. Despite such a high elevation and photoreceptor damage, complete disappearance of the liquid and improvement of vision and other symptoms in a month may be attributed to the excellent prognosis of MEWDS.

This report has shown us that some of CSCR cases may be emerge as a preliminary finding of another disease. The increase of visual loss and fibrin component of serous elevation, at the next day of presentation, directed us to research another possible diagnosis. Finally, additional investigation may require for some well known diseases with atypical progression to elucidate the etiology and prognosis.

## REFERENCES / KAYNAKLAR

1. Gross NE, Yanuzzi LA, Freund B, et al. Multiple evanescent white dots syndrome. *Arch Ophthalmol*. 2006;124:493-500.
2. Vianna RNG, Socci D, Nehemy MB, et al. The white dot syndromes. *Arq Bras Oftalmol*. 2007;70:554-62.
3. Yılmaz T, Çelebi S, Kükner AŞ. Multiple evanescent white dot sendromu. *Ret-Vit*. 2002;10:288-92.
4. Hua R, Chen K, Liu LM, et al. Multi-modality imaging on multiple evanescent white dot syndrome-A Spectralis Study *Int J Ophthalmol*. 2012;5:644-7.
5. Velthoven MEJ, Verbraak FD, Garcia PM, et al. Evaluation of central serous retinopathy with en face optical coherence tomography. *Br J Ophthalmol*. 2005;89:1483-8.
6. Chao DL, Marsiglia M, Ahmad B, et al. Peripapillary serous detachment in multiple evanescent white dot syndrome. *Retina*. 2015;35:521-4.
7. Watzke RC, Packer AJ, Folk JC, et al. Punctate inner choroidopathy. *Am J Ophthalmol*. 1984;98: 572-84.
8. Birnbaum AD, Blair MP, Tessler HH, et al. Subretinal fluid in acute posterior multifocal placoid pigment epitheliopathy. *Retina*. 2010;30: 810-4.
9. Shelsta HN, Rao RR, Bhatt HK, et al. Atypical presentations of multiple evanescent white dot syndrome without white dots. A case series. *Retina*. 2011;31: 973-6.