

Anti-VEGF Treatment and Results in a Child with Juxtapapillary Choroidal Neovascular Membrane Secondary to Optic Disc Drusen

Enver Mirza¹, Günsu Deniz Mirza², Günhal Şatırtav Akdeniz³, Refik Oltulu³, Hürkan Kerimoğlu³

ABSTRACT

A 16-year-old patient was referred to our clinic with the complaint of blurred vision in the right eye. The best-corrected visual acuity (BCVA) was 8/10 in the right eye and 10/10 in the left eye. Fundus examination revealed bilateral slightly elevated optic disc (OD) with blurred margins. Optical coherence tomography (OCT) imaging showed subretinal fluid in the right eye at presentation and in the left eye during the follow-up. The patient was diagnosed with bilateral choroidal neovascular membrane (CNVM) secondary to optic disc drusen (ODD) and treated with intravitreal ranibizumab injections. In control visit on month 1, vision improved and the subretinal fluid was decreased in the right eye. BCVA decreased in the left eye and presented subretinal fluid at the nasal side of the macula. Therefore, bilateral ranibizumab injection was performed by 2-week interval, primarily on the left eye. After 6 month follow-up, BCVA was 10/10 in the right eye and improved to 63/100 in the left eye.

Keywords: Optic disc drusen, choroidal neovascular membrane, ranibizumab, anti-VEGF.

INTRODUCTION

The prevalence of optic disc drusen (ODD), composed of hyaline-like calcific deposits, is 0.4% at childhood and 0.5-2.4% in adults.¹⁻³ The ODD which is generally bilateral and its pathogenesis hasn't been fully elucidated. It can be seen with diseases such as angioid streak, retinitis pigmentosa and Alagille syndrome; however, it may present without a symptom of a disease.³

Although it is benign in character, it can rarely result in loss of vision in children by causing complications such as non-arteritic ischemic optic neuropathy, central retinal artery and/or vein occlusion, optic disc hemorrhage or choroidal neovascular membrane (CNVM) since it can lead obstruction due to its localization adjacent to lamina cribrosa of optic nerve together with crowded disc and narrow scleral canal.⁴

The anti-VEGF agents, which are used in the treatment of many retinal diseases in adults including age-related macular degeneration, has been recently introduced in

the treatment of pediatric disorders such as Coat's disease and Best disease and ODD-related CNVM.⁵⁻⁷ Here, it was aimed to present effect of anti-VEGF treatment and outcome following 6-months in a 16-years old child developed juxtapapillary CNVM secondary to ODD.

CASE REPORT

A 16-year-old girl with no known systemic disease presented with blurred vision in right eye and underwent optical coherence tomography (OCT) in another facility; the patient was referred to our clinic due to presence of subretinal fluid on OCT thereafter. best-corrected visual acuity (BCVA) according to Early treatment diabetic retinopathy study (ETDRS) was 8/10 in the right eye and 10/10 in the left eye. Intraocular pressure (IOP) and anterior segment examination were normal. In fundus examination, it was found that there was effacement and mild elevation in margins of optic disc and yellow-green lesions at temporal to optic discs in both eyes and that there was subretinal hemorrhage at superior to optic disc in right eye (Figure 1A).

1- Asst. Prof.Dr. Department of Ophthalmology, Meram School of Medicine, Necmettin Erbakan University, Konya, Türkiye

2- MD, Department of Ophthalmology, Meram School of Medicine, Necmettin Erbakan University, Konya, Türkiye

3- Prof.Dr. Department of Ophthalmology, Meram School of Medicine, Necmettin Erbakan University, Konya, Türkiye

Received: 16.03.2021

Accepted: 16.09.2021

Ret-Vit 2022; 31: 267-270

DOI:10.37845/ret.vit.2022.31.46

Correspondence Address:

Günsu Deniz Mirza

Necmettin Erbakan Üniversitesi Meram Tıp Fakültesi, Göz Hastalıkları, Konya, Türkiye

Phone:

E-mail: gayretli.deniz@gmail.com

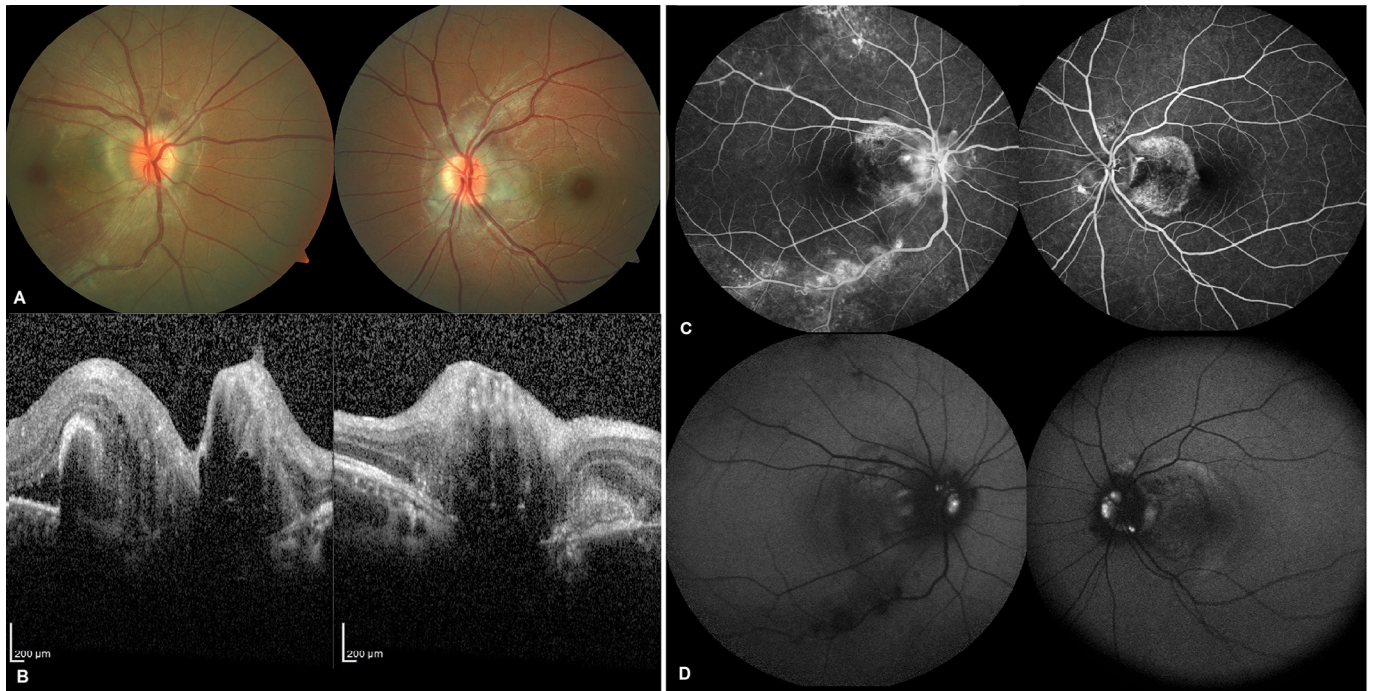


Figure 1: Fundus images of both eyes (A), OCT images of both eyes (B), FAF images of both eyes (C), FOF images of both eyes (D).

On OCT, it was observed that there was subretinal fluid at temporal to right eye and hyper-reflective, subretinal CNVM-like lesion at temporal to optic discs in both eyes (Figure 1B). On late phase of fundus fluorescein angiography (FFA), it was seen that there was leakage at peripapillary region in the areas where CNVMs were located, particularly in right eye (Figure 1C). On fundus auto-fluorescein (FOF) imaging, round-oval hyperautofluorescent nodules compatible with drusen were observed in optic disc heads in both eyes (Figure 1D). In addition, there was hyperechogenic appearance over optic disc on sonography.

The patient was diagnosed with juxtapapillary CNVM secondary to ODD and single dose of intravitreal ranibizumab injection (0.5 mg/0.05 mL) was administered to right eye. In control visit on month 1, it was seen that the subretinal fluid was decreased in the right eye but not resolved completely. It was found that BCVA was decreased to 25/100 in the left eye and that subretinal fluid was developed at nasal to macula (Figure 2A). Therefore, bilateral ranibizumab injection was performed by 2-week interval, primarily on the left eye. On month 3, it was seen that BCVA was improved to 10/10 in the right eye and 4/10 in the left eye and that subretinal fluid was completely resolved in the left eye but persisted in the right eye (Figure 2B). The patient was followed without ranibizumab injection. It was observed that there was no change in BCVA and OCT on month 4 and 5 while BCVA

was 10/10 in right eye and 63/100 in the left eye without marked change on OCT in both eyes (Figure 2C).

DISCUSSION

ODD is a congenital optic disc anomaly which is typically bilateral and rarely seen at childhood. In general, it can be overlooked during routine examination as it is embedded in anatomic manner. However, in suspected cases with more superficial location, differential diagnosis should be made with increased intracranial pressure which can be life-threatening since as it can be confused with papilledema. OCT, FOF, FFA, ultrasonography and computerized tomography can be used for diagnosis and differential diagnosis.

The CNVM secondary to ODD is generally seen at juxtapapillary region and can lead subretinal fluid accumulation by affecting subfoveal region, submacular hemorrhage and loss of central vision secondary to serous macular detachment.⁴ Several treatment modalities including focal photocoagulation (PK), photodynamic therapy or surgical removal of CNVM have been attempted in case of such complications.^{8,9} However, there is no consensus about treatment options.

Alkın et al. administered a single dose of anti-VEGF injection for CNVM secondary to ODD in a 13-year-old girl and reported that visual acuity was improved from 20/80 to 20/25 at the end of first month and that there was no recurrence at 9-months follow-up.¹⁰ Baillif et al.

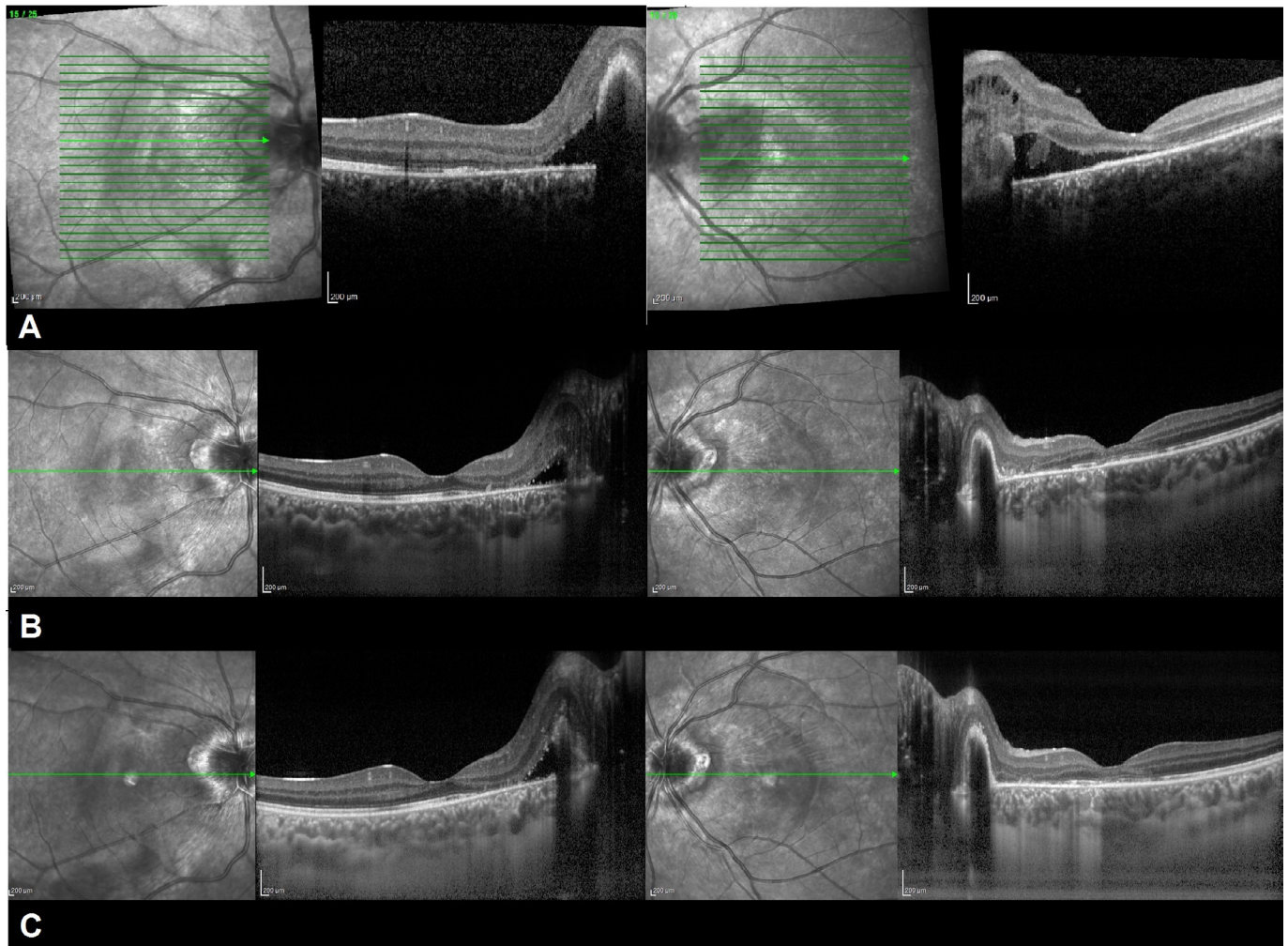


Figure 2: OCT images of both eyes on month 1 (A), Month 3 (B), Month 6 (C).

administered a single dose of anti-VEGF injection for CNVM secondary to ODD in a 5-year-old patient and reported that visual acuity was increased from 20/60 to 20/25 and remained stable over 12 months.¹¹ Delas et al. administered two doses of anti-VEGF injections for CNVM secondary to ODD in a 12-year-old patient and reported that visual acuity was improved from 20 cmfc to 20/60 and there was no additional problem during 12-months follow-up.¹² Gregory-Evans et al. reported three doses of anti-VEGF injections administered to a 11-year-old patient with CNVM secondary to ODD. Authors reported that visual acuity was increased from 20/100 to 20/20 and remained stable over 6 months with recovery of maculopathy.¹³ Knape et al. reported that subretinal fluid and CNVM findings were regressed in a 5-year-old patient who was treated with 2 doses of anti-VEGF injections in both eyes and focal PK and that visual acuity was increased from 20/200 to 20/30 in the right eye and from 20/70 to 20/20 in the left eye.¹⁴

In conclusion, although there are many studies on anti-VEGF agents which have been long used in the treatment

of age-related macular degeneration, there is limited information about anti-VEGF use in the treatment of CNVM secondary to ODD. In this study, it was observed that CNVM was regressed with resolution in macular edema and that visual acuity was improved and remained stable at long-term follow-up after anti-VEGF therapy. Thus, anti-VEGF agents should be considered as an effective and contemporary treatment method in patients with CNVM secondary to ODD.

REFERENCES

1. Erkkila H. Clinical appearance of optic disc drusen in childhood. *Albrecht Von Graefes Arch Klin Exp Ophthalmol* 1975;193:1-18.
2. Friedman AH, Henkind P, Gartner S. Drusen of the optic disc. A histopathological study. *Trans Ophthalmol Soc U K.* 1975;95:4-9
3. Auw-Haedrich C, Staubach F, Witschel H. Optic disk drusen. *Surv Ophthalmol.* 2002;47:515-32
4. Mateo C, Moreno JG, Lechuga M, ve ark. Surgical removal of peripapillary choroidal neovascularization associated with optic nerve drusen. *Retina* 2004; 24: 739-45.

5. Kramer M, Axer-Siegel R, Jaouni T, ve ark. Bevacizumab for choroidal neovascularization related to inflammatory diseases. *Retina* 2010;30:938-44.
6. Cakir M, Cekic, O, Yilmaz OF. Combined intravitreal bevacizumab and triamcinolone injection in a child with Coats disease. *J AAPOS* 2008;12:309-11.
7. Cakir M, Cekic, O, Yilmaz OF. Intravitreal bevacizumab and triamcinolone treatment for choroidal neovascularization in Best disease. *J AAPOS* 2009;13:94-6.
8. Delyfer MN, Rougier MB, Fourmaux E, ve ark. Laser photocoagulation for choroidal neovascular membrane associated with optic disc drusen. *Acta Ophthalmol Scand* 2004;82:236-8.
9. Silva R, Torrent T, Loureiro R, ve ark. Bilateral CNV associated with optic nerve drusen treated with photodynamic therapy with verteporfin. *Eur J Ophthalmol* 2004;14:434-7.
10. Alkin Z, Ozkaya A, Yilmaz I, ve ark. A single injection of intravitreal ranibizumab in the treatment of choroidal neovascularization secondary to optic nerve head drusen in a child. *BMJ Case Reports* 2014:
11. Baillif S, Nguyen E, Colleville-El Hayek A, ve ark. And one long-term follow-up of a child treated with ranibizumab: long term follow-up after a single intravitreal ranibizumab injection for choroidal neovascularisation secondary to optic nerve head drusen in a 5-year-old child. *Graefes Arch Clin Exp Ophthalmol* 2013;251:1657-9.
12. Delas B, Almudi L, Carreras A, ve ark. Bilateral choroidal neovascularization associated with optic nerve head drusen treated by antivascular endothelial growth factor therapy. *Clin Ophthalmol* 2012;6:225-30.
13. Gregory-Evans K, Rai P, Patterson J. Successful treatment of subretinal neovascularization with intravitreal ranibizumab in a child with optic nerve head drusen. *J Pediatr Ophthalmol Strabismus* 2009.
14. Knape RM, Zavaleta EM, Clark CL III, ve ark. Intravitreal bevacizumab treatment of bilateral peripapillary choroidal neovascularization from optic nerve head drusen. *J AAPOS* 2011;15:87-90.