

# Refractive Errors and Ocular Findings in Cases with Ocular Coloboma

Esay Kiran Yenice<sup>1</sup>, Caner Kara<sup>2</sup>

## ABSTRACT

**Purpose:** To evaluate refractive errors and ocular findings in cases with ocular coloboma with various involvement.

**Materials and Methods:** The ophthalmic examination findings of preterm and term infants, who were followed up with a diagnosis of ocular coloboma between December 2014 and June 2022, were retrospectively evaluated.

**Results:** The study included 22 eyes of 15 infants with a mean gestational age of  $37.00 \pm 3.00$  weeks and a mean birth weight of  $2752 \pm 896$  g. The examination was performed at a mean postmenstrual age (PMA) of  $36.8 \pm 2.7$  weeks. There were 5 (33.3%) male and 10 (66.7%) female patients. Of the 15 ocular coloboma infants included in the study, 7 had bilateral, and 8 had unilateral involvement. While isolated bilateral iris coloboma was present in only one case, chorioretinal involvement was present in 13 infants. In one of the cases with bilateral involvement, unilateral lens coloboma was present. Among the accompanying ocular findings, unilateral cataract was found in two cases and unilateral microphthalmia in one case. Strabismus and concomitant systemic diseases were not present in the cases. The spherical, cylindrical and spherical equivalent (SE) values in the coloboma infants were  $2.74 \pm 1.08$  D,  $-1.57 \pm 0.97$  D and  $1.95 \pm 1.04$  D, respectively.

**Conclusions:** In conclusion, this study supports that posterior segment involvement is more common than anterior segment involvement in patients with ocular coloboma. Although a wide range of refractive errors may be observed in these cases, hyperopic refractive error was more prominent in this study.

**Keywords:** Premature, Term, Ocular coloboma, Refractive outcome, Myopia.

## INTRODUCTION

Ocular coloboma is a rare malformation that occurs due to failure of the embryonic optic fissure to close between the 5<sup>th</sup> and 7<sup>th</sup> week of gestation, with an incidence of 0.7 per 10,000 newborns.<sup>1,2</sup> The iris, ciliary body, choroid, retina and optic disc (OD) may be involved. Typical colobomas are described as defects affecting the lower/inferonasal quadrant of the ocular part, usually along the fetal fissure. In contrast, atypical colobomas are described as similar defects seen elsewhere that may result from a defect in normal embryogenesis.<sup>3,4</sup> The size of the colobomatous defect is variable and may range from an asymptomatic small defect to a microphthalmic cystic eye causing vision loss.<sup>5,6</sup> The aetiology of coloboma is quite heterogeneous. Although it is usually inherited as an autosomal dominant

trait, autosomal recessive, X-linked and sporadic cases have also been reported.<sup>1,3,7</sup> Colobomas may be isolated or associated with systemic diseases accompanied by chromosomal abnormalities.<sup>8</sup> The incidence and severity of ocular complications may vary depending on the area affected by the coloboma and the size of the affected area. It has been reported that microphthalmia, microcornea may develop in coloboma patients. Foveal, optic nerve and maculopapular bundle involvement or retinal detachment, choroidal neovascular membrane, and cataract formation are correlated with poor vision in patients with coloboma. Refractive errors, especially in unilateral cases, have also been reported to accompany coloboma and cause anisometropic amblyopia.<sup>6,9-11</sup>

1- Assistant professor, University of Health Sciences, Etlik Zübeyde Hanım Maternity and Women's Health Teaching and Research Hospital, Ankara, Türkiye

2- Associate professor, Ministry of Health, Etlik City Hospital, Ankara, Türkiye

Received: 07.03.2023

Accepted: 22.11.2023

*J Ret-Vit* 2023; 32: 257-261

DOI: 10.37845/ret.vit.2023.32.43

**Correspondence Address:**

Esay Kiran Yenice  
University of Health Sciences, Etlik Zübeyde Hanım Maternity and Women's Health Teaching and Research Hospital, Ankara, Türkiye

**Phone:** +90 312 567 4000

**E-mail:** esay\_kiran@hotmail.com

The aim of this study was to evaluate refraction values and accompanying ocular findings in cases of coloboma with various ocular involvement.

## MATERIALS AND METHODS

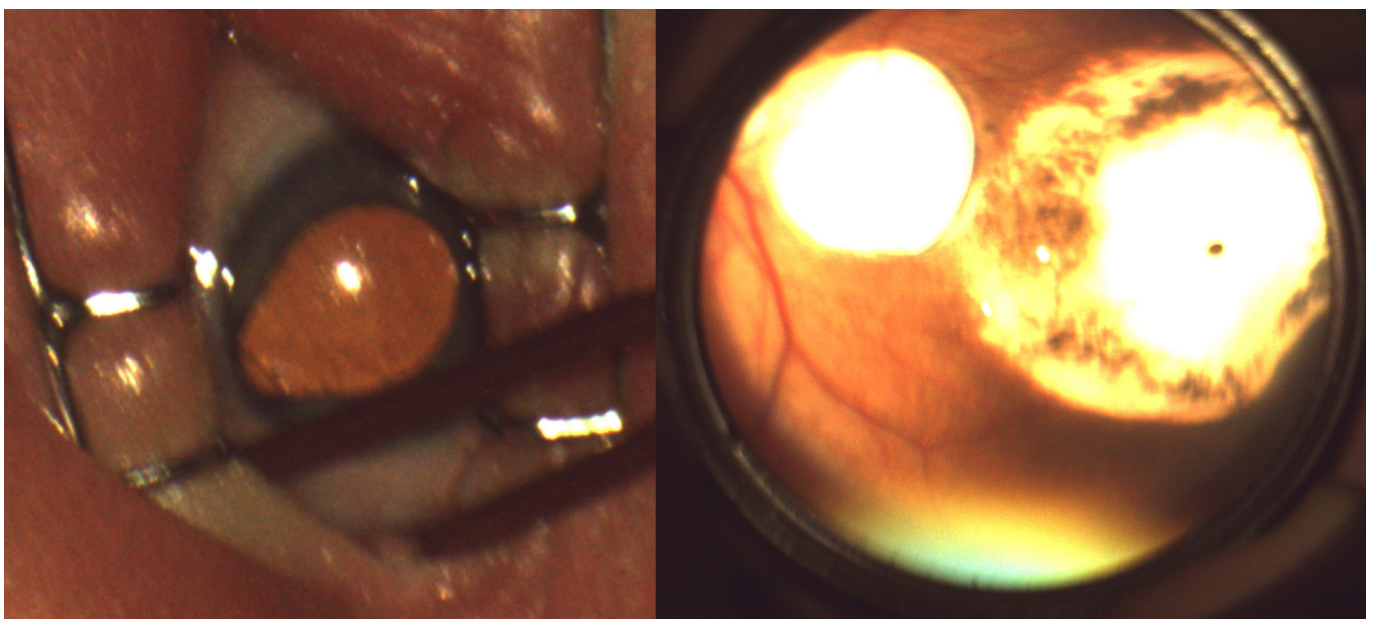
This retrospective study followed the standards of the Declaration of Helsinki and was approved by the Ethics Review Committee (2022/11). Informed consent was obtained from all parents. Eighteen neonates with a diagnosis of ocular coloboma who were followed up between December 2014 and June 2022 were included in the study. Three infants with ocular coloboma, who were later deceased, were excluded from the study. Neonates with incomplete examination findings were called and re-evaluated, and eye measurements were taken. Fifteen preterm and term infants with ocular coloboma were evaluated. The infants' gestational age (GA) at birth, birth weight (BW), family history, ophthalmic examination findings, the presence of coloboma, laterality, and dilated refraction measurements were recorded. As the disease may progress asymmetrically, evaluation was made on the number of eyes. Refractive errors were evaluated by cycloplegic retinoscopy and automated refractometry (Welch Allyn SureSight Autorefractor, USA) following dilatation with two drops of 1% cyclopentolate hydrochloride (Sikloplejin, Abdi İbrahim, Turkey). Spherical and cylindrical powers, as well as spherical equivalent (SE) values, were recorded in diopters (D) for all patients. According to the results, the myopia was recorded as  $-0.75$  D or less; the hyperopia  $+0.75$  D or more; marked astigmatism  $-1.50$  D or less; and the anisometropia as  $1.00$  D or more.

The SPSS 25.0 program package was used for statistical analysis. Categorical data were presented as frequencies and percentages, and descriptive data as mean  $\pm$  standard deviation (SD).

## RESULTS

The study included 22 eyes of 15 infants with a mean gestational age of  $37.00 \pm 3.00$  weeks (30-40 weeks) and a mean birth weight of  $2752 \pm 896$  g (1030-3800 g). The examinations were performed at an average of  $36.8 \pm 2.7$  (3-75 months) postmenstrual age. There were five (33.3%) male and 10 (66.7%) female patients. Of the 15 ocular coloboma infants included in the study, seven had bilateral, and eight had unilateral involvement. While isolated bilateral iris coloboma was present in only one case, chorioretinal involvement was present in 18 eyes of 13 infants. One case with bilateral involvement had unilateral lens coloboma, and another case had bilateral optic disc coloboma.

In addition, 13 eyes of 10 infants had coloboma involving the iris or lens or both in the anterior segment, and 20 eyes of 14 patients had coloboma involving choroid or OD or both in the posterior segment (Figure 1). Other ocular findings were unilateral cataracts in two cases and unilateral microphthalmia in one. In addition, two patients had a family history (13.3%), one with microphthalmia in the mother and another with coloboma in the father. Strabismus and posterior segment complications, such as retinal detachment, choroidal neovascularization, and vitreous hemorrhage, were not present in the cases. The systemic evaluation did not reveal any concomitant



**Figure 1:** Representative image of iris coloboma and chorioretinal coloboma

systemic disease. Demographic data and coloboma findings of infants are presented in Table 1.

The spherical, cylindrical and spherical equivalent (SE) values were  $2.74 \pm 1.08$  D;  $-1.57 \pm 0.97$  D and  $1.95 \pm 1.04$  D in infants with coloboma. Hyperopia was observed in 86.4% (n=19) of the patients, followed by astigmatism (n=8) in 36.4% and emmetropia (n=3) in 13.6%. Myopic refraction was not found. Anisometropia was found in one patient with unilateral involvement and three with bilateral involvement.

**DISCUSSION**

Ocular coloboma is a rare malformation that results in tissue defects in one or more of the iris, ciliary body,

lens, retina, choroid and optic nerve tissues as a result of abnormal closure of the embryonic optic fissure during the intrauterine period.<sup>6</sup> It can be seen in a wide spectrum, from isolated iris coloboma with no clinical signs to more severe involvement, leading to loss of vision.<sup>12</sup>

Long-term ocular problems associated with coloboma include refractive errors, strabismus and posterior segment complications, including retinal detachment, choroidal neovascular membrane and vitreous hemorrhage. Especially in patients with unilateral involvement, anisometropia and amblyopia accompanying refraction errors increase, while the visual loss may be more prominent in cases with posterior pole involvement.<sup>9,13</sup>

**Table 1:** Demographic data and coloboma findings of infants

Patient	Age (month)	Gender	Colobomatous involvement				Refraction	Family History	Eye Anomaly
			Iris	Lens	Chorioretinal	Optic Disc			
1	8	M	OD: Yes OS: No	No	OD: Yes OS: No	No	OD +4.25-1.25x10/ OS +4.50-1.50x180	-	-
2	8	F	OD: Yes OS: No	No	OD: Yes OS: No	No	OD +3.00-0.75x10/ OS +2.50-2.00x180	-	-
3	16	F	OD: Yes OS: Yes	No	OD: Yes OS: Yes	OD: Yes OS: Yes	OD +4.00-2.00x165/ OS +2.00-2.75x180	-	-
4	3	M	OD: Yes OS: Yes	No	No	No	OD +1.75-1.00x10/ OS +2.75-1.00x180	Microphthalmia (Mother)	OD Cataract
5	6	M	OD: Yes OS: No	No	OD: Yes OS: Yes	OD: Yes OS: Yes	OD +4.50-1.00x180/ OS +3.00-1.50x180	-	-
6	7	F	OD: Yes OS: No	No	OD: Yes OS: No	No	OD +1.50-0.75x170/ OS +0.75-1.50x20	-	-
7	48	M	No	No	No	OD: Yes OS: Yes	OD +2.50-1.00x10/ OS +3.50-1.00x180	-	-
8	3	F	No	No	OD: Yes OS: Yes	No	OD +1.50-0.50x180/ OS +2.00/-1.00x180	-	-
9	75	F	OD: Yes OS: No	No	OD: Yes OS: No	OD: Yes OS: No	OD +2.25-0.75x160/ OS +2.25-1.00x90	-	-
10	12	F	OD: No OS: Yes	OD: No OS: Yes	OD: Yes OS: Yes	No	OD +3.00-2.00x180/ OS +3.50-2.50x20	-	OS Cataract
11	41	F	OD: Yes OS: No	No	OD: Yes OS: No	No	OD +2.50-2.00x170/ OS +2.75-0.25x25	-	-
12	4	F	No	No	OD: Yes OS: No	No	OD +4.00-3.50x180/ OS +4.00-4.50x180	-	-
13	27	F	No	No	OD: Yes OS: No	No	OD +3.50-0.75x170/ OS +4.25-2.25x170	-	-
14	6	M	No	No	OD: Yes OS: No	OD: Yes OS: No	OD +1.50-3.00x180/ OS +4.25-3.00x180	-	-
15	7	F	OD: Yes OS: Yes	No	OD: Yes OS: Yes	OD: Yes OS: No	OD +0.50-1.00x180/ OS +2.50-1.00x180	Unilateral Coloboma (Father)	-

Varela et al.<sup>9</sup> evaluated 62 isolated coloboma cases in the adult age group without accompanying systemic anomalies and found myopia in 55%, hyperopia in 11% and cataract in 50%. It was thought that the cornea and lens might be affected by abnormal eye development in the high rate of cataract detection and myopia development. On the other hand, choroidal neovascularization, vitreous hemorrhage and microphthalmia were detected less frequently in 8% of the patients.

In a 44-year-old case in which Baker<sup>10</sup> evaluated the effect of a large chorioretinal coloboma on refraction, a regular refractive cylinder value was detected in the left eye. It was stated that the lesion margins in the left eye caused a sudden cupping-like appearance where the lesion crossed with the healthy retina in the macular region. There was also a hypoplastic appearance in the optic disc. As a result, it has been stated that this change and damage to the retina may play a role in the formation of astigmatism.

In the study of Ertekin et al.<sup>13</sup>, 16 eyes of 10 patients with iris coloboma aged between 2 months to 17 years were evaluated. There was a family history in 3 of the cases, and the mean SE value was  $0.39 \pm 3.27$ . Microphthalmia in 3 eyes, anophthalmia in 1 eye, microcornea in 1 eye, and accompanying systemic findings in 3 familial cases and strabismus in 1 case were also found. In addition, retinal detachment was not detected in the cases.

In a 20-year-old patient evaluated by Assayag et al.<sup>14</sup> for anisometric amblyopia in the right eye, peripheral lens coloboma accompanied by decreased visual acuity in the right eye. They stated that peripheral and isolated lens colobomas that do not include the visual axis, where the lens can be selected well, may cause changes in each of the ocular components and may contribute to refractive errors, and may have a role in the formation of refractive error and amblyopia in this case.

Olsen et al.<sup>15</sup> showed that cycloplegic refraction and anisometropia values varied between -12.00 D and +11.00 D and 0.50 D and 11.00 D, respectively, in 23 eyes with optic nerve coloboma. It was stated that amblyopia and suitable refraction therapy should be applied in these children because refractive errors and anisometropia are common.

To our knowledge, there are few refraction studies in coloboma cases in the literature. In the present study, SE values were  $1.95 \pm 1.04$  D in patients with coloboma. Hyperopia was found in 86.4%, astigmatism in 36.4% and emmetropia in 13.6% of the patients. In addition, when

we evaluated the frequency of anisometropia, we found that anisometropia was less common in unilateral cases and more prevalent in bilateral cases. We may have seen the reflection of the optic disc involvement in bilateral cases, which is more prominent in the refraction values and anisometropia. In addition, the cataract rate was not as high as in the study of Varela et al.<sup>9</sup>, and only two patients had cataracts.

On the other hand, similar to the study by Ertekin et al.<sup>13</sup>, two patients had a family history, and one patient had microphthalmia in our study. However, no accompanying strabismus, ocular complications or systemic finding were detected in these patients. Unlike the literature, the small age range of the children included in the study (3-75 months)<sup>9-10, 13-14</sup> may have caused fewer ocular findings.

The small number of patients, the duration of follow-up and the lack of visual acuity are among the limitations of the present study. However, coloboma is already a rare condition. In addition, longer follow-up times and evaluation of visual acuity may guide the assessment of unpredictable refractive states and accompanying ocular findings in colobomatous eyes.

## CONCLUSION

This study supports that the posterior segment involvement is more common than the anterior segment in cases with ocular coloboma, and hyperopia refraction is more prominent in the present study. Therefore, detailed ophthalmic examination, questioning for accompanying systemic diseases, correction of refractive errors, and regular follow-up of infants diagnosed with ocular coloboma in terms of possible complications may improve long-term visual prognosis.

## REFERENCES

1. Stoll C, Alembik Y, Dott B, et al. Epidemiology of congenital eye malformations in 131,760 consecutive births. *Ophthalmic Paediatr Genet* 1992;13:179-86.
2. Wilson SW, Houart C. Early steps in the development of the forebrain. *Dev Cell*. 2004;6:167-81.
3. Wang P, Liang X, Yi J, et al. Novel SOX2 mutation associated with ocular coloboma in a Chinese family. *Arch Ophthalmol*. 2008 May;126:709-13.
4. Chang L, Blain D, Bertuzzi S, et al. Uveal coloboma: clinical and basic science update. *Curr Opin Ophthalmol*. 2006 Oct;17:447-70.
5. Olsen TW. Visual acuity in children with colobomatous defects. *Curr Opin Ophthalmol*. 1997;8:63-7.

6. Onwochei BC, Simon JW, Bateman JB, et al. Ocular colobomata. *Surv Ophthalmol* 2000;45:175-94.
7. Pagon RA. Ocular coloboma. *Surv Ophthalmol*. 1981;25:223-36.
8. Lingam G, Sen AC, Lingam V, et al. Ocular coloboma-a comprehensive review for the clinician. *Eye*. 2021;35:2086-109.
9. Daich Varela M, Huryn LA, Hufnagel RB, et al. Ocular and Systemic Findings in Adults with Uveal Coloboma. *Ophthalmology*. 2020;127:1772-4.
10. Baker DR. Retinal astigmatism induced by a chorioretinal coloboma? *Clin Exp Optom*. 2021;104:240-2.
11. Gradstein L, Belfair N, Ronen E, et al. Functional visual loss in patients with bilateral ocular coloboma. *J AAPOS*. 2002;6:195-7.
12. Vogt G, Puhó E, Czeizel AE. A population-based case-control study of isolated ocular coloboma. *Ophthalmic Epidemiol* 2005;12:191-7.
13. Ertekin S, Göksel I, Kuş N, et al. Systemic and ophthalmologic findings in patients with iris coloboma. *Turk J Ophthalmol*. 2013; 43: 19-22.
14. Assayag E, Zadok D, Smadja D, et al. Optical changes and apparent emmetropization in a patient with a peripheral unilateral lens coloboma. *J AAPOS*. 2021;25:195-8.
15. Olsen TW, Summers CG, Knobloch WH. Predicting visual acuity In children with colobomas Involving the optic nerve. *J Pediatr Ophthalmol Strabismus*. 1996;33:47-51.